

Study the Impact of the Concentration of Mercury Chloride on Micronuclei Formation and Some Organs of Juveniles of *Ctenopharyngodonidella*

Afrah Abed Maktoof¹, Rasha Salih Nuhair², Awatif Mokar Al-Saaedi³, Zahraa Z. Aljanabi⁴

¹Assistant Prof., Department of Biology, College of Science, University of Thi-Qar, Iraq, ²Lecturer, Department of Biology, College of Science, University of Thi-Qar, Iraq, ³Assistant Lecturer, Department of Biology, College of Science, University of Thi-Qar, Iraq, ⁴Assistant Lecturer, Environmental Research Center/University of Technology, Iraq

Abstract

There is no doubt that Mercury is considered one of the significant pollutants to the environment. It has been noticed that exists in three forms. The previously mentioned forms are elemental or metallic (mercury), organic and inorganic mercury. Inorganic mercury can be converted microbiologically into organic form. The present paper has been focused on the genotoxicity and histopathological effect of mercuric chloride on *Ctenopharyngodonidella* (Grass carp). Basically, *Ctenopharyngodonidella* is one of the most important fish species according to FAO reports. Moreover, *C. idella* fry have been divided into four groups. The first Group was exposed to sublethal concentrations of 5 ppb, Second Group was exposed to 10 ppb of mercuric chloride and the third one was exposed to 15 ppb, on the other hand, the fourth Group was kept as unexposed control. Furthermore, a blood smear was done for micronuclei examination and gills and liver of the tested fish were obtained for histopathological study. A significant increase of micronucleus notched erythrocytes in fish exposure with HgCl₂ than in the controls). The microscopic examination has shown different histological changes in the organs of the examined fish which has been exposed to mercuric chloride in comparison with control organs.

Keywords: Mercuric chloride, *Ctenopharyngodonidella*, Micronucleus, Histopathological changes.

Introduction

Generally speaking, Mercury is classified as one of the most harmful pollutants because of its high toxicity and persistence in the environment. To put it in other way, it exists in three forms: elemental (metallic) mercury, organic mercury (methylmercury) and inorganic mercury (Mercuric Chloride).^(1,2) No one can deny that the fact that it is a naturally occurring element, but it has been directly mobilized into ecosystems through mining. Moreover, it has been used in products on (paint, electronic devices) and industry.^(3,4)

To that end, Mercury pollution in aquatic ecosystems has received a great deal of attention since the discovery of mercury as the cause of Minamata disease in Japan in the 1950s⁵. Having said that most mercury is released into the environment as an inorganic form, which is

primarily bound to particulates and organic substances and might not be available for direct uptake by aquatic organisms. Then, part of the inorganic mercury can be microbiologically converted into methyl-mercury and taken up by the aquatic organisms^(6,7).

However, once Hg exists in aquatic systems, it can be accumulated in different organisms, leading to its biomagnification through the food chain. Studies examining Mercury accumulation in fish tissues are significant because these organisms represent the main human contamination pathway^(8,9,10).

Furthermore, *Ctenopharyngodonidella* (Grass carp), species of the family Cyprinidae, is a subtropical to temperate fish species, native in eastern Asia with a native range from northern Vietnam to the Amur River on the Siberia-China border. It is considered one

of the most important species, according to FAO, the value of farmed *C. idella* is about 6.46 billion USD for a production of 5.03 billion tons in 2012^(11,12,13).

Additionally, this species is characterized by a wide, sacaleless head, terminal or subterminal mouth with simple lips and very short snout¹³. That is to say, the body is slender and fairly compressed with a rounded belly and the lateral line is complete, slightly decurved and extending along the middle of the depth of the tail^(14,15). As well as, adult *C. Idella* has a dark gray colour while the dorsal surface sides have a slightly golden shine. Colour fins are clear to gray-brown¹⁶.

C. idellais consumed as food in Iraq and many other countries in the world. It is also being widely introduced to control of submersed aquatic weed because of their strong preference for aquatic vegetation^(17,18)

Although many studies had been estimate the pollution of aquatic environments in Iraq, There is a need to investigate the effect of this pollution on aquatic biomass. So this study was performed to examine the effect of mercuric chloride on the histology of some organs of *C.idella* fish.

Materials and Method

Fish and experiments: *C.idella* fry with an average length of 15 -20 cm and weight of 100g were purchased from a commercial aquaculture facility in Al Rifaicity (Thi-Qar, Iraq) and adapted to experimental conditions (running dechlorinated tap water at 25°C (with a 12 h-D,12 h-L photoperiod)for a minimum period of 15 days. During the adaptation period, fish were fed dry commercial pellets, and water was renewed daily. Later 15 fish were transferred to each one of four aquaria; of 200 L capacity. Different test doses were prepared making dilution of the stock concentration. Three of aquaria containing 5,10 and 15 ppb HgCl₂, respectively. Control fish were added to the fourth aquarium which containing uncontaminated water. The fish were sacrificed after 14 days. Micronuclei Examination, Gills and liver was pulled out for histopathological study.

Cytogenetic Examinations:

Micronuclei: Determine the number of Micronuclei by¹⁹. A blood smear was made on a glass slide to dry, then fixed for 10 minutes with methanol and dye with gmsa stain for 30 minutes. The prepared slides were examined under the (40X). the number of Micronuclei

was calculated in 1000 cells.²⁰

Histopathological study: Tissue specimens from used fish (Gills, liver and muscles) were taken and fixed in 10 % formalin. They were processed into the routine histological procedure to obtain five micron thick paraffin sections then they were stained with hematoxylin and eosin and were examined under light microscope²¹.

Results and Discussion

Cytogenetic study: It is noticed from Table (1) the rates of the number of micronuclei in (1000) red blood cell of the three groups and the control group fish, in the third HgCl₂ groups a significant increase (P≤0.05) in micronuclei rates during the time of the experiment was (3.400 ± 0.910), (7.133 ± 1.355) And (10.333 ± 3.145), respectively, compared to the control group (0.666 ± 0.487), (Fig. Micronuclei).

Table (1): Rates of micronuclei (1000/cell) in the blood of *Ctenopharyngodonidella* during the time of the experiment

Group	Micronuclei		
	Mean	Std. Deviation	Std. Error
Control group	0.666 d	0.487	0.125
5 ppb HgCl ₂ group	3.400 c	0.910	0.235
10 ppb HgCl ₂ group	7.133 b	1.355	0.350
15 ppb HgCl ₂ group	10.333 a	3.145	0.814
LSD	2.73	-----	

- N=15
- Different small letters indicate a significant difference below the probability level (p <0.05) when compared vertically.

The results indicated a significant increase in micronuclei of mercury chloride exposure group compared with control groups. These results agreed with the previous.⁽²²⁻²⁴⁾

The micronucleus test, one of the most popular and promising tests of environmental genotoxicity, has served as an index of cytogenetic damage for over 30 years.²⁵ The increase in micronuclei of red blood cells in the present study of (*ctenopharyngodonidella*) due to mercury chloride toxicity was identified as a good biological indicator of genetic toxins to monitor the influence of such elements. Mechanisms of erythrocyte nuclei deformity have not yet been explained and there is no consensus about the causes of these changes²⁶.

Recently, it has been proposed that severe nuclear deformations can also originate from physical forces, such as the compression of the nucleus during migration through confined spaces that can lead to nuclear envelope rupture.²⁷

Histopathological study: There is no sign of mortality was noticed at the study period in all fish groups. However different histopathological changes were noticed through microscopic examination the studied organs. Moreover, the gill sections of *C.idella* have shown that the all fish groups which have

been treated with the three concentration of mercuric chloride (5, 10 and 15 ppb) have a loss of epithelial tissue (Fig. 1,2). Additionally, the other microscopic histopathological changes in fish group which have been treated with 10 ppb mercuric chloride are the congestion of small blood vessels (Fig. 2), what's more, it has been noticed that there is presence of inflammatory cells in the secondary lamina in the gills of *C.idella* treated with 15ppb of experimental toxic element that has been used in this investigation (Fig. 3). The normal histology of gills is presented in (Fig. 4).

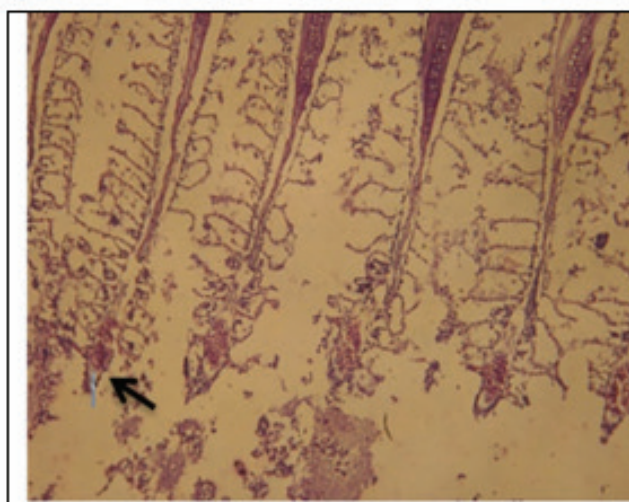


Fig 1.Gills section of *C. idella* treated with 5 ppb mercury chloride 10X

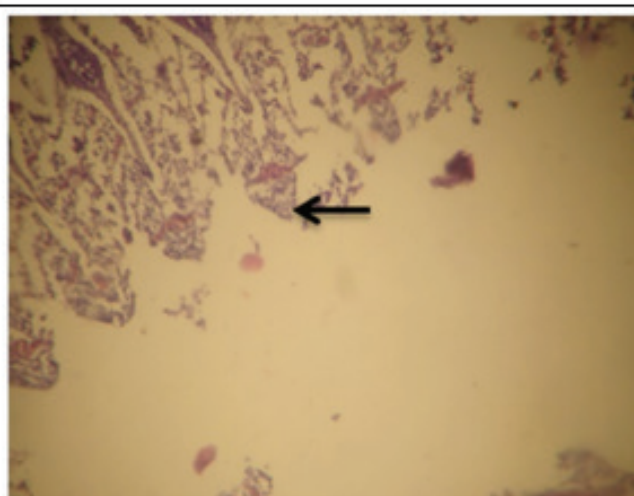


Fig 2. Sever loss of epithelial lining, Gill sections, Fish treated with 10 ppb mercuric chloride 10X

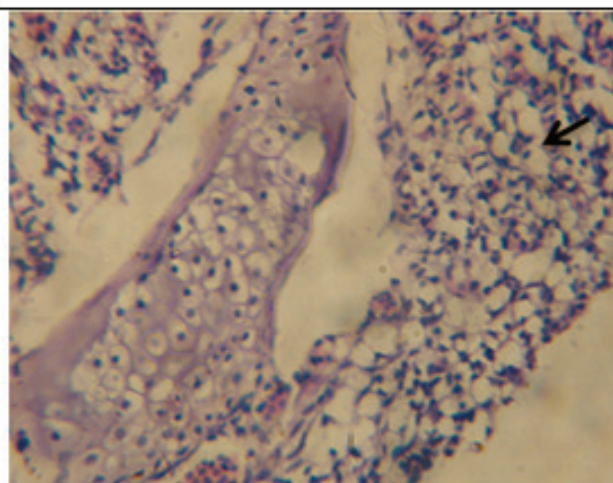


Fig 4. Presence of inflammatory cells in the secondary lamina in the gills of *C. idella* treated with 15ppb mercuric chloride 40X

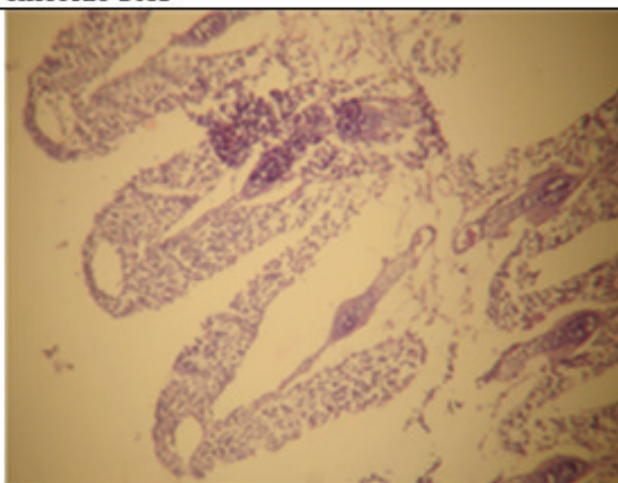


Fig 5. Normal set of gills 40X

Furthermore, figures (5) pointed to the Presence of inflammatory cells in the liver section of the fish treated with 5 ppb mercuric chloride.

Fish gills are particularly sensitive to the chemical and physical modifications of surrounding water. Not only but also, morph functional alterations of the gills have been widely documented after exposure to water pollutants. However, many authors suggest that gill damages are largely non-specific and can be induced by a wide range of toxicants^(28,29).

Several studies have been focused on the effects of mercury on gill tissues. Most of the available data have been focused on methyl mercury, while the effects of inorganic mercury are less investigated. However, gill damages and structural changes caused by water-borne inorganic mercury have been reported for relatively few species, from both marine and freshwater ecosystems⁽³⁰⁻³⁴⁾. Mercury caused a wide variety of morphological changes in *Danio rerio* gills and modifications of both Na⁺/K⁺-ATPase and metallothioneins expression³⁵.

It has been noticed that the appearances of lysed areas were found in zebra fish liver after exposure to copper sulphate. As well as, considering the copper's ability to induce membrane disruption, the authors suggested that the lysed distribution may reflect a heterogeneous distribution of Copper in the parenchyma. Interestingly, Observation of lysed area after exposure to inorganic mercury; whereas similar adverse effects have not been reported in liver after exposure to methyl mercury; These results further support the hypothesis that inorganic mercury, affect membrane whereas methyl mercury does not appear to act directly at plasma membrane³⁶.

Wu et al³⁷ provided strong evidence for liver toxicity following exposure of adult guppies (*Poecilia reticulata*) to methylmercury (1–10 µg/L for 1 and 3 months). Additionally, alterations have involved hepatocytes (cell swelling and nuclear pyknosis) and hyperplastic biliary epithelium of the intrahepatic bile duct.

It have been concluded that fish exposure to inorganic mercury causes different histopathological changes. However, further study is warranted to study the molecular effect of mercuric chloride of *C. idella*, or to know the toxic effect of mercury on the other important types of fish ⁽³⁸⁻⁴⁰⁾.

Disclosure statement: No potential conflict of

interest was reported by the authors.

Conflict of Interest: The author has no disclosures to report.

Source of Funding: Self.

Ethical Clearance: Not required.

References

1. Jung-Duck P, ZWei. Human exposure and health effects of inorganic and elemental mercury. J. Prev. Med. Public Health, 2012; 45:(6); 344-352.
2. Clarkson TW, L.Magos, GJMyers. The toxicology of mercury-current exposures and clinical manifestations. New Engl. J. Med, 2003; 349: 1731-1737.
3. Pirrone N, GJKeeler, JONriagu. Regional differences in worldwide emissions of mercury to the atmosphere. Atmos. Environ, 1996; 30(17): 2981-2987.
4. Streets DG, QZhang, YWu. Projections of global mercury emissions in 2050. Environ. Sci. Technol, 2009; 43(8): 2983-2988.
5. Philippe G, SHiroshi, MKatsuyuki, EKomyo. Adverse effects of Methylmercury: environmental health research implications. Environ Health Perspect, 2010; 118(8): 1137-1145.
6. Zahra K, KSaber, SMMohsen, MKSaeedeh. Histopathological and pathomorphological effects of Mercuric chloride on the gills of Persian Sturgeon, *Acipenser persicus*, Fry. IJNRMS, 2011; 1(1): 23-32.
7. Richard P, GHKlaus. Production of methylated mercury, lead, and cadmium by marine bacteria as a significant natural source for atmospheric heavy metals in polar regions. Chemosphere, 1991; 39(1): 89-102.
8. Clayden MG, KAKidd, BWyn, JLKirk, DCMuir, NJO'Driscoll. Mercury biomagnification through food webs is affected by physical and chemical characteristics of lakes. Environ Sci Technol, 2013; 47(21): 12047-1253.
9. Mehdi H M, Seyedand PYaghob. Bioaccumulation of trace Mercury in trophic levels of benthic, benthopelagic, Pelagic fish species, and sea birds from Arvandriver, Iran. Biol Trace Elem Res, 2013; 56(13): 175-180.
10. Balshaw S, JEdwards, BDaughtry, KRoss. Mercury

- in seafood: mechanisms of accumulation and consequences for consumer health. *Rev Environ Health*,2007;22(2):91-113.
11. Mehrzad M, RAnnahita, TDZahra. Case report of chondromainagrass carp(*Ctenopharyngodonidella*). *Vet Res Forum*,2016;7(2):173-176.
 12. Xiaoyan X, SYubang, FJianjun, LLiqun, LJiale. De novo assembly of the grass carp *Ctenopharyngodonidella* transcriptome to identify miRNA targets associated with motile aeromonad septicemia. *PLoS One*,2014; 9(11):e112722.
 13. Cudmore B, NMandrak. Biological Synopsis of Grass Carp (*Ctenopharyngodonidella*). Canadian manuscript report of fisheries and aquatic sciences,2004;1488-5387:2705, Publishing Burlington, Ontario : Fisheries and Oceans Canada, 52 p.
 14. Eccles DH. FAO species identification sheets for fishery purposes. Field guide to the freshwater fishes of Tanzania. FAO, Rome,1992;145.
 15. Cassani JR, WE Caton, BClark. Morphological comparisons of diploid and triploid hybrid grass carp, *Ctenopharyngodonidella* X *Hypophthalmichthys nobilis*. *J. Fish. Biol*,1984; 25:269-278.
 16. Opuszynski K, JVShireman. Herbivorous fishes: culture and use for weed management. In cooperation with James E. Weaver, Director of the United States Fish and Wildlife Service's National Fisheries Research Center. CRC Press, Boca Raton, Florida,1995.
 17. Shireman JV, CR Smith. Synopsis of biological data on the grass carp, *Ctenopharyngodonidella* (Cuvier and Valenciennes, 1844). Food and Aquaculture Organization Synopsis,1983;135:86.
 18. Abdul-Razak M, SSajed, AFRafea. The status of artisanal fisheries in the lower reaches of Mesopotamian rivers, north Basrah, Iraq. *Proc. 5th Int. Con. Biol. Sci. (Zool.)*,2008; 5:128 - 132.
 19. Al-Sabti, K. Comparative micronucleated erythrocyte cell induction in three cyprinids by five carcinogenic-mutagenic chemicals. *Cytobios*,1986; 47:47-54.
 20. Fenech M, Morley A. Measurement of micronuclei in lymphocytes, *mut Res*,1985;147:29-36.
 21. Luna LC. Manual of histologic staining method of Armed forces. Institute of pathology., 3rd ed., McGraw-Hill Book. Newyork, London,1968;9:1-74.
 22. Nepomuceno JC, Ferrari, I, Spanó MA, Centeno AJ. Detection of micronuclei in peripheral erythrocytes of *Cyprinus carpio* exposed to metallic mercury,1997;30(3):293-7.
 23. Da Rocha CAM, da Cunha LA, da Silva Pinheiro RH, et al. Studies of micronuclei and other nuclear abnormalities in red blood cells of *Colossoma macropomum* exposed to methylmercury. *Genetics and Molecular Biology*,2011; 34(4): 694-697.
 24. Nirchio M, Choco-Veintimilla O, Quizhpe-Cordero PF, José Gregorio Hernández JG., Oliveirac. Genotoxic effects of mercury chloride on the Neotropical fish *Andinoacara rivulatus* (Cichlidae: Cichlasomatini). *Rev. Biol. Trop. (Int. J. Trop. Biol. ISSN-0034-7744)*,2017;67(4): 745-754.
 25. Fenech M, Chang WP, Kirsch-Volders M, Holland N, Bonassi S, Zeiger E. HUMN project: Detailed description of the scoring criteria for the cytokinesis-block micronucleus assay using isolated human lymphocyte cultures. *Mutat Res*,2003; 534:65-75.
 26. Strunjak-Perovic I, Coz-Rakovac R, Topic Popovic N, Jadan M. Seasonality of nuclear abnormalities in gilthead sea bream *Sparus aurata* (L.) erythrocytes. *Fish Physiology and Biochemistry*,2009;35(2): 287-291.
 27. Shah P, Wolf K, Lammerding J. Bursting the Bubble-Nuclear Envelope Rupture as a Path to Genomic Instability? *Trends in Cell Biology*,2017;27(8): 546-555.
 28. Mallatt J. Fish gill structural changes induced by toxicants and other irritants: A statistical review. *Can. J. Fish Aquat. Sci.*,1985; 42:630-648.
 29. Martinez CB, MYNagae, CTZaia, DAZaia. Acute morphological and physiological effects of lead in the neotropical fish *Prochilodus lineatus*. *Braz. J. Biol.*,2004; 64:797-807.
 30. Jagoe CH, PLShaw-Allen, SBrundage. Gill Na⁺, K⁺-ATPase activity in largemouth bass (*Micropterus salmoides*) from three reservoirs with different levels of mercury contamination. *Aquat. Toxicol.*, B,1996;36:161-176.
 31. Jagoe CH, AFaivre, MCNewman. Morphological and morphometric changes in the gills of mosquitofish (*Gambusia holbrooki*) after exposure to mercury (II). *Aquat. Toxicol.*,1996; 34:163-183.
 32. Canli M, RMStagg. The effects of in vivo

- exposure to cadmium, copper and zinc on the activities of gill ATPases in the Norway lobster, *Nephrops norvegicus*. *Arch. Environ. Contam. Toxicol. A*, 1996; 31:494-501.
33. de Oliveira Ribeiro CA, L. Belger, E. Pelletier, C. Rouleau. Histopathological evidence of inorganic mercury and methyl mercury toxicity in the arctic charr (*Salvelinus alpinus*) *Environ. Res.*, 2002; 90: 217-225.
 34. De Oliveira Ribeiro CO, E. Pelletier, W. C. Pfeiffer, C. Rouleau. Comparative uptake, bioaccumulation, and gill damages of inorganic mercury in tropical and nordic freshwater fish. *Environ. Res.*, 2000; 83: 286-292.
 35. Rachele M, B. Elvira. Morphofunctional alterations in zebrafish (*Danio rerio*) gills after exposure to Mercury chloride. *Int J Mol Sci.*, 2017; 18(4): 824.
 36. Rachele M, G. Antonello, P. Daniela, B. Laria, T. Valentina, O. E. Lars, S. Settimio, T. Sandro, B. Elvira. Effects of two sublethal concentrations of Mercury chloride on the morphology and metallothionein activity in the liver of Zebrafish (*Danio rerio*). *Int J Mol Sci.*, 2016; 17(3): 361.
 37. Wu D, L. Jie, W. Lixin, J. Yang, C. Melissa, E. H. David. Developmental toxicity from exposure to various forms of mercury compounds in medaka fish (*Oryzias latipes*) embryos. *Peer J.*, 2016; 4: e2282.
 38. Uluturhan E, F. Kucuksezgin. Heavy metal contaminations in Red Pandora (*Pagellus erythrinus*) tissues from the Eastern Aegean Sea, Turkey. *Water Res.*, 2007; 41: 1185-1192.
 39. Wael AO, H. Z. Khalid, A. A. Amr, S. Abo-Hegab. Risk assessment and toxic effects of metal pollution in two cultured and wild fish species from highly degraded aquatic habitats. *Arch Environ Contam Toxicol.*, 2013; 65(4): 753-764.
 40. Rejomon G, M. Nair, T. Josep. Trace metal dynamics in fishes from the southwest coast of India. *Environ Monit Assess.*, 2000; 167: 201, 243-25.