

Histological Changes in Mice (Balb/c) Induced by Newcastle Virus in Digestive System

Abbas Abed Sharhan¹, Ahmed Obaid Hussain², Ameer Jawad Hadi³, Ruqya jaafer baqer³

¹College of biotechnology, Al-Qasim Green University, Iraq, ²College of biotechnology, Al-Qasim Green University, Iraq, ³Babylon Dental Specialize Center, Iraq

Abstract

Many domestic and Newcastle disease is a contagious bird disease affecting wild avian species, it may be transmissible to humans. Detection of Newcastle virus confirmed by rapid test technique (Immunochromatography). ten sample (10%) out of 100 faeces sample collected from chickens were positive. Twelve mice used in this study divided into two groups, first group consist of six mice induced with 0.2 ml from one positive sample of Newcastle virus suspension to evaluate some histopathological changes caused by Newcastle virus in small intestine and stomach of mice, second group induced with 0.2 ml from phosphate buffer saline only. The results revealed that histopathological changes in small intestine (duodenum) induced by using 0.2 ml from the positive Newcastle virus suspension to complete necrosis and fragmentation in the villi. Jejunum of mice treated with this concentration of Newcastle virus has partial necrosis for villi with filtration of villus core while ileum of mice treated with same concentration has wide spread of villus necrosis. Stomach of treated mice has oedema in submucosa layer and partial necrosis in gastric glands.

Key words: Histological changes, Newcastle virus, digestive system

Introduction

Newcastle disease is caused by avian paramyxovirus serotype-1 (APMV-1), which is also disease virus (NDV). It is a highly contagious viral disease that affects domesticated and wild bird species throughout the world as well as NDV is a human pathogen and the most common sign of infection in humans is conjunctivitis that develops within hours of NDV exposure to the eye (1,2). However, disease host species and in different geographical locations. NDV is classified in the genus Avulavirus within subfamily Paramyxovirinae, family Paramyxoviridae and order Mononegavirales³. This enveloped virus has a negative sense non-segmented, single stranded RNA genome has 15198 nucleotides in length⁴. The genome encodes six structural and two non-structural proteins. Based on the fusion (F) gene strains are classified into lineages or genotypes; however the discrepancies between the two classification systems are nominal (5,6,7). NDV is spread primarily through direct contact between healthy birds and the bodily discharges of infected birds. The disease is transmitted through infected birds' droppings and secretions from

the nose, mouth, and eyes.. Clinical manifestation or severity of the ND depends largely upon the isolates involved in disease outbreak⁸. Based upon pathogenicity, these strains are commonly categorized into velogenic (mesogenic and lentogenic types)⁹. The varying level of pathogenicity is attributed to amino acid sequence motif present in protease cleavage site of the precursor F protein^(10,11).

Materials and Method

Samples collection:

A total of 100 faeces samples were collected from chicken suffering from clinical signs and symptoms of severe greenish watery diarrhea. Detection of Newcastle virus performed by rapid test (Immunochromatography) supplied from Biochek company –USA. The positive samples for Newcastle by rapid test were diluted with phosphate buffer saline or normal saline and stored at -20 °C in freeze. One positive samples of Newcastle was further used for the experimental study on laboratory animals (mice) for evaluation the effects of Newcastle disease on histological sections of these

mice **Experimental study** :. A total of 12 males mice species Balb/c have aged two month and weight 100-120 g divided into two groups , the first group consist of six mice injected orally with 0.2ml of Newcastle virus suspension for one positive sample.. The other as control group was received 0.2 ml of sterile phosphate buffer saline (PBS) according to methods of ^(12,13). after 4-6 days clinical signs were recorded in infected animals . were observed Experimental mice were sacrificed after anesthetization by chloroform and open abdomen cavity by medical scissors, tissue from small intestine , stomach ,liver were collected from the experimentally infected mice and placed in formalin 10% for histopathological examination in later. Histological sections and staining were prepared according to methods described by ¹⁴ . The histopathological changes were observed by Dr. Nemah . H. AL-jabori /college of medicine / Babylon university under the magnification power 10X and 40 X of light microscope.

Results

Histological changes observed in stomach and small intestine which infected with 0.2ml from newcasstle virus suspension , these changes shown in figure 1,3,5,7 . Figure (1) Stomach of mice treated with 0.2ml from Newcastle virus suspension shows edema in submucosa layer and partial necrosis in gastric gland. The results in figure (3) small intestine of mice (duodenum) treated with 0.2ml concentration from virus Newcastle suspension revealed to complete necrosis and fragmentation of the villi. figure (5) small intestine of mice(jejunum) treated with 0.2ml concentration from newcasstle virus suspension revealed to partial necrosis of villi with filtration of villi core of lymphocytes. ilium of mice treated with 0.2ml concentration of virus suspension indicated to wide spread of villus necrosis

While the figures 2,4,6,8 revealed to stomach, small intestine(duodenum) , small intestine (jejunum) and small intestine (illum) respectively for control mice treated with

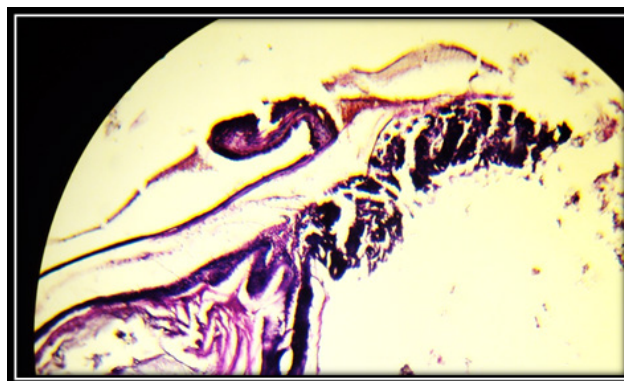


Figure (1) : Stomach of mice treated with 0.2ml from Newcastle virus suspension. The slide shows edema in submucosa layer and partial necrosis in gastric gland . H&E. 20X .

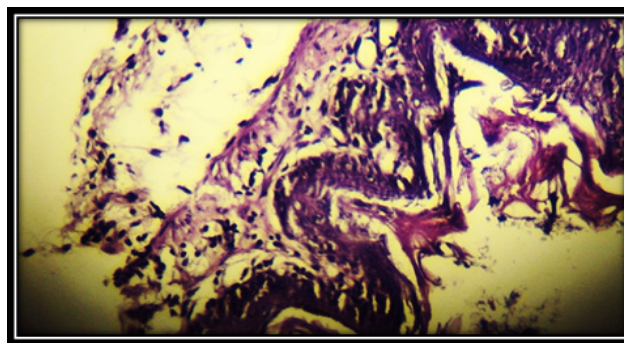


Figure (2): Stomach of control mice. The slide shows the normal histology of the stomach with the following layers: Serosa. Mu, muscularis properia. and submucosa layers .. H&E. 20X



Figure (3): Small intestine of mice (doudenum) treated with 0.2ml from Newcastle virus suspension. The slide shows complete necrosis and fragmentation of villi . H&E. 20X

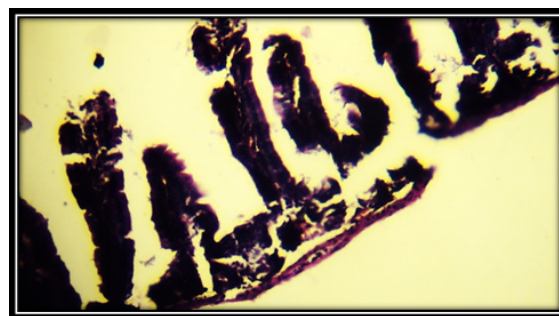


Figure (4) : duodenum of control mice. The slide shows the normal histology of the duodenum with normal villi . H&E 20X .

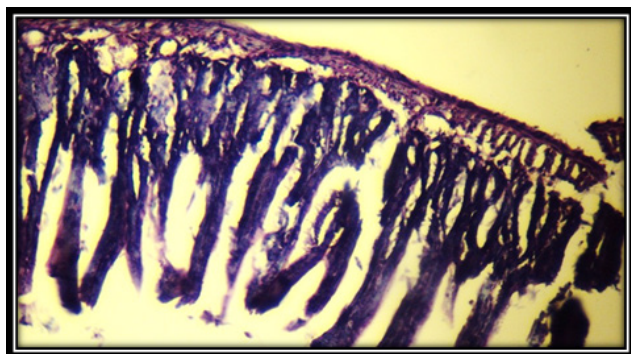


Figure (5) : jejunum of control mice. The slide shows the normal histology of the duodenum with normal villi core . H&E 20X .

Discussion

The authors consider lesions of Newcastle virus most prominent duodenum jejunum and ileum. Even in birds showing neurological signs prior to death, little evidence is found nervous system. Lesions are usually present in the respiratory tract when clinical signs indicate involve men ¹⁵ . The results of present study about effects of Newcastle virus on stomach and small intestine of mice which experimentally infected with this virus revealed to histopathological changes within stomach and small intestine including duodenum , jejunum and ileum in the mice infected with 0.2ml from Newcastle virus suspension .These histopathological changes were observed in figure 3,5 were indicated histopathological changes in small intestine including duodenum, jejunum and ileum of mice treated 0.2 ml viral suspension ,histological changes showed complete necrosis of the villi in duodenum, partial necrosis of villi with filtration of villi core of lymphocytes in jejunum. and wide spread of necrosis of villi for Ileum. This results similar to recent studies for other enteroviruses such as rotavirus ,these studies recorded a severe hemorrhagic lesions in the lab animals groups (pigs) infected with rotavirus ¹³ . Other reports mentioned the occurrence of villi atrophy and atrophy with blunting of the villus tips in the ileum and jejunum of pigs infected with rotavirus ¹² . Similar findings were reported by ¹⁶ which mentioned the severe necrotic and degenerative lesions of the villous enterocytes in piglets. Stomach of mice treated with 0.2ml from Newcastle virus suspension had macroscopic changes in the stomach , as well as microscopic changes (figure 1) in tissues .Stomach of mice treated with this concentration has oedema in submucosa layer and partial necrosis in gastric gland, this result also reported by (17, 18,19,20) which mentioned that piglets infected with rotavirus showed

macroscopic and microscopic changes in the stomach , histopathological changes in stomach and small intestine of mice which treated with Newcastle virus suspension due to most replication for newcasstle virus in small intestine. Causes of histopathological changes in small intestine of mice due to enterovirus replicates predominantly in the cytoplasm of differentiated small intestinal villous epithelial cells and thus the virus induces changes that are restricted to the small intestine and these viruses induced epithelium cells destruction and inflammatory response to these parts of intestine (21, 22).

Conclusion

In Conclusion the Newcastle virus suspension caused clear histological changes in stomach and small intestine of mice (Balb /c).

Financial Disclosure: There is no financial disclosure.

Conflict of Interest: None to declare.

Ethical Clearance: All experimental protocols were approved under the College of biotechnology, Al-Qasim Green University, Iraq and all experiments were carried out in accordance with approved guidelines.

References

1. Swayne DE , King DJ. Avian influenza and Newcastle disease. J. Am. Vet. Med. Assoc., 2003; 222 (1) :1550-1534...
2. Seal BS , King DJ , Meinersmann RJ. Molecular evolution of the Newcastle disease virus matrix protein gene and phylogenetic relationships among the paramyxoviridae. Virus .Res., 2000;66:1-11...
3. Alexander D. Newcastle disease, other avian paramyxoviruses and pneumovirus infections. In Diseases of Poultry. 4th edition. Edited by Saif YM, Barnes HJ; Glisson, JR; Fadly ,AM LRM and Swayne, D.: Iowa State University: 2003;63-99.
4. Kolakofsky D ,Roux L ,Garcin D , Ruigrok RW. Paramyxovirus mRNA editing the "rule of six" and error catastrophe: a hypothesis. J .Gen .Virol., 2005;86:1877-1869.
5. Aldous EW ,Mynn JK ,Banks J , Alexander DJ. A molecular epidemiological study of avian paramyxovirus type 1 (Newcastle disease virus) isolates by phylogenetic analysis of a partial nucleotide sequence of the fusion protein gene.

- Avian.Pathol ., 2003;32:239–256.
6. Czegledi A ,Ujvari D ,Somogyi E , Wehmann E. genome size category of avian paramyxovirus serotype 1 (Newcastle disease virus) and evolutionary implications. Virus .Res., 2005;120:36–48.
7. Diel DG , Susta L , Cardenas G , Killian ML. Complete genome and clinicopathological characterization of a virulent Newcastle disease virus isolate from South America. J .Clin. Microbiol., 2012;50:378–387..
8. Miller PJ , Decanini EL , Afonso CL . Newcastle disease: evolution of genotypes and the related diagnostic challenges. Infect .Genet. Evol. 2010;35.-10: 26.
9. OIE: Newcastle disease . In Chapter 2115 OIE Manual of Standards for Diagnostic Tests and Vaccines, in Manual of Diagnostic Tests and Vaccines for Terrestrial Animals: Mammals, Birds and Bees. Paris: Office. International .des Epizooties: 2004;270–282.
10. Herczeg J , Wehmann E , Bragg RR , Travassos D. Two novel genetic groups (VIIb and VIII) responsible for recent Newcastle disease outbreaks in Southern Africa, one (VIIb) of which reached Southern Europe. Arch .Virol ., 1999 ;144:2087–2099.
11. Munir M ,Cortey M ,Abbas M , Qureshi ZU. Biological Newcastle disease virus isolated from outbreaks in commercial poultry and from backyard poultry flocks in Pakistan. Infect. Genet. Evol ., 2012;12:1010–1019.
12. Debouck P , Pensaert M. Experimental infection of pigs with Belgian isolates of the porcine rotavirus's. Vet .MedB, 1979;26: 517-526.
13. Bhargu K , Nagendra N ,Durlav P , Sudip C. Experimental infection of pigs with group rotavirus and enterotoxigenic Escherichia coli in India gross, Histopathological and immunopathological study, Veterinaria Italiana., 2011;47 (2): 117-128.
14. Luna LG . Manual of histological staining methods of the Armed Forces Institute of Pathology, 3rd Ed. McGraw Hill. New York. 1968;195 - 196.
15. Alexander D. Newcastle disease and other avian paramyxoviruses . Rev. sci. .tech. Off. int. Epiz., 2000;19 (2): 443-462.
16. Tzipori S , Chandler D, Smith M , Makin T , Smith M. Escherichiacoli and rotavirus infection in four week old gnotobiotic piglets. fed milk or dry food. Aus.Vet.J, 1980;56:279-284. .
17. Ahmed OH ,Zahraa MA ,Khansa H. Adequacy of Magnetic Resonance Image versus Electromyography in Patients with Back Pain. J.Global Pharma Tech. 2018;10(03): 225-228
18. Ahmed OH. EFFECT OF FUMONISIN B1 ON HISTOLOGY OF SPLEEN OF BROILER CHICKEN *GALLUS GALLUS*. Biochem. Cell. Arch. 2018;18(2): 1755-1761,
19. Collins JE , Benfield DA , Duimstra JR. Comparative virulence of two porcine group A rotavirus isolates in gnotobiotic pigs .Am .J.Vet. Res., 1989;50: 827-835.
20. Theil KW , Bohl EH , Cross RF , Kohler EM , Agnes AG. Pathogenesis of porcine rotaviral infection in experimentally inoculated gnotobiotic pigs.Am.J.Vet.Res., 1978;39: 213-220..
21. Crouch C , Woode G. Serial studies of virus multiplication and intestinal damage in gnotobiotic piglets infected with Rotavirus . J. Med. Microbiol., 1978;11: 325-334...
22. Sikdar D , Rahman H , Borah P , Boro B. Occurrence of piglet diarrhoea in north-Easter India isolation, serotyping and antibiogram of Escherichia coli . Ind .J. Anim .Sci . , 1994;64:728-730.