

Combination Use of Aloe Vera and VEGF Promotes Osseointegration and Stability of Titanium Implants

Athraa Y Al-Hijazi¹; Zaid M.Akram²; Emad H Abdulla³

¹Prof.Dr. In Al-Mustaqbal University College/Dentistry Department, Babel, Iraq, ² Lecturer Dr. In Al-Rafidain university college,Baghdad,Iraq. Board in Oral And Maxillofacial Surgery, ³Ass. Prof. In College of Dentistry,IbnSina University of medical and pharmaceutical sciences,Baghdad, Iraq. M.Sc. in Oral And Maxillofacial Surgery

Abstract

Background: Aloe vera was used to enhance defense mechanisms, and it has a variety of components that affected on periodontal healing and other oral condition .It was used also around dental implants to control inflammation from bacteria contamination. Vascular endothelial growth factor(VEGF) is of particular interest because of its ability to induce neovascularization (angiogenesis), VEGF also acts to recruit and activate osteoclasts as well as stimulate osteoblast chemotaxis, differentiation, and matrix mineralization.

Aim of study: The objective of this research was to illustrate the biological actions of topical application of aloe vera and growth factor VEGF on implant tissue contact surface which is involved in osseointegration .

Materials and Method: Commercially pure Titanium(cpTi) implants with aloe vera /and VEGF ,were placed in the tibia of (24) New Zealand white rabbits, Mechanical test (torque removal test) was performed as an indicator for the presence of osseointegration and bone implant contact (BIC)measurement as a test for the property of bone-implant interface.

Histological investigation was performed on all the implants of both control and experimental groups at (1,2, and 6weeks) healing intervals.

Results: Findings illustrated that removal torque mean and BIC values in experimental implant showed high value in comparison to control. Histological results show an early bone deposition and early maturation in combination group .

Conclusions: Bone formation &maturation was accelerated by adding biological materials and using a combination of Aloe Vera and VEGF is a powerful tool for enhancement of osseointegration.

Keywords: Aloe Vera,Titanium implant,Vascular endothelial growth factor,Osseointegration,Implant

surface, Bone

Introduction

Osseointegration refers to a structural and functional fusion of the implant surface with the surrounding bone tissue ^[1,2]. Many factors may include and affect

osseointegration ^[3] such as surgical technique^[4], healthfulness of host bed^[5], implant design ^[6] , implant surface and its modification^[7], material biocompatibility and loading conditions^[8,9].

Aloe Vera is really quite an incredible plant , has used therapeutically for over 5000 years. ^[10].The bulk of the Aloe Vera leaf is filled with a clear gel-like substance, which is approximately 99% water. Aloe Vera contains over 200 active components including vitamins, minerals, amino acids, enzymes, polysaccharide, and fatty acids. The vitamins including A, C, E, folic acid, choline, B1, B2, B3 (niacin), B6^[11]. It is also one of the few plants

Corresponding Author:

Athraa al-hijazi,

Al-Mustaqbal University College, Dentistry
Department, Babel, Iraq,
Email: athraayms@yahoo.com

that contains vitamin B12, while the minerals include: calcium, magnesium, zinc, chromium, selenium, sodium, iron, potassium, copper, manganese, and important fatty acids include HCL cholesterol (which lowers fats in the blood), campesterol, and B-sitosterol^[12].

Aloe vera has been used as a popular herbal medicine since ancient times for many conditions including burns, wound healing, and in dental treatment it illustrates bone, cementum and periodontal ligament regeneration^[13,14].

Vascular endothelial growth factor (VEGF) is endothelial cell-specific mitogen that suggested a regulator of naturally occurring physiologic and pathologic angiogenesis. It stimulates endothelial cell growth, angiogenesis, and capillary permeability that accelerate healing events^[15].

The present study was planned to use an external local application of Aloe Vera and VEGF with implantation of screw and study their effect on healing and osseointegration process.

Materials and Method

Animals

A total of 24 male New Zealand White rabbits, weighing (2.5-3 kg), aged (10-12 months) were used in this study, and kept in the animal department of (National Center of Drug Control and Research /Iraq) at a constant humidity and temperature of 23°C according to the National Council's guide for the care of laboratory animals.

Materials

-Commercially pure titanium (CpTi) rods

-Aloe vera Gel 87.399%, Phyto care company.

-VEGF165, human recombinant, Bio Vision company

Methods

Commercially pure titanium (CpTi) rods (30 cm in length and 5 mm in diameter) were used to form (96) screw-shaped implants by using lathe machine. Each screw was 8 mm in length (5 mm threaded and 3 mm smooth) and the diameter was 3.5 mm in the threaded part and 4mm in the smooth part. The bottom of the screw was made flat but the head of the screw had a slit with 1.5 mm in depth to fit the screw driver of the torque

meter during insertion and removal of the implant. Then the implants were cleaned by using ultrasonic cleaning bath (Sonomatic/170-2-T80, Germany) with ethanol and acetone of 75:25 wt% ratio was carried out to removing debris and contamination from the fabricated samples. Implants were rinsed with distilled water and then dried in the oven at temperature of 100 °C. Then the implants were sterilized by using gamma radiation with a CO⁶⁰ source.

Ninety six Implants were divided as follows:

Group I :Control :24 Ti implant inserted in rabbit tibia

Group II: Experimental consists 3 subgroups

A:24 implant inserted in rabbit tibia with local application of 0.1µl of VEGF

B:24 implant inserted in rabbit tibia with local application of 0.1µl of Aloe Vera

C:24 implant inserted in rabbit tibia with local application of combination of 0.1µl VEGF and 0.1µl Aloe Vera

Surgical procedure:

Animals were anaesthetized generally with a mixture of ketamine (50 mg/kg) with xylazine (2.5 mg/kg). Surgical technique was performed to prepare holes, two holes in the left tibia in which control was inserted in one hole, & experimental (VEGF) was placed in the second one with a space 2 cm. In the right tibia one hole was prepared for the insertion of implant with experimental (AV), and other one for combination of (VEGF and AV) with a space 2 cm.

Each hole was washed by normal saline and dried gently by air. For the experimental group; 0.1µl of VEGF was applied in socket hole by using a micro-pipette and was left for one minute, while hole with 0.1µl of AV was left for two minutes. Application of a combination was done by using VEGF firstly, allow one minute followed by adding Aloe Vera and give two minutes, then insert the implant.

Eighteen animals were sacrificed after 1, 2, and 8 weeks (6 animals for each period) for histological examination.

Bone implant contact (BIC), as histomorphometry at the light microscopic level was done for the period of

8th week.

The rest sixth animals were subjected to mechanical test (torque removal test). The torque was measured with the torque wrench device (OstellTM; Savedalen, Sweden)^[16].

Radiographic evaluation

X-ray was done prior to surgery, to ensure that the bone of the tibia was sufficient to accept the implants, and immediately after the operation to ensure that the implants were properly inserted in their positions. After each healing period, both tibiae were examined radiographically again to assess bone healing around each implant.

Specimen retrieval

The implants along with their surrounding bone were excised with a surgical saw right away following the euthanasia. The excess tissue was dissected and the specimens were removed with a margin of surrounding bone of about 5–10 mm. The specimens were immediately put into the 10% formaldehyde solution.

Sample preparation for embedding


The specimens were decalcified, washed and then dehydrated in the ascending graded ethanol solution. Specimens were embedded in wax block and trimmed, the first undefined slice was removed from the saw blade and the desired section thickness was selected. Mounting and staining of slides by hematoxylin and Eosin (H&E).

Statistical methods

Mean values and standard deviations were calculated for Removal Torque test and bone implant contact (BIC) in different studied groups at sixth week measured period. ANOVA test was used to analyze the differences between the implant groups. P value <0.05 was considered significant.

Results

Radiographical evaluation The results appeared that there were no gross changes in the tibial architecture with no areas of radiolucency between implant and adjacent cortical bone in all specimens, figure(1)



Figure(1) Conventional radiographic view for implant in rabbit tibia

Mechanical test finding with BIC value.

Statistics analysis of the removal torque value and bone implant contact (BIC) value for cpTi implants for study groups at eighth week interval were recorded, the torque value that needed to remove all the experimental implant was higher than the control, BIC value records same results. Findings also illustrate a significant difference in measurements for combination (VEGF & AV) in comparison to AV/VEGF group. While a non significant difference value was recorded for the comparison of VEGF with AV. The real domain of the expected torque force and BIC that needed in this period was shown in maximum and minimum value with 95% confidence interval for means and ANOVA test (tables, 1, 2, 3).

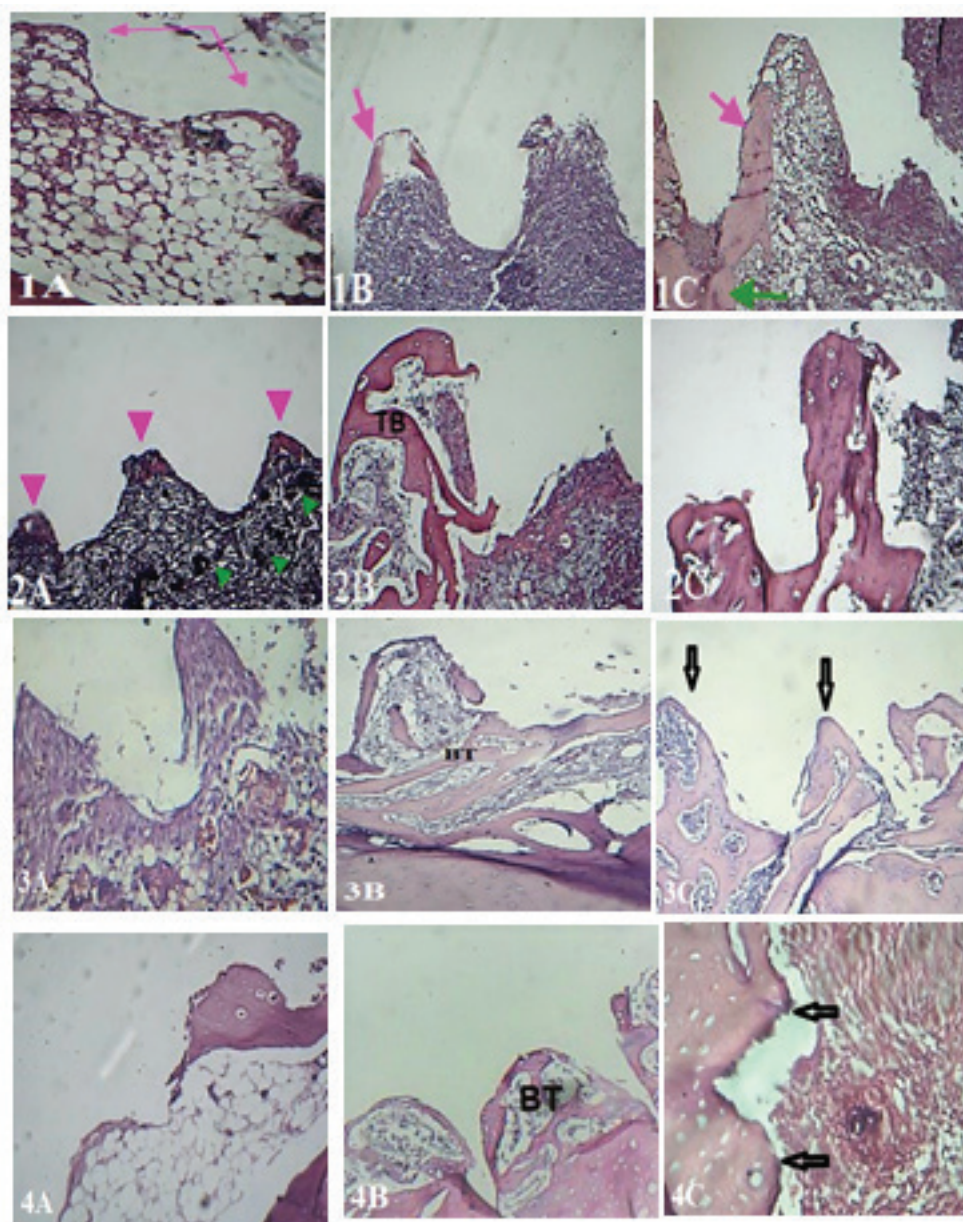
Histological findings

In control group and at 1st week, osteoid tissue formation was detected at the apex of threads, then bone trabeculae was illustrated at the 2nd week. At eighth week a new lamellated bone showed in the base of implant bed that coalesce with bone thread.

Histological features for experimental group (VEGF), at 1st week, showed osteoid deposition on the apex of the threads, then bone trabeculae mostly filled the threads at the 2nd week. At the eighth week an immature bone with osteon was observed.

In experimental group (AV) and at 1st week, osteoid tissue formation was detected at the apex of threads, then bone trabeculae filled most of implant bed was illustrated at the 2nd week. At eighth week an immature bone was observed.

Experimental group (combination VEGF&AV) ,at 1st week ,showed an early formation of bone trabeculae on the apex thread , then it filled all the apex at the 2nd week.A mature bone with haversian system was illustrated at eighth week.Figure(2)



Figure(2) Implant views for studied groups shows developing threads at periods (1,2 &6 weeks)

1A:Shows threads (arrows) for control 1week.H&Ex10

1B:Shows thread(arrow) with bone apposition for control 2week.H&Ex10

1C :Shows thread (pink arrow) with bone formation extend to implant bed (green arrow)for control 8week.H&Ex20

2A:Shows threads (pink arrows) with developing blood vessels(green arrow heads) at implant bed for VEGF group,at 1week. H&Ex4

2B: Trabeculated bone (TB)fill most of thread for VEGF group,at 2week. H&Ex10

2C :Immature bony threads for VEGF group,at 8week. H&Ex10

3A:Shows threads for AV group,at 1week. H&Ex10

3B:Bone trabecule (BT) mostly filled bed thread for AV group,at 2week. H&Ex10

3C:Immature bony threads for AV group,at 8week. H&Ex10

4A:Shows threads for combination group,at 1week.H&Ex10

4B:Bone trabecule (BT)fill most of thread for combination group,at 2week. H&Ex10

4C :Mature bony threads for combination group,at 8week. H&Ex20

Table(1) Statistics analysis for Removal Torque test in different studied groups at 8th week measured periods.

Torque-test (Ncm)										
Period	Material	Groups	No implant	Mean	Std. Dev.	Std. Error	95% Confidence Interval for Mean		Min.	Max.
							Lower Bound	Upper Bound		
Eighth week	VEGF	Exp.VEGF	6	23.16	0.60	0.33	22.20	25.11	22.36	24.66
	AV	Exp.AV	6	22.16	0.89	0.44	21.33	24.45	20.65	24.22
	AV & VEGF	Exp.AV & VEGF	6	28.55	1.60	0.80	26.95	30.65	27.13	30.13
	without	control	6	17.88	0.79	0.39	16.45	19.22	16.88	18.95

Table(2)Statistics analysis for BIC test in different studied groups at 8th week measured period.

BIC test										
Period	Material	Groups	No implant	Mean	Std. Dev.	Std. Error	95% Confidence Interval for Mean		Min.	Max.
							Lower Bound	Upper Bound		
e i g h t h week	VEGF	Exp.VEGF	6	23.24	1.13	0.23	22.20	24.22	22.22	24.58
	AV	Exp.AV	6	25.22	1.01	0.66	23.55	26.44	23.66	27.03
	AV&VEGF	Exp. AV&VEGF	6	29.54	0.54	0.66	27.95	30.65	28.13	30.77
	Without	Control	6	11.62	1.94	0.33	10.45	13.22	10.88	13.45

Table(3) LSD after ANOVA test for removal torque and BIC in 8th weeks distributed among different groups

parameters	Group		Mean Diff.	Sig.	C.S. (*)
Removal torque	Control	VEGF	-7.20	0.000	HS
		AV	-6.88	0.000	HS
		Combination	-5.0	0.000	HS
	VEGF	AV	0.55	0.334	NS
		Combination	-1.60	0.020	S
	AV	Combination	-1.30	0.011	S
BIC	Control	VEGF	-1.40	0.050	S
		AV	-1.50	0.022	S
		Combination	-5.04	0.000	HS
	VEGF	AV	0.43	0.676	NS
		Combination	-1.60	0.040	S
	AV	Combination	0.55	0.543	NS

* $P \leq 0.001$: high significant, $P \leq 0.05$: significant, $P \geq 0.05$: non significant

Discussion

Aloe Vera is a well known plant in Iraq. Because of its use in folk medicine as a wound-healing agent, and in cosmetic preparation, and even widely used by public Iraqi people as mask face and in burn condition. On other hand using of VEGF was documented to enhance healing. Therefore we involved using of Aloe Vera with VEGF with implantation and study their effect on bone healing activity and osseointegration.

The present study shows an early osteoid deposition in VEGF group as osteoid tissue formation. These results could be attributed to, that the traumatic site includes, stem cells differentiate into osteoblasts (Catharino et al., 2014)^[17] that enhanced by exogenous vascular endothelial growth factor (VEGF) which has been implicated in angiogenesis, and the proliferative osteoblast and active osteocyte were included in deposition of collagen fiber. Same results was illustrated

for AV group.

We found also an advance osseointegration sign with early bone maturation in experimental group and specifically combination group, moreover removal torque and BIC values were higher in combination group in comparisum to AV, VEGF and control groups at the studied period.

These results may due to the followings

1. Action of Aole Vera include: anti-inflammation, antimicrobials, healing promotion, and biological/immunological modulation^[12,18,19]
2. Aole Vera stimulate hard tissue formation include bone^[20,21].
3. Aole Vera act as a bioactive molecule and scaffold for implant bed regeneration.^[22,23]

4. Angiogenic potential of VEGF is effective to constitute an enhancement effect for developing bone. [24,25,26]

5. The present findings establish proof that the angiogenic activity of VEGF or the stimulation enhancement of AV is insufficiently potent as compared to combination of AV with VEGF to achieve therapeutic benefit.

Conclusions

Our data suggest that Aloe Vera could be a candidate biomolecule for osseointegration that affect on bone -implant interface tissue regeneration. And a combination of AV with VEGF represent a such a new strategy that might ultimately be applicable to enhance implant stability and integration.

Acknowledgment: This work was supported by Prof. Dr. Hasan Majdi Dean of Al-Mustaqbal University College/ Babel, Iraq

Source of Funding- by ours

Conflicts of Interest: The author declares no conflict of interest.

Ethical Clearance- all work of this study had done according to the National Council's guide for the care of laboratory animals.

References

1. Lotz EM, Berger MB, Schwartz Z, Boyan BD. Regulation of osteoclasts by osteoblast lineage cells depends on titanium implant surface properties. *Acta Biomater.* 2018 Mar 1;68:296-307.
2. Walsh WR, Pelletier MH, Christou C, He J, Vizesi F, Boden SD. The in vivo response to a novel Ti coating compared with polyether ether ketone: evaluation of the periphery and inner surfaces of an implant. *Spine J.* 2018 Jul;18(7):1231-1240.
3. Carlos, N.E. (2011). Factors Affecting the Success of Dental Implants, *Implant Dentistry - A Rapidly Evolving Practice*, Prof. Ilser Turkyilmaz (Ed.) ISBN: 978-953-307-658-4.
4. Al-Sabbagh M, Eldomiaty W, Khabbaz Y. Can Osseointegration Be Achieved Without Primary Stability? *Dent Clin North Am.* 2019 Jul;63(3):461-473.
5. Soncini, M., Baena. R.R., Pietrabissa, R., Quaglini, A., Rizzo, S., and Zaffe, D. (2002). Experimental procedure for the evaluation of the mechanical properties of the bone surrounding dental implant, *Biomaterial.* 2002;23: 9-17.
6. Dávila E, Ortiz-Hernández M, Perez RA, Herrero-Climent M, Cerrolaza M, Gil FJ. Crestal module design optimization of dental implants: finite element analysis and in vivo studies. *J Mater Sci Mater Med.* 2019 Jul 25;30(8):90.
7. Kozlova MV, Mkrtumyan AM, Bazikyan EA, Belyakova AS, Dzikovitskaya LS. [Effect of dental implants with conditioned surface based on sodium hydroxide in patients with osteoporosis]. *Stomatologiya .* 2019;98(3):46-51.
8. Huynh V, Ngo NK, Golden TD. Surface Activation and Pretreatments for Biocompatible Metals and Alloys Used in Biomedical Applications. *Int J Biomater.* 2019 Jun 2;ID3806504:21
9. Su Y, Cockerill I, Zheng Y, Tang L, Qin YX, Zhu D. Biofunctionalization of metallic implants by calcium phosphate coatings. *Bioact Mater.* 2019 May 20;4:196-206.
10. Somboonwong J, Duansak N. The therapeutic efficacy and properties of topical Aloe vera in thermal burns. *J Med Assoc Thai.* 2004 Oct;87 Suppl 4:S69-78.
11. Maenthaisong R, Chaiyakunapruk N, Niruntraporn S, Kongkaew C. The efficacy of aloe vera used for burn wound healing: a systematic review. *Burns.* 2007 Sep;33(6):713-8.
12. Hajhashemi V, Ghannadi A, Heidari AH. Anti-inflammatory and wound healing activities of Aloe littoralis in rats. *Res Pharm Sci.* 2012 Apr;7(2):73-8.
13. Ke F, Yadav PK, Ju LZ. Herbal medicine in the treatment of ulcerative colitis. *Saudi J Gastroenterol.* 2012 Jan-Feb;18(1):3-10.
14. Chantarawatit P, Sangvanich P, Banlunara W, Soontornvipart K, Thunyakitpisal P. Acemannan sponges stimulate alveolar bone, cementum and periodontal ligament regeneration in a canine class II furcation defect model. *J Periodontal Res.* 2013 Apr;49(2):164-78.

15. Takeshita S, Zheng Lp, Brogi E, Kearney M, Pu L Q, Bunting S, Ferrara N, et al. Therapeutic angiogenesis .A single intraarterial bolus of VEGF augments revascularization in a rabbit ischemic hind limb model. *J Clin Invest.* 1994 February, 93(2):662–670.
16. Barros RR, Novaes Jr AB, Muglia VA, Iezzi G, Piattelli A. Influence of interimplant distances and placement depth on peri-implant bone remodeling of adjacent and immediately loaded Morse cone connection implants: a histomorphometric study in dogs. *Clin Oral Implants Res.* 2010 ,21(4):371–8.
17. Catharino PC., Dominguez GC., Pinto Ddos S. Jr., Morea C..Histologic, Histomorphometric, and Radiographic Monitoring of Bone Healing Around In-Office-Sterilized Orthodontic Mini-implants With or Without Immediate Load: Study in Rabbit Tibiae. *Int J Oral Maxillofac Implants.* 2014,29(2):321-30.
18. Boonyagul S, Banlunara W, Sangvanich P, Thunyakitpisal P. Effect of acemannan, an extracted polysaccharide from Aloe vera, on BMSCs proliferation, differentiation, extracellular matrix synthesis, mineralization, and bone formation in a tooth extraction model. *Odontology.* 2013 ,102(2):310-7.
19. Jittapiromsak N, Sahawat D, Banlunara W, Sangvanich P, Thunyakitpisal P. Acemannan, an extracted product from Aloe vera, stimulates dental pulp cell proliferation, differentiation, mineralization, and dentin formation. *Tissue Eng Part A.* 2010 Jun, 16(6):1997-2006.
20. Jettanacheawchankit S, Sasithanasate S, Sangvanich P, Banlunara W, Thunyakitpisal P. Acemannan stimulates gingival fibroblast proliferation; expressions of keratinocyte growth factor-1, vascular endothelial growth factor, and type I collagen; and wound healing. *J Pharmacol Sci.* 2009 Apr, 109(4):525-31.
21. Chavhan SG, Brar RS, Banga HS, Sandhu HS, Sodhi S, Gadhave PD, Kothule VR, Kammon AM. Clinicopathological Studies on Vitamin D(3) Toxicity and Therapeutic Evaluation of Aloe vera in Rats. *Toxicol Int.* 2011 Jan, 18(1):35-43.
22. Gupta R, Flora SJ. Protective value of Aloe vera against some toxic effects of arsenic in rats. *Phytother Res.* 2005, 19:23–8.
23. Etim OE, Farombi EO, Usuh IF, Akpan EJ. The protective effects of Aloe vera juice on lindane induced hepatotoxicity and genotoxicity. *Pak J Pharm Sci.* 2006, 19:337–40
24. Al - Hijazi A.Y., Fadhil E. The role of local exogenous application of VEGF: N- acetyl D-glucosamine on bone healing (experimental study). *The Journal of Materials Science. Photon* .2014, 120:166-174.
25. Joensuu K, Uusitalo L, Alm JJ, Aro HT, Hentunen TA, Heino TJ. Enhanced osteoblastic differentiation and bone formation in co-culture of human bone marrow mesenchymal stromal cells and peripheral blood mononuclear cells with exogenous VEGF. *Orthop Traumatol Surg Res.* 2015 May, 101(3):381-6.
26. Al-Hijazi, A.Y.; Al-Mahammadawy, A.A. Role of Topical Application of Growth Factors on Periodontal Repair. *Nat. Sci.* 2016, 6:351-361.