

A Study of Age Estimation by Radiological Assessment of Ossification Centers at Hand Wrist and Elbow Joint at a Tribal Teaching Medical College of Adilabad

B Shekhar Rao¹, Mohd Inayatulla Khan²

¹Associate Professor, Department of Forensic Medicine and Toxicology, Rajiv Gandhi Institute of Medical Sciences [RIMS], Adilabad, ²Assistant Professor, Department of Physiology, Rajiv Gandhi Institute of Medical Sciences [RIMS], Adilabad.

Abstract

Background: Radiological assessment of the skeletal ages is an important tool for the estimation of age in the living. Such data can be very useful for forensic practitioners especially in developing countries some of the population is uneducated where the birth records are not present.

Methods: This retrospective study was conducted in the Department of Forensic Medicine and Toxicology, Rajiv Gandhi Institute of Medical Sciences [RIMS], Adilabad. A total of n=26 males and n=46 females cases were examined for the ossification at 4 areas which include left-Hand epiphyses (the distal end of radius and ulna), Base of the first metacarpal and Conjoint Epiphyses. The assessment of radiographic images of hand and elbow joints was based on the revised method for epiphyseal union assessment.

Results: The mean ages at ossification for stage I in males were found to be 12.90 years. At stage II we found the mean age of 15.18 years. In stage III we found the mean age of 16.15 years and stage IV the mean age value at all ossification centers was 19.18 years. Similarly for females the mean values of all ossification centers at the stage I estimated the age of 14.12 years. In stage II the mean age estimated was 15.27 years and stage III the mean age estimated was 16.29 years and stage IV mean age estimated was 17.96 years.

Conclusion: Within the constraints of the present study we found that hand wrist and elbow joint radiographs are very useful for estimation of bone age in cases up to 18 years of age. We used digital radiographs along stages for determining the degree of ossification which has a greater degree of reproducibility and reliability.

Keywords: Age Estimation, Radiological Assessment, Ossification Centers, distal end of radius ulna

Introduction

Age determination for the individual has considerable importance in the medicolegal field. It is well known that accurate estimation of a living person can prove to be important for humanitarian, administrative, and

legal purposes especially in cases when the subject is considered as minor (Child). The UN Convention on rights of child defines a 'child' as every human below the age of 18 years. [1] The signs of progress of ossification and changes during various periods of development can be studied by means of X-rays in living individuals and these changes are age-related. [2] Therefore it is possible to determine the approximate age of an individual by radiological examination of the bone till ossification is complete. [3] the most commonly used regions for the radiographic evaluation of skeletal age in the left hand and wrist, the elbow joint, and the medial epiphysis of right clavicle all are considered useful when the subject in question is less than 21 years of age. There are a number

Corresponding Author:

Dr. B Shekhar Rao,

Associate Professor, Department of Forensic Medicine and Toxicology, Rajiv Gandhi Institute of Medical Sciences [RIMS], Adilabad.

Email: bsraorims@gmail.com Mobile: 9603265855.

of factors that affect the stage of epiphyseal union which includes geographic distribution, socioeconomic status, climate, nutrition, and genetics. [4, 5] Ethnicity is also very important when this kind of study done in a neglected population. With this background, we in the present study tried to evaluate the age as determined by the stages of ossification at centers in our predominantly tribal population. There is hardly any data of such a study done in the tribal region of Adilabad.

Material and Methods

This retrospective study was conducted in the Department of Forensic Medicine and Toxicology, Rajiv Gandhi Institute of Medical Sciences [RIMS], Adilabad. The radiographs were taken as a part of the medicolegal examination for age determination requested by law enforcement agencies in cases where there were no official birth certificates of the individual or where there was a dispute of age. We examined the digital radiographs of all the cases from Jan 2018 to December 2019. Institutional Ethical committee permission was obtained for the study. The inclusion criteria were medicolegal cases of both sexes reporting for age determination to our institute, availability of digital x-ray records of the cases. Exclusion criteria were cases with fractures of the epiphysis, congenital anomalies of bones, or cases with bone disorders. A total of n=26 males and n=46 females cases were examined for the ossification at 3 areas which include left-Hand epiphyses (the distal end of radius and ulna), Base of the first metacarpal and Conjoint Epiphyses. The assessment of radiographic images of hand and elbow joints was based on the revised method for epiphyseal union assessment by S. S. Bhise et al; [2]. Stage 0 is a radiolucent area observed between epiphysis and diaphysis. In stage I there is a continuous radiolucent gap between epiphysis and diaphysis separable at extremes. Stage 2 is the presence of a radiopaque line between epiphysis and diaphysis. In stage 3 there a continuous radiopaque line called union scar. In stage 4 there is the disappearance of both epiphysis and diaphysis and bone is fused as one. All the x-rays were examined by a single observer and the available data was entered in MS Excel spreadsheet the mean of age at various stages of ossification was determined and graphs were plotted. Finally, the mean of ossification at 3 centers with stage 1, stage 2 stage 3 and stage 4 were calculated and plotted as shown in

Graph 4.

Results

In the present study a total of n=26 male and n=46 female cases. We assessed in all the cases radiographic ossification stages at 3 places which includes hand epiphyses (distal end of radius and ulna), the base of the first metacarpal, Conjoint Epiphyses, and details given in table 1.

The minimum age based on the stage of ossification at the hand epiphyses (the distal end of radius and ulna) in males was 11.1-12 years and the maximum age based on the ossification at hand epiphyses was found to be 22.1 – 23 years. We did not have any case of stage 0 in this study. Out of n=26 males, n=9 cases were found in stage I ossification the mean age was found to be 13.52 years. In stage II there was a single case with a mean age of 15.5 years. In stage III n=4 cases with a mean age were 16.45 years and in stage IV n=12 cases the mean age was 19.7 years. The mean age of all the patients was plotted in graph 1.

In females for hand epiphyses (the distal end of radius and ulna) minimum and maximum age based on ossification stages were estimated at 13.1 – 14 years and 19.1 – 20 years respectively. Out of n=46 cases, n=8 cases were found in stage I with a mean age of 14 years. Stage II n=22 cases were present with a mean age of 15.17 years. Stage III there were n=9 cases with a mean age of 16.32 years and in stage IV n= 7 cases with a mean age of 17.86 years graph 1.

The age estimation as per the base of first metacarpal ossification in radiographs in males found the minimum age was 11.1-12 years and the maximum age was estimated at 22.1 to 23 years. In stage I ossification we found n=7 cases with the mean age estimated at 12.94 years. In stage II n=3 cases with the mean age of 15.16 years. In stage III there were n=2 cases with a mean age of 16.5 years and in stage IV n=14 cases with the mean age of 19.06 years total of n=26 cases. Graph 2 shows the mean age at various stages of ossification.

Radiographic age estimation by assessing the base of the first metacarpal in females (n=46) found the minimum age of 13.1-14 years and the maximum age was 19.1-20 years. There was no case in stage 0

ossification in stage I ossification there were n=4 cases with mean age estimated to be 14.56 years. In stage II n=24 cases with a mean age of 15.14 years. Stage III n=4 cases with a mean age of 16.25 years. In stage IV n=14 cases with a mean age of 17.94 years given in graph 2.

The ossification of Conjoint Epiphyses in the humerus for males estimated the minimum age of 11.1-12 years and the maximum age of 22.1 to 23 years. There were n=2 cases in stage I with a mean age of 12.25 years and n=6 cases in stage II with a mean age of 14.88 years and stage III n=2 cases mean age of 15.5 years and stage IV n=16 cases with a mean age of 18.8 years given in graph 3.

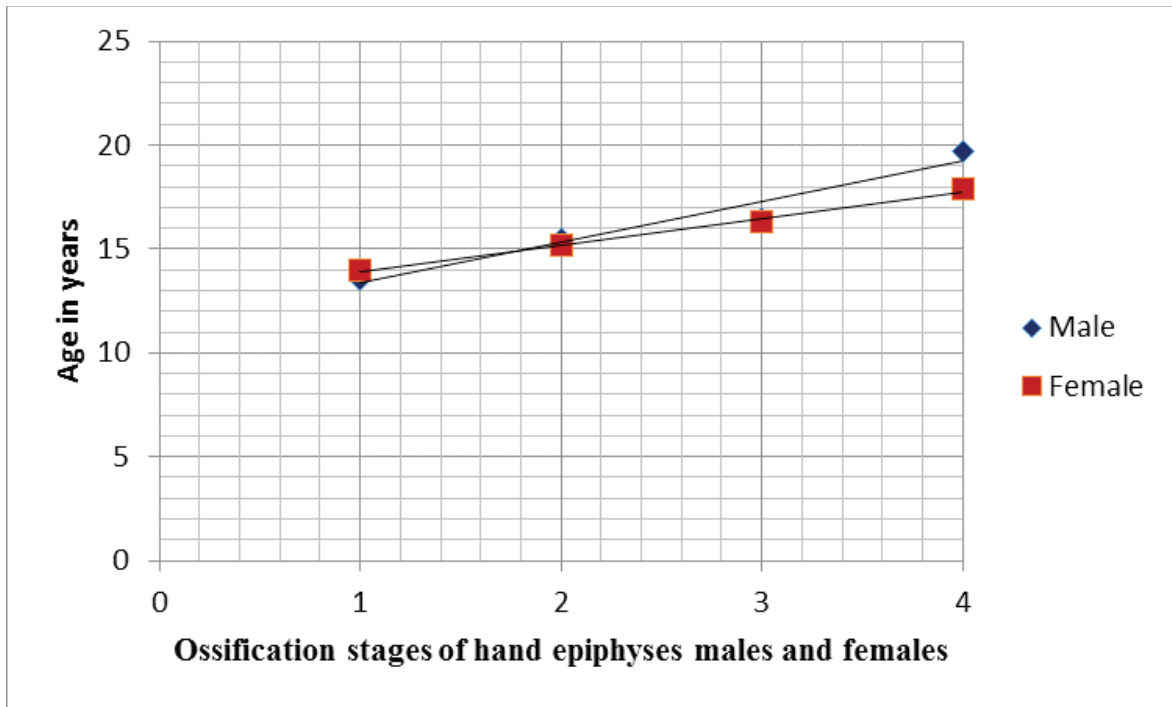
The ossification stages of Conjoint Epiphyses in females revealed the age ranges from 13.1-14.0 years minimum to 19.1-20 years maximum. In stage I

ossifications there were n=3 cases mean age 13.8 years. In stage II n=4 cases with mean age 15.5 years. In stage III there were n=4 cases with mean age 16.3 years and in stage IV there were n=35 cases with a mean age of 18.1 years shown in graph 3.

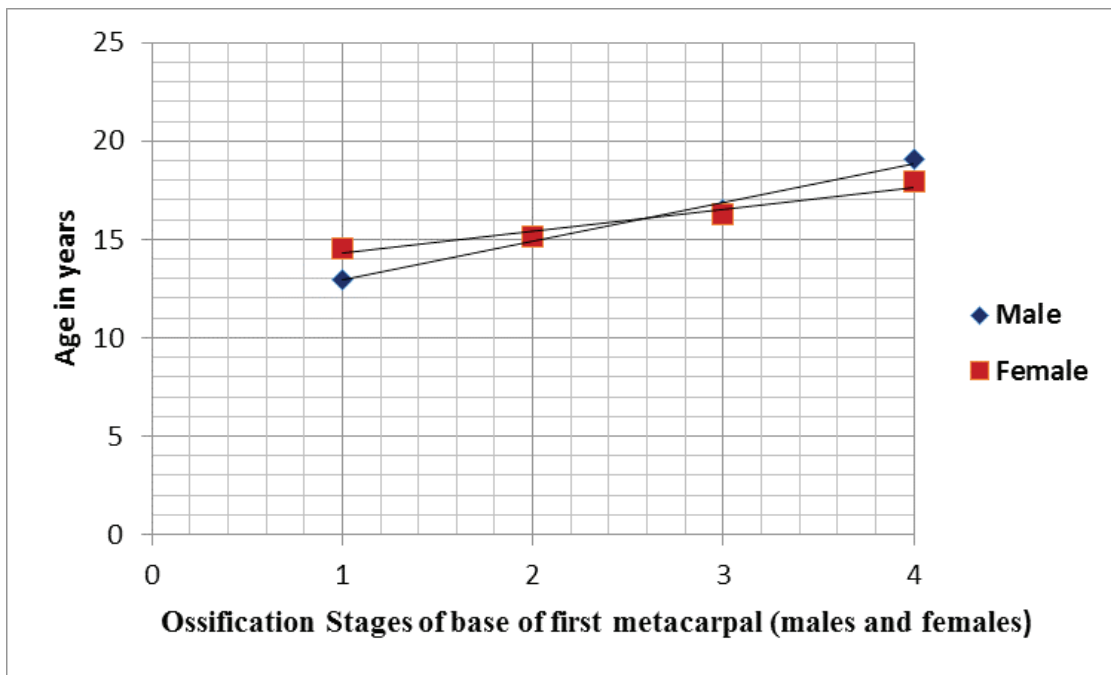
The mean ages at ossification Stage I at various centers was plotted in male and the mean value obtained for stage I ossification was found to be 12.90 years. At stage II we found the mean age of 15.18 years. In stage III we found the mean age of 16.15 years and stage IV the mean age value at all ossification centers was 19.18 years given in graph 7. Similarly for females the mean values of all ossification centers at the stage I estimated the age of 14.12 years. In stage II the mean age estimated was 15.27 years and stage III the mean age estimated was 16.29 years and stage IV mean age estimated was 17.96 years shown in graph 4.

Table 1: Showing the number of cases and stages of ossification based on radiographic evaluation at various centers

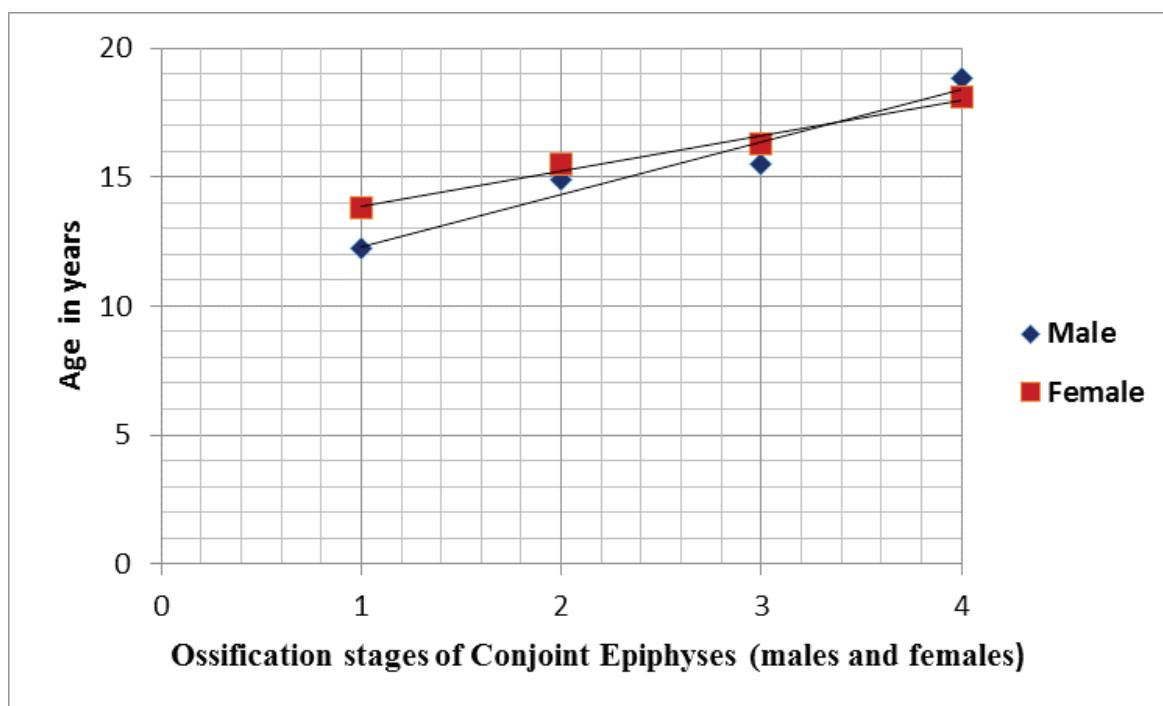
No of Patients (N)	Stages of Ossification					No of Patients (N)	Stages of Ossification				
	0	1	2	3	4		0	1	2	3	4
	Staging of Hand epiphyses (Male)						Staging of Hand epiphyses (Female)				
26	0	9	1	4	12	46	0	8	22	9	7
	Staging of Base of first Metacarpal (Male)						Staging of Base of first Metacarpal (Female)				
26	0	7	3	2	14	46	0	4	24	4	14
	Staging of Conjoint Epiphyses (Male)						Staging of Conjoint Epiphyses (Female)				
26	0	2	6	2	16	46	0	3	4	4	35



Graph 1: Showing the mean age at different ossification stages of hand epiphyses (males and females)



Graph 2: Showing the mean age at different ossification stages of base of first metacarpal (males and females)



Graph 3: Showing the mean age at different ossification stages of Conjoint Epiphyses (males and females)

Discussion

The present study was done in n=26 male and n=46 females the male to female ratio was 1:1.76. This study consisted of a predominantly tribal population of Adilabad District in Telangana State with different ethnicity, race, socioeconomic status and residency, and these factors do impact the epiphyseal union. In a country as diverse as India, it is difficult to follow a simple standard for determination of age across the entire country. We in the present study estimated the ossifications at 3 centers and mean values were considered this will negate the small variations between the different stages at different centers. Previous studies have shown that union age for each epiphyseal plate at the knee joint and hand joint has similar union stages. [2, 6] A study by Majed O. Aljuaid et al; [7] showed a stronger correlation of the hand joint bones both males and females as compared to knee joint for estimation of age accurately. In the present study, we found in males the average age at stage I (beginning of union) was 12.90 years and stage IV (complete union) was 19.18 years. For females Stage, I (beginning of union) was 14.12 and stage IV (complete union) was 17.96 years. It shows that the average age of fusion is higher in males as compared to females. The female subjects commence

fusion at the age of 13 - 14 years of age and complete it by 17-18 years while the male subjects commence fusion at 14-15 years and complete it at 19- 20 years. A study by S Krishnamoorthy et al; [8] found that complete fusion of distal end of the ulna was found in 18-19 years in males and 17 – 18 years in females. In the current study, we found the distal end of ulna fused with shaft completely at 19.7 years in males and 17.86 years in females agreeing with the results of the above study. Other studies in India by Hepworth in Punjab [9], Kothari in Marwar [10], and Sunil et al; [11] all have found similar results across India. S. Shanmugasundaram et al; [12] found the base of the metacarpal fusion was completed from 15 to 19 years. The average age range of fusion of 4th and 5th metacarpals ranges from 15 – 17 years in girls in boys' fusion occurs between 17 to 18 years. In our study, we found the base of the first metacarpal in boys ossified completely by 19 years, and in females, it occurred at 17.94 years. In our study, we found in boys the Conjoint Epiphyses was in stage 3 unions at 15.5 years and stage IV was at 18.8 years and in females, Conjoint Epiphyses was in stage 3 unions in 16.3 and stage IV in 18.1 years. Similar observations have been found by Lal et al; [13] and Jain S [14]. Although we found that in several studies they have used different criteria

for evaluation of ossifications hence there may be some variations between the results of the present study compared to the other studies.

Conclusion

Within the constraints of the present study, we found that hand wrist and elbow joint radiographs are very useful for estimation of bone age in cases up to 18 years of age. We used digital radiographs along stages for determining the degree of ossification which has a greater degree of reproducibility and reliability. Although several studies have been conducted for age estimation using radiographs there was no uniform method of assessment of age. We hope that in future a standardized method could be adopted for wider application across the country.

References

1. Catalin Dogaroiu, Marian Avramoiu. Correlation between chronological age and the stage of union of the distal femur and proximal tibia epiphyses in a Romanian sample population. *Rom J Leg Med* 2015; (23) 171-76.
2. Bhise, S.S., Chikhalkar, B. G., Nanandkar, S. D., Chavan, G. S. Anand P. Rayamane. Age Determination from of Ossification Center Fusion around Knee Joint in Mumbai Region: A Radiological Study. *J Indian Acad Forensic Med* 2015; 37(1):19-23.
3. Sharma Yogesh, Bohra Bhavesh Buri Sanjeev. A prospective roentogenological study in Mewar Region of Rajasthan to establish age group 16 to 18 years. *Medico-Legal Update* 2013; 13: 17-20.
4. K. S. Nemade, N. Y. Kamdi, M. P. Parchand. Ages of epiphyseal union around wrist joint - A radiological study. *Journal of the Anatomical Society of India* 2010; 59(2):205-10.
5. S. Patond, B. Tirpude, P. Murkey, P. Wankhade, N. Nagrale, V. Surwade. Age determination from the epiphyseal union of bones at ankle joint in girls of central India. *Journal of Forensic Medicine, Science and Law* 2012; 21(2): 1-6.
6. J. E. O'Connor, C. Bogue, L. D. Spence, J. Last. A method to establish the relationship between chronological age and stage of union from radiographic assessment of epiphyseal fusion at the knee. An Irish population study. *Journal of Anatomy* 2008;212(2): 198-209.
7. Majed O. Aljuaid, Osama R. El-Ghamry. Determination of Epiphyseal Union Age in the Knee and Hand Joints Bones among the Saudi Population in Taif City *Radiology Research and Practice* 2018; Volume 2018: 1-9.
8. Sanjeev Krishnamoorthy, O. Murugesu Bharathi, Rajesh D.R., Roop Kumar, Abhishek Singh, Hitesh Chawla. Age Determination from Radiological Investigation of Epiphyseal Appearance and Fusion around Wrist Joint: A Cross-Sectional Study from Khammam Region. *Sch. J. App. Med. Sci.*, 2016; 4(7F):2685-89.
9. Hepworth SN. On the determination of age in Indians from a study of ossification of the epiphysis of long bones. *Ind Med Gaz* 1929; 64-128.
10. Kothari DR; Age of epiphyseal Fusion at elbow and wrist joints in Marwar region of Rajasthan. *J Ind Med Asso.* 1974; 63(8):252-56.
11. Sunil KS, Viswanathan KG; Age estimation radiologically from epiphyseal Fusion at wrist joint among subjects in Davanagere District. *Indian Journal of Forensic Medicine and Toxicology*; 2012;6(2). 195-98.
12. Sivakumar Shanmugasundaram. K. Thangaraj, O Ghambir Singh. Radiological assessment of age of adolescents from wrist joint. A prospective study of 151 cases. *IAIM* 2015; 2(1):95-99.
13. Lal R, Nat BS. Age of epiphyseal union at the elbow and wrist joints among Indians. *Indian Journal of Medical Research* 1934; 21(4): 683-689.
14. Jain S. Estimation of age from 13 to 21 years. *Journal of Forensic Medicine and Toxicology* 1999; 16(1):27-30.