

Immediate Denture – A Case Report

Praveen P¹, Ragavendra Jayesh², Sanjna Nayar³

¹Final year, Post Graduate, ²Principal, ³Head of the Department, Department of Prosthodontics, Sree Balaji Dental College & Hospital, BIHER

Abstract

Esthetics is an important consideration for patients undergoing dental treatment. Patients always want an immediate prosthesis before intervening any treatment option. Hence a fabrication of denture placement immediately after the extraction of teeth is precise one. Immediate denture is the best option for functional, esthetics purpose as well as patients need.

Keywords; immediate denture, esthetics, function

Introduction

Esthetics is always a prime consideration for a patient seeking dental treatment. Thus, dentist should be skilled enough to fulfill the patient expectation. An immediate denture is a versatile option which can be given to a patient who's main consideration is esthetics¹. Immediate dentures are denture constructed before all of the remaining teeth have been removed and are inserted immediately following removal of remaining natural teeth.

Definition

- Any fixed or removable dental prosthesis fabricated for placement immediately following the removal of natural tooth or teeth² – GPT9
- According to Heartwell “an immediate complete denture is a dental prosthesis constructed to replace the lost structure and associated structure of the maxillae and/ or mandible and inserted immediately following removal of remaining teeth”

A Case Report

A 64 years, female patient came to the Department of Prosthodontics, Sree Balaji Dental College & Hospital with a chief complaint of difficulty in chewing food due to mobility of the fixed prosthesis placed in the upper arch. The patient presented no significant medical history.

On clinical examination (fig 1 and 2) and radiographic assessment revealed metal ceramic fixed partial denture in 24 to 12 region (fig 3). The patient was advised for extraction of the teeth due to the mobility of fixed prosthesis and fabrication of interim immediate denture was planned. The patient signed the informed consent, and accepted the treatment plan for an interim immediate denture.

Procedure

- The primary impression was made with irreversible hydrocolloid impression material (Zhermack-tropicalgin, Badia Polesine [Rovigo] Italy). The cast was poured in type-3 dental stone (DPI, Mumbai, Maharashtra, India) (fig 4 and 5). The wax spacer (Modelling wax No 2 - Hindustan Dental Products, chapel road, Hyderabad) of two sheet thickness on an edentulous area and one sheet thickness on the dentulous area was adapted. The custom tray was fabricated with VLC tray material (Poly tray- Delta, Germany). Border molding was done, the wax spacer was removed, relief holes were made, tray adhesive was applied, and final

Corresponding Author:

Dr. Sanjna Nayar

Head of the Department, Department of Prosthodontics, Sree Balaji Dental College & Hospital
Velachery Main Road, Narayanapuram - Pallikaranai
Chennai-100, Email: nayarsanjna@gmail.com

impression was made with medium-body addition silicone impression material.

- The Jaw relation was recorded and teeth arrangement was done. The remaining teeth were removed from the cast. The denture was fabricated before the extraction of remaining teeth. The mobile teeth are extracted under local anaesthesia (fig 6). The denture was inserted on the same appointment (fig 7). Post insertion instructions were given and the patient was recalled after 1 day.

Discussion

Immediate denture is a valuable and reliable treatment option when proper case selection, treatment planning and other procedures are followed carefully. Success of this treatment procedure depends on various factors like case selection, diagnosis and treatment planning, proper surgical protocol, accurately contoured and finished prosthesis and eagerness of the patient towards the treatment.

Case selection is one of the important factors for planning immediate denture. Certain cases are not eligible for immediate denture treatment option. This can be identified by initial examination of the patient.

Extraction must be carried out in a least traumatic way. Errors like fracture of cortical plate, tearing of mucoperiosteal flap must be avoided, which may reduce the rate of success of the treatment³.

To attain the maximum degree of success, the immediate denture should fulfil the following requirements such as

- Bio-compatibility with oral environment,
- Restore the masticatory performance,
- Harmony with the following functions like - speech, respiration, mastication, and deglutition, esthetics and preservation of the remaining tissues⁴.

When patients require total extraction and an immediate complete denture, clear acrylic surgical stent may be fabricated to act as a guide to the surgeon while bone contouring. This will ensure a comfortable wearing of the prosthesis immediately after extraction³.

The immediate denture can protect the surgical site, and its appearance is usually excellent, because natural teeth serve as a guide for positioning of denture teeth⁴. Immediate dentures are very satisfying treatment modality for both patient and dentists. The patient gets the benefits of improved confidence, comfort, and functional needs. The dentist also finds satisfaction in providing a very acceptable treatment to the patients.

Immediate denture is a more challenging one for the dentist due to inadequate support from the tooth and try-in procedure is not possible during this treatment. Sometimes patient satisfaction may be compromised during initial placement. Hence patient cooperation is needed. Every necessary clinical step should be explained to the patient before starting the treatment⁵.

The advantages of immediate dentures are help to control haemorrhage, prevent contamination and provide protective covering over the wounds⁶.

The interim immediate denture was successful in fulfilling the requirement of the patient. The initial retention and stability are good and patient was also satisfied with esthetics. It should provide the restoration of phonetics and masticatory functions and facilitates transition of the edentulous state.

However, this prosthesis was intended for use as an immediate interim denture. Follow-up was done regularly. After complete healing of ridge, conventional complete denture was fabricated for the patient.

Conclusion

From this clinical report it was concluded that immediate denture is a satisfactory treatment for both patient and dentist. It fulfils patient needs, physiologic function as well as the esthetic concerns regarding treatment option. Hence placement of immediate prosthesis after the extraction of teeth, provide beneficiary condition from patient towards the dentist.

Fig 1: Intra Oral Examination

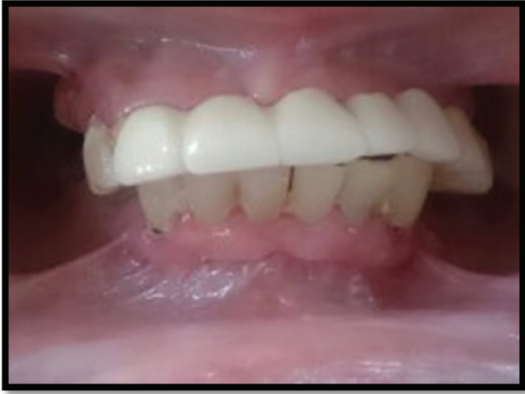

Fig 1: Intra Oral Examination

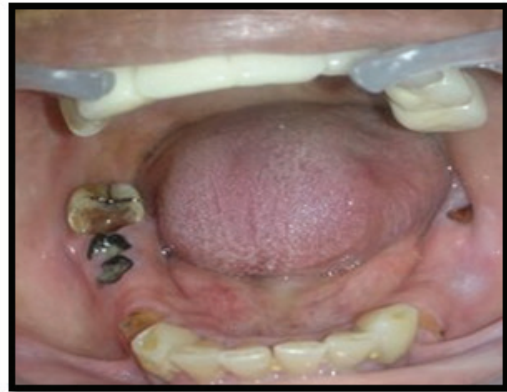

Fig 2: occlusal view

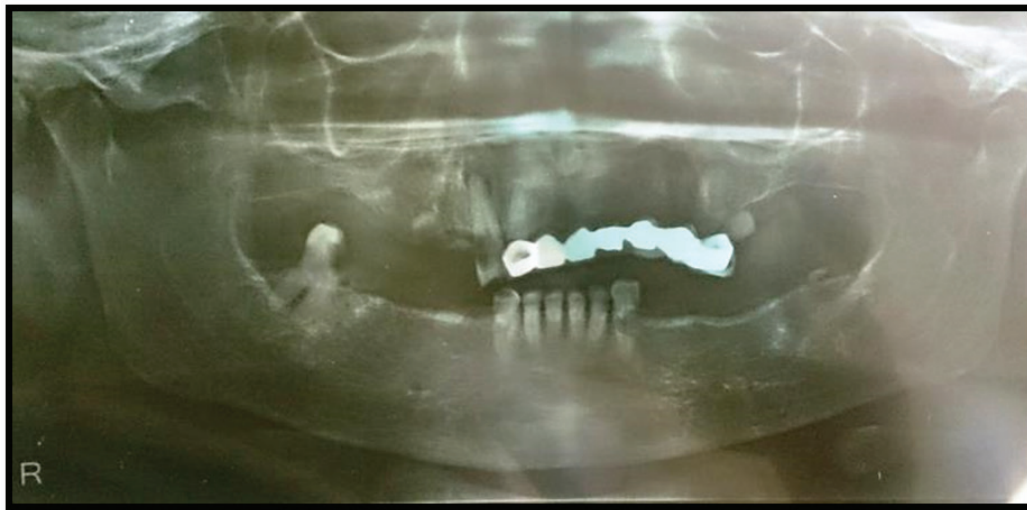


Fig 3: Pre - operative OPG

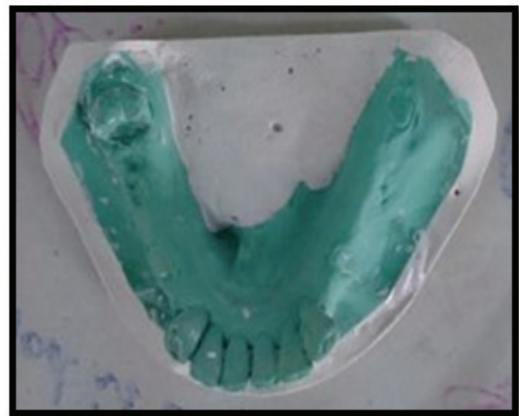


Fig 4 and 5 : Primary maxillary and mandibular cast

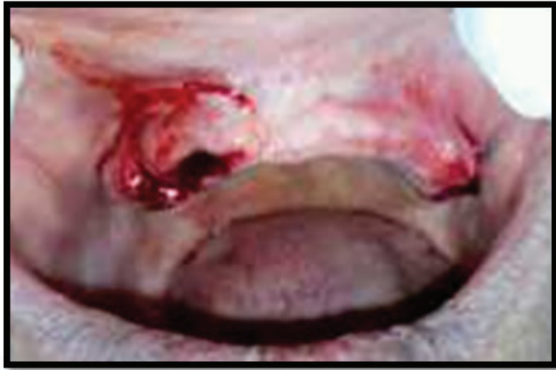

Fig 6: Extraction of maxillary anterior teeth

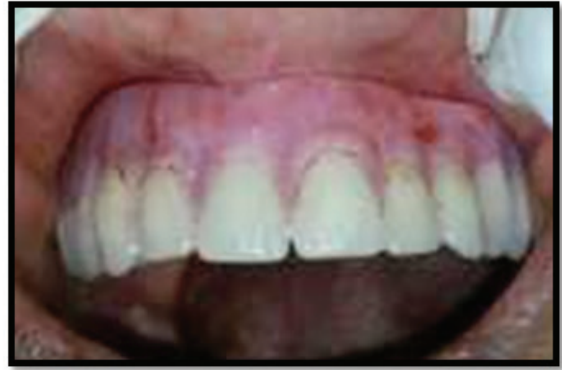

Fig 7: Denture insertion

Fig 8: Post-operative profile view



Ethical Clearance – Not required since it is a case report

Source of Funding – Nil

Conflict of Interest – Nil

Reference

1. Maxillary immediate denture: A case report - Dr. Pardeep Bansal, Dr. Dhanyamol and Dr. Preetikabansal- International Journal of Medical and Health Research, Volume 4; Issue 3; March 2018; Page No. 148-150
2. GLOSSARY OF PROSTHODONTICS- GPT-9
3. Immediate partial denture prosthesis - a case report- Vinaya Bhat & S. Sriram Balaji-NUJHS Vol. 3, No.4, December 2013, ISSN 2249-7110
4. Dental Laboratory Procedures –Complete Denture: Marrow, Rudd, Rhoads, SanjnaNayar- Volume 1, Chapter 16: Page No 321
5. Rehabilitation of Failing Dentition with Interim Immediate Denture Prosthesis - Amit Sharma, DiviaChugh, Bhavika Sachdeva, Manish Sen Kinra- Indian Journal of Dental Sciences, 2016;8:168-71
6. Immediatedenture – an important treatment modality - Kalpana Hasti, Anurag Hasti, Rahul Sharma, Aprajita Mitra- KDJ 2016 | Vol. 39 | No. 1 | Pg 27-29
7. Rehabilitation of a patient with immediate complete denture-Jyoti B Nadgere, SuyogKisanraoMasram, Sabita M Ram, Naisargi P Shah – Journal of Contemporary Dentistry, January – April 2016,6(1);90-95
8. Immediate Denture Service Designed to Preserve the Oral Structures – A Case Report- Dr. Rubina, Dr. Manjit Kumar, Dr. Rashim Garg: et al - International Dental Journal of Student’s Research| Feb 2013-May 2013| Volume 1| Issue 4
9. Immediate complete denture: a contemporary view - Gavazzoni,Alessandro, Rosso Júnior ; et al JRD-Tubarão,/v./3,/n./2,/mar/apr./2015
10. An interim denture technique and case reports - Sheldon Winkler, DDS Robert Wood, DMD Kenneth G. Boberick, : et al- Journal of Oral Implantology, 2005Vol. XXXI/No. Three, 129