

The Diagnostic Efficacy of Visually Enhanced Lesion Scope (VELscope) In Identifying Benign , Dysplastic and Cancerous Oral Lesions

Suroor Ali Jabbar¹, Fawaz Aswad², Ameena Ryhan. Diajil³

¹Post graduate/ Dentist in Department of Oral Diagnosis, College of Dentistry, University of Basrah/Iraq, ²Prof Dr. B.D.S. ,M.Sc., ph.d., MFDS., RCPS. Glasgow in Oral Medicine, Department of Oral Diagnosis, College of Dentistry, University of Baghdad/Iraq, ³B.D.S., M.Sc., Ph.D. Assistant Professor in Oral Medicine, Department of Oral Diagnosis, College of Dentistry, University of Baghdad/Iraq

Abstract

Background : Visual inspection by conventional oral examination (COE) has been the backbone of oral cancer and precancer detection. More recently, several commercially available diagnostic adjuncts have been developed to aid clinicians in the early detection of oral epithelial dysplasia (OED) and squamous cell carcinoma (SCC), such as OralCDx, Toluidine coloring, ViziLite machine, Identafi machine, and VELscope.

VELscope is a technology based on the principles of autofluorescence mechanism imaging. This device offers in-vivo, real-time, direct visualization of tissue autofluorescence, termed direct visual fluorescent examination (DVFE). It is currently marketed as an oral cancer screening tool to be used with all new and recall dental patients and as an aid for surgeons in tumor margin delineation.

Aim of the study : was to obtain auto fluorescent data on variety of histopathologically distinct oral lesions and assessment of direct auto fluorescent examination validity in identifying dysplastic (pre-malignant) and malignant oral mucosal lesions using VELscope and judgment with histopathological examination.

Materials and methods: Routine oral examination of fifty patients having suspicious oral lesions followed by direct autofluorescent examination by VELscope and then histopathological examination.

Conclusion : VELscope can be considered as an adjunctive device to enhance the visualization of oral mucosal abnormalities, but not as a tool for risk stratification.

Key words: *Autofluorescence examination , VELscope , oral premalignant lesions.*

Introduction

Several studies were conducted in many countries interested with the diagnostic value of visually enhanced lesion scope (VELscope) since its development by the British Columbia Cancer Agency and granted FDA clearance on July 06, 2006⁽¹⁾. However no study was conducted in Iraq, so the current study may be considered

the first study concerning with this field.

Biopsy and microscopic evaluation by a trained oral and maxillofacial or head and neck pathologist, remain the clinical gold standard to determine the presence and grade of dysplasia or carcinoma, but over time various diagnostic adjuncts were developed⁽²⁾. Autofluorescence imaging occupies the interest of many researchers and specialists in the field of early detection of oral premalignant and malignant lesions, so several autofluorescence devices have become commercially available since the past decade till nowadays, such as VELscope (LED

Corresponding author:

Suroor Ali Jabbar

surooraj9@gmail.com

Dental, Atlanta, GA), Identafi (StarDental-DentalEZ, Englewood, CO), OralID (Forward Science, Stafford, TX)⁽³⁾ and oralook⁽⁴⁾.

The principle of Velscope work depends on the changes of autofluorescent characteristic of the oral mucosa that contains abundant endogenous autofluorescence molecules called fluorophores which are molecules that emit energy in the form of fluorescence when excited by light, including structural proteins such as collagen and elastin, the metabolic co-factors nicotinamide adenine dinucleotide (NADH) and flavin adenine dinucleotide (FAD), as well as several aromatic amino acids, and porphyrins. This should be done through blue excitation light (wavelength of 400–460 nm) emitted from the VELscope contacts these fluorophores, The level of fluorescence energy emitted from the endogenous autofluorescence substances will become lower than that of the light energy emitted from the VELscope, and green light with a wavelength of 515 nm is then emitted from endogenous autofluorescence substances in healthy area⁽⁵⁾.

Dysplasia and cancer causing measureable changes in tissue autofluorescence in which the collagen cross-links and basal lamina of tissue affected by SCC and epithelial dysplasia are destroyed, and glucose is highly consumed in malignant tissue even when in an aerobic environment (Warburg effect). Also, certain changes, such as increased metabolism, nuclear pleomorphism, increased epithelial thickness, breakdown of collagen cross-links, increased vascularization and production of fluorophores by bacteria may also contribute to this effect⁽⁶⁾.

Epithelial fluorophores concentration decrease in the epithelial dysplasia therefore, the lower level of endogenous auto fluorescence substances in tissue affected by epithelial dysplasia and SCC of the oral mucosa, which has no fluorescence energy, resulting in the appearance of a black area detected as fluorescence visualization loss (FVL)⁽⁷⁾. So in order to perform simple criteria analysis and evaluation of the tissue status, the sample interpreted correctly by Velscope and further analyzed by histopathological examination.

The advantages of auto fluorescence examination using VELscope include obtaining of diagnostic information in situ, real time, and in a minimally invasive

manner⁽⁸⁾. High sensitivity for dysplasia and cancer, ability for assessment of large areas of oral mucosa, consumables are not required, clinical utility for risk assessment during longitudinal monitoring of patients with known high-risk potentially premalignant oral lesions or previous history of cancer and commercially available device rely on subjective interpretation of autofluorescence⁽⁶⁾.

But, Velscope is unfortunately limited by false positive results (low specificity) because lesions of various etiologies have different autofluorescent properties⁽⁹⁾.

Subjects, Materials and Methods

This cross sectional study was conducted from the 1st of February till the 1st of August 2019 in Oral Medicine Department at the College of Dentistry University of Baghdad.

Ethical approval and official permission was obtained from college of dentistry / university of Baghdad Scientific Committee.

Participation consent form for each subject was signed after brief details about the study, having the right of withdrawing from the study at any time.

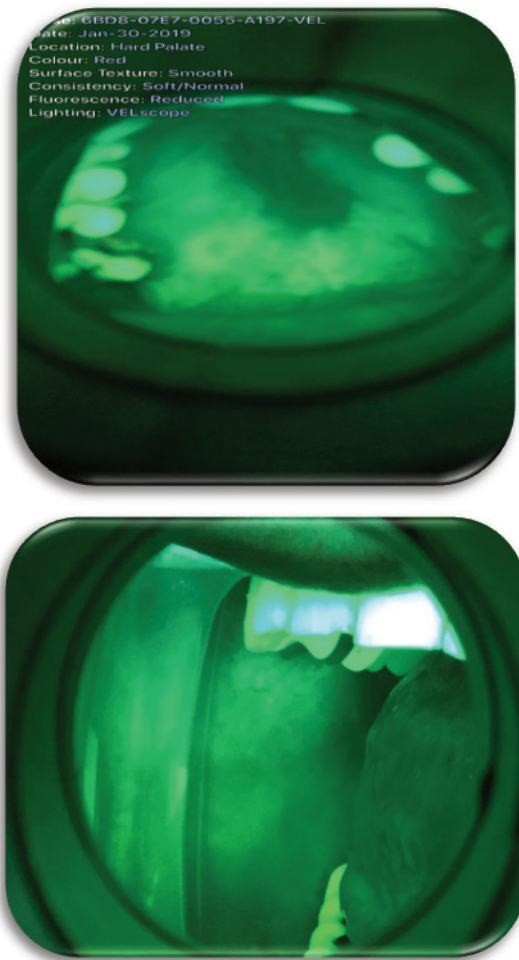
The current study involves 50 patients with an age ranged between 18-75 years with suspicious oral lesions. A case sheets were used to record the personal information including age, sex, occupation, address, phone number and age of onset and duration of the oral lesions. Medical history, family history and history of smoking and alcohol consumption were also recorded.

Excluded patients were those who have contraindications for biopsy sampling, such as bleeding disorders or uncontrolled systemic diseases, diabetic patient, pregnant woman, patients with a confirmed diagnosis of dysplasia or malignancy in a previous biopsy, or patient with history of photosensitivity or those using photosensitive medication who should not be exposed to the light emitted from the VELscope device were also excluded from the study.

All patients were examined by oral medicine specialist at oral diagnosis department for exploring the existence of the oral lesions which was done in sequence examination procedure of oral soft tissue following

directions represented by WHO (1987).

Direct visual examination is then performed by VELscope Lesional and perilesional tissue was assessed for visual fluorescence retention (VFR) and visual fluorescence loss (VFL) when viewed through the velscopeVX handpiece, As documented by the manufacture information ,(LED Dental Inc ,Vancouver ,Canada ,2007).figure (1)



Figurer (1) A:VELscope examination of hard palate demonstrating an area of VFL B: VELscope examination of buccal mucosa demonstrating an area of VFR

Direct visual examination findings were documented and digital photographs of tissue fluorescence were acquired. Images were obtained directly through the VELscope viewing handpiece using Ipod 5 digital camera connected to VELscope by image adapter that is based on the manufacturer (LED DENTAL Inc).

Biopsies were then taken from the suspicious area of the oral lesions,Specimens were stored in 10% neutral buffered formalin and sent to at oral pathology laboratory of the oral diagnosis department at the collage of dentistry /university of Baghdad and Al Byan private specialized medical laboratory.

To determine the sensitivity and specificity of the VELscope, attempts were made to have the biopsy site cover both the COE and VEL positive regions.

Following the biopsy, the tissue sample was fixed in 10% formalin and sent to The Oral Pathology Laboratory for processing and histologic diagnosis, without information of the DVFE findings.

Formalin-fixed and paraffin embedded tissue was processed and stained following standard protocol for routine (hematoxylin and eosin) histopathologic evaluation. The examination were done under a light microscope by an experienced specialist in oral and maxillofacial pathology ,and epithelial dysplasia classified according to its severity (mild ,moderate ,sever).

Final histopathologic diagnoses were recorded on data collection sheets.

To calculate the sensitivity, specificity, positive predictive values (PPV), and negative predictive values (NPV), the results of both the COE and VELscope were compared with the histopathological results.Statistical analysis evaluation was performed using SPSS software.

Results

Results shows that female patients were formed 27(54.0%) with no significant different compared with male numbers 23(46.0%)at $P>0.05$.Age groups of the examined patients seems to be having an extreme shape distribution of type I (smallest values of left skewness),with mean and standard deviation values 53.90 yrs,and 10.44 yrs., as well as recorded highly significant different at $P<0.01$.

Table (1) shows distribution of risk factors in the studied group, such that: (Smoking status and Alcoholic)

Table(1):Risk Factors distribution with comparison's significant

Risk Factors	Groups	Patients		C.S.
		No.	%	
Smoking	No	36	72	P=0.003 HS
	Yes	14	28	
	Total	50	100	
Alcoholic	No	45	90	P=0.000 HS
	Yes	5	10	
	Total	50	100	

The clinical appearance of the oral lesions on the conventional oral examination demonstrated in table (2)

Table(2): Appearance of oral mucosal lesions with comparisons significant

Appearance	Resp.	No.	%	C.S. (*)
White Lesion	No	25	50	P=1.000 NS
	Yes	25	50	
Red Lesion	No	38	76	P=0.000 HS
	Yes	12	24	
Ulcer	No	43	86	P=0.000 HS
	Yes	7	14	
Exophytic Lesion	No	43	86	P=0.000 HS
	Yes	7	14	
Swelling	No	47	94	P=0.000 HS
	Yes	3	6	

Result shows that most of the oral lesions presented as a white Lesion, and they are accounted 25(50.0%), with no significant different at $P>0.05$, then followed by "Red Lesion", and they are accounted 12(24.0%), with significant different at $P<0.01$, then followed by "ulcer, and exophytic Lesion" and they are accounted for each 7(14.0%), with significant different at $P<0.01$, and finally only 3(6.0%) cases are recorded "Swelling" appearance,

with significant different at $P<0.01$ Autofluorescence examination by VELscope was performed on all the 50 patients.

After histopathological examination result shows most patient's diagnosed were having benign oral lesions, and they are accounted 37(74%), table(3)

Table (3) histopathological diagnosis of benign lesions

Definite Diagnosis	No.	%	C.S. (*)
Lichen Planus	32	64	P=0.066 NS
	17	36	
Hyperkeratosis	44	88	P=0.000 HS
	6	12	
Chronic Inflammation	47	94	P=0.034 HS
	3	6	
Nonspecific ulceration	47	94	P=0.000 HS
	3	6	
Fibrolipoma	49	98	P=0.000 HS
	1	2	
Hyperplasic Epithelium	47	94	P=0.000 HS
	3	6	
Fibroma	49	98	P=0.000 HS
	1	2	
Papilloma	48	96	P=0.000 HS
	2	4	
Mucocele	49	98	P=0.000 HS
	1	2	

dysplastic lesion accounted 7 (14 %) and classified as mild dysplasia 5 cases ,moderate dysplasia 1 case ,sever dysplasia 1 case and SCC accounted 6 (12%) cases ,table 6 demonstrated the distribution of histopatholigical diagnosis of dysplasia and SCC.

Table(4)Histopathological distribution of dysplastic and SCC lesions

Diagnosis	Resp.	No.	%	C.S. (*)
Mild Dysplasia	Absent	45	90	P=0.000 HS
	Present	5	10	
Moderate Dysplasia	Absent	49	98	P=0.000 HS
	Present	1	2	
Sever Dysplasia	Absent	49	98	P=0.000 HS
	Present	1	2	
SCC	Absent	44	88	P=0.000 HS
	Present	6	12	

Autofluorescence examination of 37(74%) benign lesions by VELscope show that 24(65%) show VFR to be reported as true negative cases ,and 13(35%) lesions show VFL which is a false positive cases .

Dysplastic lesions examination show that 6(86%) lesion exhibit VFL which are true positive cases and 1(14%) exhibit VFR which is false negative case,

sequamous cell carcinoma show 4(67%) true positive cases that axhibit VFL and 2(33%) false negative cases that exhibit VFR.As a result the autofluorescence examination by VELscope in this study show a sensitivity and specificity of 76.92% and 64.86% respectively,positive predictive value(PPV) is 43.48 %,And negative predictive value (NPV)88.88 %.Table(5)

Table (5): VELscope Sensitivity,specificity,PPV and NPP

Histopathological diagnosis	VFR-	VFL+	Sens	spec	PPV	NPV
	Benign	24	13	76.92 %	64.86%	43.48
Dysplasia	1	6				
SCC	2	4				

Discussion

Oral cancer continues to be a major disease with significant morbidity and mortality so prevention and early detection are essential to improving health outcomes,thus,various diagnostic adjunct had been developed to improve the early detection capabilities of the potential oral premalignant and malignant lesions .among these adjunct is VELscope (visually enhanced lesion scope) that occupies a remarkable concern among researchers and specialist which is based on tissue autofluorescence characteristics.

To the best of our knowledge the current study considered to be the first one that’s conducting in Iraq in an attempted to expand some of the early investigative prospect in the field of oral diagnosis .

The previous studies in this field reported sensitivities and specificities for the device in specialist practice range from 30% to 100% and 15% to 81% respectively ⁽¹⁰⁾

Amirchaghmaghi et al,(2018)demonstrated a high sensitivity(90%)and low specificity (15%)in their study⁽¹¹⁾

Koch et al.,(2017) reported a higher sensitivity(97%) and specificity of(95.8%) of the VELscope in diagnosing OSCC.⁽¹²⁾ On the other hand,Rana et al.(2012) in their study compared VELscope examination with COE and reported that using the VELscope leads to higher sensitivity (100% vs. 17%), but a lower specificity (74% vs. 97%).⁽¹³⁾

The statistical analysis in the current study revealed the sensitivity value of the VELscope examination to be(76.9 %) that was warranted to the false negative results presentation,because one of 7 epithelial dysplasia cases and 2 of 6 SCC cases showed visual fluorescent retention which considered as false negative finding.

This result was also expressed by McNamara et al.(2018) they found that a number of benign lesions displayed VFL⁽¹⁴⁾.

The involvement of few cases of OPMDs and OSCC in the current study may also contribute to these results .

This is in agreement with results reported by Paderni et al. study,they showed a sensitivity of 75% ⁽¹⁵⁾, and disagreement with a study conducted by Farah

et al 2013 ⁽¹⁶⁾, and Mehrotra et al 2010.⁽¹⁷⁾ whom reported low sensitivity for this device(30% and 50% respectively) .

Specificity of VELscope examination that reported by the present study was 64.86%.The study demonstrated that 13 of 37 benign lesions show VFL that's considered as false positive results. One of the main etiologies may be the inclusion of inflammatory and ulcerative lesions in the current study.This low specificity reflects VELscope weakness in distinguishing high-risk lesions(i.e., lesions with dysplasia and malignancy)from low-risk lesions(i.e., inflammatory and benign lesions without dysplasia) that's because of presentation of loss in fluorescent characteristic during the examination (black to grey color comparing with the adjacent tissues) with some cases of atrophic and erosive lichen planus ,ulcerative lesion, and hyperplastic epithelium .

In inflammatory and erythematous tissues, the destruction of structural molecules is less common; however, two factors contribute in the above mentioned results; an increased hemoglobin concentration due to increased circulation and an increased density of chronic inflammatory cells, such as lymphocytes, that's lead to increased dispersion and absorption of the fluorescence along with a darkening of the lesions.⁽¹⁸⁾

Conclusion

Direct visual fluorescent examination by VELscope has potential as a simple, cost-effective screening, biopsy guidance that act as an intermediate adjunctive tool between routine oral examination and a biopsy for oral premalignant and early malignant lesions and to be especially useful to alleviate both patient and practitioner concerns regarding a clinically oral suspicious lesion.

Ethical Clearance: The Research Ethical Committee at scientific research by ethical approval of both environmental and health and higher education and scientific research ministries in Iraq

Conflict of Interest: The authors declare that they have no conflict of interest.

Funding: Self-funding

References

1. Ayoub HM,Newcomb TL,McCombs GB,Bonnie

2. MJADHA.The use of fluorescence technology versus visual and tactile examination in the detection of oral lesions:a pilot study. 2015;89(1):63-71.
2. Lingen MW,Abt E,Agrawal N,Chaturvedi AK,Cohen E,D'Souza G,et al.Evidence-based clinical practice guideline for the evaluation of potentially malignant disorders in the oral cavity:A report of the American Dental Association. Journal of the American Dental Association (1939).2017;148(10):712-27.e10.
3. Yamamoto N,Kawaguchi K,Fujihara H,Hasebe M,Kishi Y,Yasukawa M,et al. Detection accuracy for epithelial dysplasia using an objective autofluorescence visualization method based on the luminance ratio.International journal of oral science.2017;9(11):e2.
4. Morikawa T,Kosugi A,Shibahara TJA.The Utility of Optical Instrument "ORALOOK®" in the Early Detection of High-risk Oral Mucosal Lesions.2019;39(5):2519-25.
5. Yamamoto N, Kawaguchi K,Fujihara H,Hasebe M,Kishi Y,Yasukawa M, et al.Detection accuracy for epithelial dysplasia using an objective autofluorescence visualization method based on the luminance ratio.2017;9(11):e2
6. Yang EC, Tan MT, Schwarz RA, Richards-Kortum RR, Gillenwater AM, Vigneswaran NJOs, oral medicine, oral pathology, et al. Noninvasive diagnostic adjuncts for the evaluation of potentially premalignant oral epithelial lesions: current limitations and future directions. 2018;125(6):670-81.
7. Palmer S,Litvinova K,Rafailov EU,Nabi G.Detection of urinary bladder cancer cells using redox ratio and double excitation wavelengths autofluorescence.Biomedical optics express.2015;6(3):977-86
8. Al-Jaber A, Al-NasserL,El-MetwallyA. Epidemiology of oral cancer in Arab countries. Saudi Med J.2016;37(3):249-55
9. Lingen MW,Abt E,Agrawal N,Chaturvedi AK,Cohen E,D'SouzaG,et al.Evidence-based clinical practice guideline for the evaluation of potentially malignant disorders in the oral cavity:a report of the American Dental Association. 2017;148(10):712-27.

10. Bhatia N,Matias MAT,Farah CSJOO.Assessment of a decision making protocol to improve the efficacy of VELscope in general dental practice: a prospective evaluation. 2014;50(10):1012-9.
11. Amirchaghmaghi M,Mohtasham N,Delavarian Z,Shakeri MT,Hatami M,Mozafari PMJP,et al. The diagnostic value of the native fluorescence visualization device for early detection of premalignant/malignant lesions of the oral cavity.2018;21:19-27.
12. Ganga RS,Gundre D,Bansal S,Shirsat PM,Prasad P,Desai RSJOO.Evaluation of the diagnostic efficacy and spectrum of autofluorescence of benign,dysplastic and malignant lesions of the oral cavity using VELscope.2017;75:67-74.
13. Rana M,Zapf A,Kuehle M,Gellrich N-C,Eckardt AMJEJoCP.Clinical evaluation of an autofluorescence diagnostic device for oral cancer detection:a prospective randomized diagnostic study.2012;21(5):460-6.
14. Cănjău S,Todea DCM,Sinescu C,Pricop MO,Duma V-FJRJME.Fluorescence influence on screening decisions for oral malignant lesions.2018;59(1):203-9.
15. Paderni C,Compilato D,Carinci F,Nardi G,Rodolico V,Lo Muzio L,et al.Direct visualization of oral-cavity tissue fluorescence as novel aid for early oral cancer diagnosis and potentially malignant disorders monitoring.2011;24(2_suppl):121-8.
16. Farah CS,McIntosh L,Georgiou A,McCullough MJJH,neck.Efficacy of tissue autofluorescence imaging (VELScope) in the visualization of oral mucosal lesions.2012;34(6):856-62.
17. Mehrotra R,Singh M,Thomas S,Nair P,Pandya S,NigamNS,et al. A cross-sectional study evaluating chemiluminescence and autofluorescence in the detection of clinically innocuous precancerous and cancerous oral lesions.2010;141(2):151-6
18. Rashid A,Warnakulasuriya SJJoOP,Medicine. The use of light-based (optical) detection systems as adjuncts in the detection of oral cancer and oral potentially malignant disorders:a systematic review. 2015;44(5):307-28