

The Possible Nephroprotective Effect of Roflumilast Ameliorating Glycerol -Induced Myoglobinuric Acute Renal Injury in Rabbits Model

Mukhallad A. Ramadhan¹; Haider F. Al-Saedi²; Ghufraan L. Ismaeel²; Uday Abdul-Reda Hussein³

¹PhD Pathology, University of Misan/ College of Medicine/ Misan/ Iraq, ²PhD Pharmacology and Toxicology, College of pharmacy–University of Al-Ameed, ³Ph.D. Pharmacology, College of Pharmacy- University of Thi-Qar

Abstract

Glycerol encouraged kidney damage through originating an oxidative injury to renal tubular cells which further leads to tissue necrosis and inflammation. While, roflumilast N-oxide is an active metabolite of roflumilast that rising the cyclic adenosine-3', 5'-monophosphate by inhibiting PDE4.

Thirty rabbits were divided into three groups, control group was received normal saline intra-muscularly and driven from water for eighteen hours before. Second group was received a single dose glycerol injected intra-muscularly after driven from water for eighteen hours. Third group was received roflumilast intraperitoneal daily for three days after received a single dose of glycerol.

All animals were sacrificed after 72 hour, and then blood collected by cardiac puncture for evaluation the changes in the levels of renal function tests and histopathological study of rabbit's kidneys tissues are evaluated evaluation and scoring the changes of tested agents. The numerical data are expressed as means \pm standard error means and analyzed by using SPSS version 20.

The results of the levels serum urea and creatinine found to be significantly reduced by roflumilast using ANOVA test. Besides, the histopathological changes showed ameliorative effects of roflumilast in compared to glycerol group. From this study, one could be concluded the protective effect of roflumilast in case of renal failure induction by glycerol.

Key words: *nephroprotective, roflumilast, glycerol*

Introduction

Acute kidney encompasses smaller changes in the renal function without obvious failure that could be resulted in significant worse consequences and the rate of disease in a population, moreover may be ended to death⁽¹⁾. The incidence rate of these emergent cases that is needed to hospitalization reached to 2-5%. Acute kidney impairment developed within one month postoperatively

in rate 1 of 100 patients of general surgery cases and arises in up to near 70 % of intensive care unit patients⁽²⁾. Nephrotoxicity induced by drug overdose or time dependent is a frequent problem in nephritic-medicine and the incidence of drug-accompanying acute kidney impairment may be as high as sixty percent⁽³⁾. The etiology of pathological condition associated with acute renal failure is septic shock at 47.5 % of total patients that needed hospitalization. The percent of death to total hospital mortality was 60.3%⁽⁴⁾. Other causative condition of acute renal function deterioration is a myoglobinuric case, which is uremic syndrome followed rhabdomyolysis and muscle destruction with releasing of intracellular elements such as myoglobin and other intracellular constituents into blood stream

Haider F. Al-Saedi Corresponding author

PhD Pharmacology and Toxicology

College of pharmacy–University of Al-Ameed

hasaedi@alameed.edu.iq Corresponding author email

Mobile: 009647735244677

(5). The myoglobin casts producing its effects by tubular obstruction or damaging of tubular epithelium with leakage of filtrate across it after reducing glomerular filtration rate (6). Acute nephrotic injury given that an increase in serum creatinine often lags two and three days behind the onset of injury that may reflect the damage might be included two third parts of kidney were included (7). Indication of roflumilast in case of chronic obstructive respiratory disease, it is effective in reducing the frequency of respiratory disease exacerbations(8). The current study aimed to evaluate and investigate the potential nephroprotective effect of roflumilast against nephrotoxicity induced by glycerol in rabbits.

Experimental Design and Method

Rabbits (albino & domestic) of different sexes were weighing (1- 2 Kg) were acclimated for new animal house for ten days before any experimental procedures and fed with commercial pellets and allowed water *ad libitum*. They were reserved under dominated condition of temperature (23 ± 2 °C) and humidness ($55 \pm 15\%$). Also, lighting was systemized lighten to half day then to darken later. All methods performed in this current study were in accordance with regulatory content on the maintenance and practice of lab animals and reported to ethical committee approval of college of pharmacy. In the present study, after 72 hour of water deprivation, three groups of rabbits (n = 10 for each group involved control group was received intraperitoneal (5 ml) of normal saline (0.9 % of sodium chloride); group 2 (induction group) was only received given dose of diluted glycerol (50 %; 8 ml/ kg, i.m.), the total dose was divided equally, then administered in each hind limb muscle (18). Group 3 was given glycerol intramuscularly as single dose plus roflumilast that was given intraperitoneal after 60 minutes of the glycerol injections(1 mg/kg)⁽⁹⁾. Blood samples are collected by cardiac puncture to prepare serum, and then kidneys tissues were harvested for further biochemical and histopathologic analyses.

Measurement of serum urea concentration involved the usage of a commercially available kit (Biosystems)^R (10). The urea levels in the samples react with the kit's reagent components (11). Measurement of serum creatinine concentrations were done by using a commercially available kit was used (Biosystems)^R. The auto- analyzer apparatus is used to measure the

absorbance of standard and samples after 30 and 90 second based on spectrophotometric measurement at 505nm^(12, 13).

Histopathological assessment involved the macroscopic examination of the kidneys, then microscopic evaluation (14) (15). A pathologist, who was unaware of the group assignments, performed a semiquantitative analysis of the kidney sections using a light microscope⁽¹⁶⁾. The statistical analyses were performed by using statistical package of social science (SPSS version 20). All numerical data are expressed as mean \pm standard error of the mean (SEM). The data were evaluated by one-way analysis of variance (17) and Mann Whitney U test. *P* value is considered significant when its value equal or less than 0.05⁽¹⁸⁾.

Findings

Induction was done by glycerol-received group and it showed a significant elevation of urea level compared to control group. While, treatment group (roflumilast-treated group) displayed a significance reduction of urea level in comparison with induction group (shown in table 1). In addition, induction group exhibited there is significance elevations of serum creatinine level compared to control one. While the treatment group (roflumilast treated group) offered a significance reduction of creatinine level in comparison with induction group as shown in table (1).

Sections of kidneys of control group revealed normal appearance of renal tubules in both cortex and medulla (figure1). Glycerol treated group showed area of interstitial inflammation and others changes discussed in scoring system (figure 2, table 2). While, roflumilast treated group showed as clearly improvement of histopathological changes (figure 3). Kidneys in the induction group showed moderate to severe lesions. Lesions were included deposition of hyaline material in the tubules of cortex and medulla, marked dilation of renal tubules, vacuolization of the renal tubular epithelium particularly in the medullary region, this group showed marked epithelial vacuolation to obtained score 4 in statistical significant level of $P \leq 0.01$ than control group (displayed in table 2). Some of the epithelial cells revealed statistically significant level of necrosis ($P \leq 0.05$) than both G1 and G3, this change was indicated by fragmentation of cell membrane and absence of

nuclear staining to get score 2 as showed in table 2. Some apoptotic cells were also observed indicated by fragmentation of nuclei with intact cell membrane to give score 1 but it was statistically non-significant ($P \geq 0.05$) in comparison with both G1 and G3 (table 2). Marked (score 2) interstitial lymphocytic infiltration was noted in this group, it was significant in comparison with G1 and

G3 (table 2) but no significant glomerular changes had been detected in the level of light microscopic inspection (table 2). Complete absence of hyaline casts in the renal tubules, no necrosis and apoptosis in the renal tubular cells ((figures 3), (tables 2)). As G1 and G2, there were no obvious glomerular changes at the level of light microscope illustrated table2.

Table (1) Effect of roflumilast on level of serum creatinine against glycerol- induced acute renal failure

Group	Urea level (mg16)	Serum creatinine
Control	43.58	0.79
Glycerol	61.43*	1.25*
Roflumilast	31.80*#	1 *#

* means $p \leq 0.05$ when compared to control group; # means $p \leq 0.05$ when compared to glycerol (induction) group

Table (2) represent the scores of interstitial inflammation, evacuation, necrosis, apoptosis and epithelial cell glomerular injury in the groups of study

S	Group	Score of interstitial inflammation	Score of epithelial cell vacuolation	Score of epithelial cell necrosis
1	G1	00 ± 00 A score 0	00 ± 00 A score 0	00 ± 00 A score 0
2	G2	40% ± 0.32 B score 2	84% ± 0.2 B score 4	25% ± 0.14 B score 2
3	G3	10 % ± 0.11 A score 1	37% ± 00 C score 3	00 ± 00 A score 0
P Value		$P \leq 0.01$	$P \leq 0.01$	$P \leq 0.05$
S	Group	Score of epithelial cell apoptosis	Score of epithelial cell glomerular injury	
1	G1	00 ± 00 A score 0	00 ± 00 score 0	
2	G2	13 % ± 00 B score 1	00 ± 00 score 0	
3	G3	00 ± 00 A score 0	00 ± 00 score 0	
P Value		$P \leq 0.05$	$P \geq 0.05$	

- These notes applied for all tables
- Values were expressed as a mean ± standard error.
- P values ≤ 0.01 was considered as significant.
- different capital letters refer to the significance among the groups.

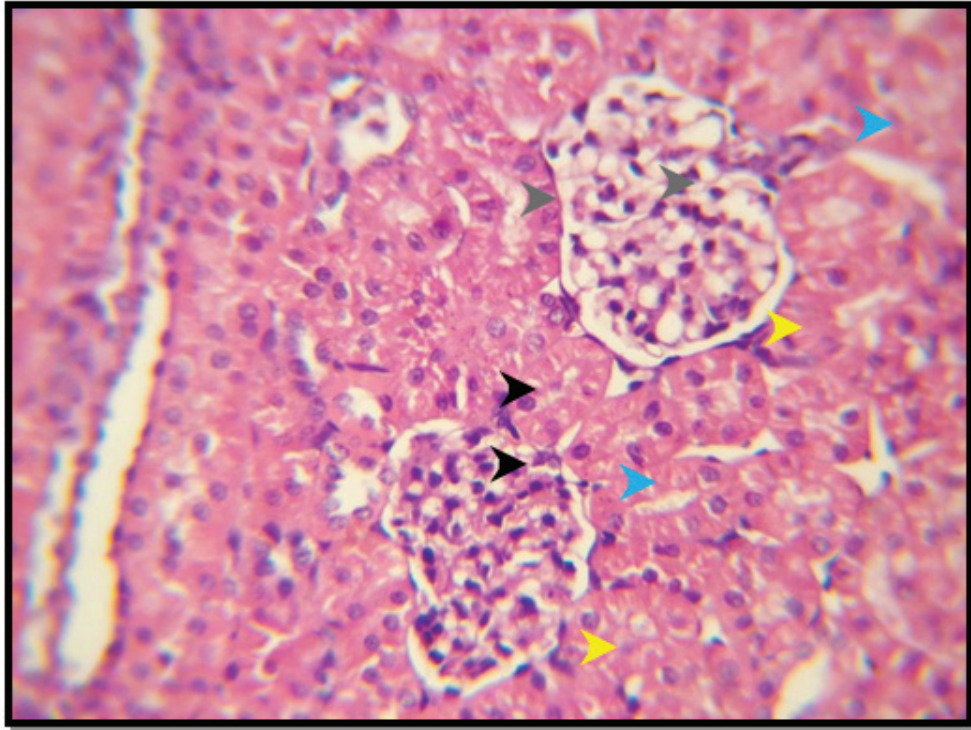


Figure (1) Kidney of control group shows normal proximal renal tubules (white arrow head), distal tubules (black arrow head), glomerular tuft (blue arrow head) and bowman's space (yellow arrow head) in the renal cortex (3) H&E 500X

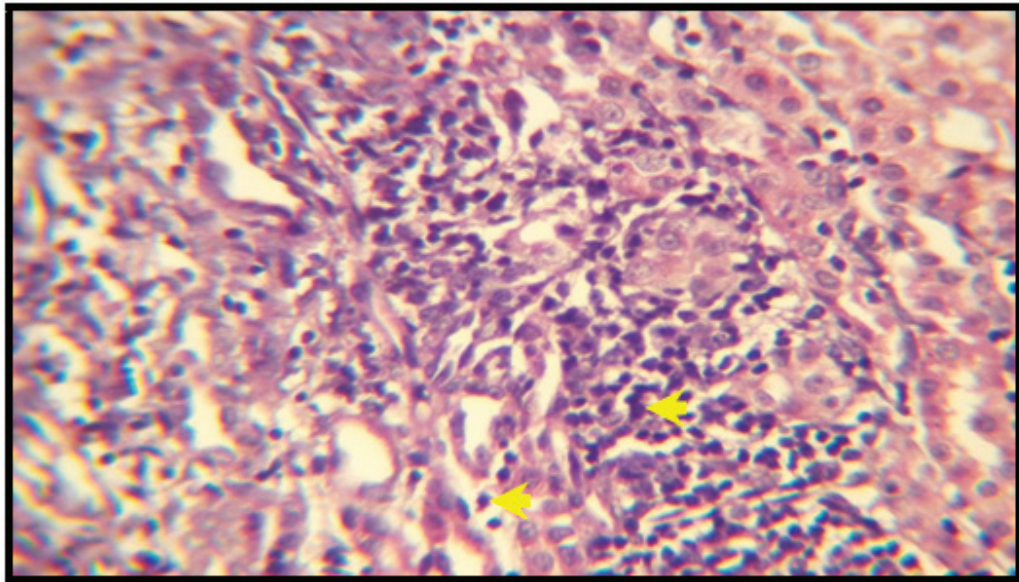


Figure (2) Kidney of Glycerol treated group shows area of interstitial inflammation (yellow arrow head) H&E 500X

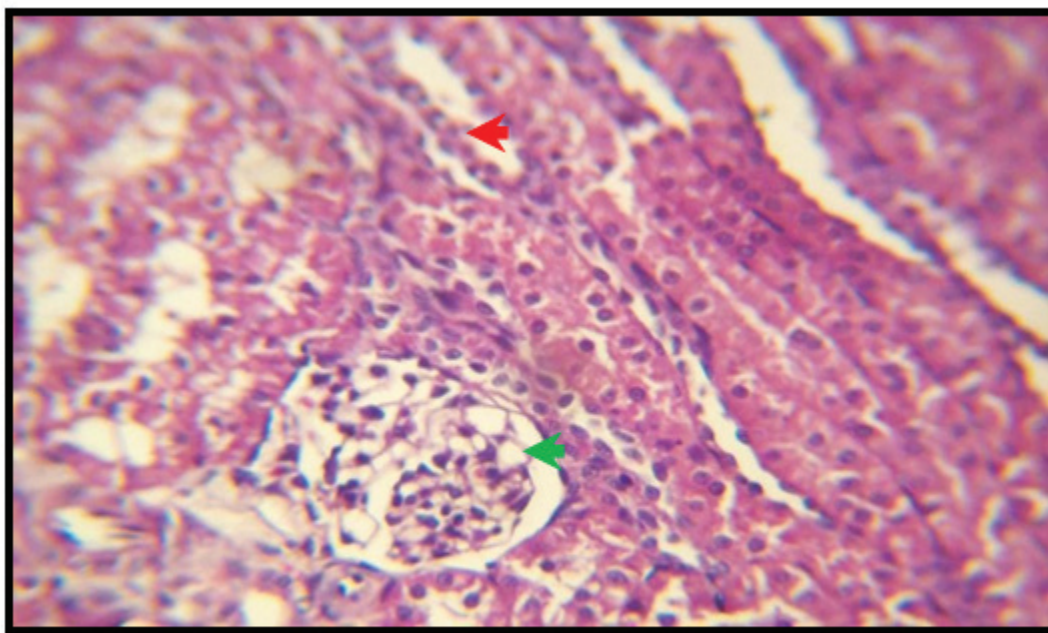


Figure (3) Kidney of glycerol + roflumilast treated group shows normal renal tubules (red arrow head) with normal glomerulus (green arrow head) in the cortex H&E 500X

Discussion

Glycerol-induced kidney impairment is cardinal of the most remarkably used model of experimental rhabdomyolysis inducing renal failure and is reflected as an experimental similarity of human myoglobinuric renal failure that resulted from transfusion problems or crush injury or random traffic accident⁽¹⁹⁾.

Myoglobin-induced tubular damage; or by renal actions of cytokines released⁽²⁰⁾. Glycerol mediated nephrotoxicity by different mechanisms including a uncorrected renal ischemia of renal blood vessels, whereby blood flow ceases or arterial or arteriolar constriction⁽²¹⁾. This may be interpreted to increment of high proteins level in the blood leading to elevation of osmotic pressure and reduction of hydrostatic pressure, then both of them leading to reduced glomerular filtration pressure and reduced filtration process through glomerulus to Bowman's capsule, leading to elevation levels of both serum urea and serum creatinine⁽²²⁾. The reduction of blood flow leading to persistence ischemia and free radical formation ended with glomerulopathy terminated with allow high molecular weight molecules such as protein to penetrate into tubules and elevate

intratubular pressure that may equilibrate with oncotic pressure and diminished the glomerular filtration rate. In contrast, when intratubular oncotic pressure increased leading to loss of diffusion process so loss of kidney filtration function⁽¹⁷⁾. Glycerol treated group showed epithelial cells vacuolation and apoptotic cells besides the deposition of hyaline casts in the renal tubule⁽²⁰⁾. Roflumilast is mainly effective through selective PDE 4 inhibitors, pleotropic effects including anti-inflammatory, anti-emphysema, and antibiotic⁽²³⁾. Also, the beneficial effects were including pulmonary hypertension and hypersecretion of mucus⁽²⁴⁾. The pharmacological actions behind nephroprotective effects attributed to inhibition of reactive molecules formation epithelial cells besides inhibition of neutrophils recruitment. Furthermore, it modulate vascular remodeling due to endothelial cells and probably some inflammatory cells⁽²⁵⁾. Roflumilast is the one of drugs that could be item for further researches for improving these beneficial effects through improving effects on levels of kidney function biomarkers and ameliorating histopathological change⁽²⁶⁾. Inhibition of glomerular vasoconstriction one of the other two mechanisms participating in the development of acute renal failure

is the decrease in blood flow in the glomerulus⁽²⁷⁾. The roflumilast advantageous role of specific diesterase inhibition may be through blocking signaling pathways of inflammation and refreshing cell survival⁽²⁸⁾. These results informed the advantageous role of PDE4 suppression in treating of nephrotoxicity, possibly through histopathological changes amelioration⁽²⁸⁾. Also, The vasodilator effect may be considerable effect for roflumilast shared with another drug of PDEs inhibitor on reversing nephrotoxicity⁽²⁹⁾.

Conclusion

Roflumilast had a therapeutic effect against glycerol induced renal failure and ameliorating the renal impairment by rendering the level of urea, creatinine and histopathological tissue features.

Acknowledgments: to Department of Pharmacology in College of Pharmacy / University of Al-Ameed.

Fund: Independent researchers by authors themselves.

References

- Horino T. Acute Kidney Injury: Definition and Epidemiology. *Acute Kidney Injury and Regenerative Medicine*: Springer; 2020. p. 3-20.
- Rewa O, Bagshaw SM. Acute kidney injury—epidemiology, outcomes and economics. *Nature reviews nephrology*. 2014;10(4):193.
- Anwar M, Muhammad F, Akhtar B, Ur Rehman S, Saleemi MK. Nephroprotective effects of curcumin loaded chitosan nanoparticles in cypermethrin induced renal toxicity in rabbits. *Environmental Science and Pollution Research*. 2020:1-9.
- Deep A, Saxena R, Jose B. Acute kidney injury in children with chronic liver disease. *Pediatric Nephrology*. 2019;34(1):45-59.
- Yuan S-M. Acute kidney injury after pediatric cardiac surgery. *Pediatrics & Neonatology*. 2019;60(1):3-11.
- AlBasher G, Alfarraj S, Alarifi S, Alkhtani S, Almeer R, Alsultan N, et al. Nephroprotective role of selenium nanoparticles against glycerol-induced acute kidney injury in rats. *Biological Trace Element Research*. 2020;194(2):444-54.
- Navarro I, Khanna S. Ambrisentan for use in the treatment of acute renal failure. Google Patents; 2019.
- Rhee CK, Kim DK. Role of phosphodiesterase-4 inhibitors in chronic obstructive pulmonary disease. *The Korean Journal of Internal Medicine*. 2020;35(2):276.
- Martorana PA, Beume R, Lucattelli M, Wollin L, Lungarella G. Roflumilast fully prevents emphysema in mice chronically exposed to cigarette smoke. *American journal of respiratory and critical care medicine*. 2005;172(7):848-53.
- Al-Notazy MR, Al-Rubye MA, Aal-Aaboda MS, Al-Saedi HF, Qasim BJ. The possible protective effect of trimetazidine on imiquimod-induced psoriasis like skin inflammation in an animal model. *International Journal of Research in Pharmaceutical Sciences*. 2019;10(1):70-6.
- Mousleh R, Al Laham S, Al-Manadili A. The preventive role of pioglitazone in glycerol-induced acute kidney injury in rats during two different treatment periods. *Iranian journal of medical sciences*. 2018;43(2):184.
- Grotto D, Bueno DCR, de Almeida Ramos GK, da Costa SR, Spim SRV, Gerenutti M. Assessment of the safety of the shiitake culinary-medicinal mushroom, *lentinus edodes* (agaricomycetes), in rats: Biochemical, hematological, and antioxidative parameters. *International journal of medicinal mushrooms*. 2016;18(10).
- Priyadarshini KA, Rao GS, Kumar GS, Raju D. ANTIHYPERLIPIDEMIC ACTIVITY OF RUELIA TUBEROSA ROOT EXTRACT.
- Dahl S. Databank on Phytochemistry and Phytotherapy. *Research & Reviews: A Journal of Bioinformatics*. 2020;7(1):31-51.
- Egeberg A, Andersen YM, Halling-Overgaard AS, Alignahi F, Thyssen JP, Burge R, et al. Systematic review on rapidity of onset of action for interleukin-17 and interleukin-23 inhibitors for psoriasis. *Journal of the European Academy of Dermatology and Venereology*. 2020;34(1):39-46.
- Kunert-Keil C, Richter H, Zeidler-Rentzsch I, Bleeker I, Gredes T. Histological comparison between laser microtome sections and ground specimens of implant-containing tissues. *Annals of Anatomy-Anatomischer Anzeiger*. 2019;222:153-7.
- Sukhomlinova I, Tichonovskay M, Kirsanova E, Yeryomina A. The physiology of the kidney and

- body fluids. 2016.
18. Lee KJ, Moreno-Betancur M, Kasza J, Marschner IC, Barnett AG, Carlin JB. Biostatistics: a fundamental discipline at the core of modern health data science. *The Medical Journal of Australia*. 2019;211(10):444.
 19. Van Avondt K, Nur E, Zeerleder S. Mechanisms of haemolysis-induced kidney injury. *Nature Reviews Nephrology*. 2019;1-22.
 20. Abd-Ellatif RN, Hegab II, Atef MM, Sadek MT, Hafez YM. Diacerein protects against glycerol-induced acute kidney injury: modulating oxidative stress, inflammation, apoptosis and necroptosis. *Chemico-biological interactions*. 2019;306:47-53.
 21. Al Asmari AK, Al Sadoon KT, Obaid AA, Yesunayagam D, Tariq M. Protective effect of quinacrine against glycerol-induced acute kidney injury in rats. *BMC nephrology*. 2017;18(1):41.
 22. Polzin DJ, Cowgill LD. Management of glomerulopathies. *BSAVA Manual of Canine and Feline Nephrology and Urology: BSAVA Library*; 2017. p. 278-90.
 23. Cortijo JG, Morcillo ES. Pharmacological profile of roflumilast. *Archivos de bronconeumologia*. 2010;46:19-24.
 24. Martin C, Frija-Masson J, Burgel P-R. Targeting mucus hypersecretion: new therapeutic opportunities for COPD? *Drugs*. 2014;74(10):1073-89.
 25. Konrad F, Bury A, Schick M, Ngamsri K, Vollmer I, Reutershan J. 0997. The unrecognized effects of phosphodiesterase 4 on epithelial cells in pulmonary inflammation. *Intensive care medicine experimental*. 2014;2(S1):P82.
 26. Ansari MN, Ganaie MA, Rehman NU, Alharthy KM, Khan TH, Imam F, et al. Protective role of Roflumilast against cadmium-induced cardiotoxicity through inhibition of oxidative stress and NF- κ B signaling in rats. *Saudi Pharmaceutical Journal*. 2019;27(5):673-81.
 27. Heyman SN, Khamaisi M, Zorbavel D, Rosen S, Abassi Z, editors. *Role of Hypoxia in Renal Failure Caused by Nephrotoxins and Hypertonic Solutions*. *Seminars in Nephrology*; 2019: Elsevier.
 28. Xu M, Yu X, Meng X, Huang S, Zhang Y, Zhang A, et al. Inhibition of PDE4/PDE4B improves renal function and ameliorates inflammation in cisplatin-induced acute kidney injury. *American Journal of Physiology-Renal Physiology*. 2020;318(3):F576-F88.
 29. Al-Saedi H, Al-Zubaidy A, Khattab Y, Sahib H. Effect of pentoxifylline against doxorubicin-induced nephrotoxicity in rabbits. *International Journal of Pharmaceutical Sciences Review and Research*. 2015;30(1):195-9.