

Survey on Management of White Spot Lesions

N.E.Kaviya¹, S.Haripriya², Anitha Roy³

Research Associate, Dental Research Cell, ²Senior Lecturer, Department of Conservative Dentistry and Endodontics, ³Associate Professor, Department of Pharmacology, Saveetha Dental College, Saveetha Institute of Medical and Technical Sciences, Saveetha University, Chennai, Tamil Nadu, India

Abstract

White spot lesion occurs due to the demineralization of enamel. The white spot lesion is also caused by hypomineralization, fluorosis etc. It can be identified by visual as well as radiographic methods. The white spot lesion can mainly be prevented by maintaining proper oral hygiene. Other methods of management of white spot lesions include fluoride therapy, calcium phosphate, resin infiltration and CPP-ACP. The usage of remineralizing agents also helps in preventing and treating white spot lesions. This survey was conducted with a questionnaire about the management of white spot lesion and was circulated among 100 specialists and general practitioners. Data collection was done and analysed. The graphs were plotted according to the responses obtained from the survey. The results of the survey showed that the participants preferred the proper maintenance of the oral hygiene to prevent the white spot lesion. In case of no proper oral hygiene the participants preferred the usage of different techniques available to revert demineralisation. There was no significant association between the field of practice (specialist /general practitioners) and their response to the question. The participants had a good knowledge regarding the management of the white spot lesion and most of them were aware regarding the different modalities of treatment available and implied them in their clinical practice.

Keywords: *White opacity; hypomineralization; fluoride; CPP - ACP; Resin infiltration*

Introduction

White spot lesion is the demineralization or decalcification of enamel ¹. The initial lesion formation in caries is called as white spot lesion ². It can also occur due to hypomineralization, hypoplasia and fluorosis. The risk of white spot lesion is due to improper oral hygiene maintenance, acid producing bacteria, low salivary volume flow rate and fermented carbohydrates ³. It is also called as white opacity because of its white opaque appearance during the scattering of light and appears as

decalcified structures where the calcified structures are demineralized ^{4 5}. The common site for white spot lesion is the labiogingival surface of the lateral incisors and the least common site of white spot lesion is maxillary posterior segments ⁶. The development of the white spot lesion requires the coexistence of four factors namely fermentable carbohydrates, bacterial plaque, susceptible tooth surface and period for the development of white spot lesion ⁷.

Diagnosis of white spot lesion is done using visual inspection and radiography, transillumination methods, ultrasonic methods, electrical conductivity, polarization-sensitive test, optical coherence tomography including new technological methods for diagnosis of white spot lesion ⁸. The most commonly used method in the diagnosis of white spot lesion is visual identification and radiography method. The differential diagnosis factor included is hypomineralization that is caused by fluorosis ¹, molar-incisor hypomineralization ^{9 10} and traumatic hypomineralization.¹¹

Corresponding Author:

S. Haripriya,

Senior Lecturer, Department of Conservative Dentistry and Endodontics, Saveetha Dental College, Saveetha Institute of Medical and Technical Sciences, Saveetha University, Chennai 600 077, Tamil Nadu, India. Email: haripriyas.sdc@saveetha.com
Contact number: 9677139139

The management of white spot lesion is by remineralization of demineralized enamel¹². Fluoride application in the form of toothpaste, mouthwash, varnishes, gels and foam can promote remineralisation. The fluoro apatite formed is seen to be more durable than the hydroxyapatite^{13 14}. Other management techniques include the usage of calcium phosphate, sealants, vital tooth bleaching, microabrasion and resin infiltration¹¹. Chlorexidine also reduces the white spot lesion^{15 16 17}. Tooth bleaching agents are minimally invasive and provide a uniform appearance¹⁸. Administration of phosphoric acid reduces the white spot lesion. Microabrasion treatment can improve the enamel surface texture and remineralize enamel. In resin infiltration method the diffusion pathway of dissolved minerals and acids causes obstruction of pores. The resin infiltration produces good strength and they prevent the cavitation of the tooth. The masking also showed good colour stability¹⁹. The usage of natural products like milk help the recovery of white spot lesions. Bioactive composites are also used in the treatment of white spot lesions^{20 21 21,22}. White spot lesions can also be managed using the laminates and veneers^{23 24} Grape seed has remineralization capacity hence it can be used

in the treatment of white spot lesion^{25 26}.

The previous studies conducted by our team in the field of conservative dentistry and endodontics²⁷⁻³⁴ paved the way to carry on with this research. This survey was performed to analyse the knowledge, attitude and practice regarding the management of white spot lesions among the general practitioners.

MATERIALS AND METHODS

A survey questionnaire was prepared and circulated among the specialists and general practitioners to analyze and evaluate the techniques used in the management of the white spot lesion. This survey was conducted through an online portal, questionnaires (Table:1) were prepared using google forms and circulated among 100 participants comprising of 63 specialists and 37 general dental practitioners randomly using social media; it took about 5-10 minutes to complete the survey. Responses obtained from the survey were tabulated in an excel sheet and analysed using SPSS software. The charts were plotted and the results were compared with responses obtained from the participated specialists and general dental practitioners.

The table below shows the questionnaire prepared and circulated among the respondents,

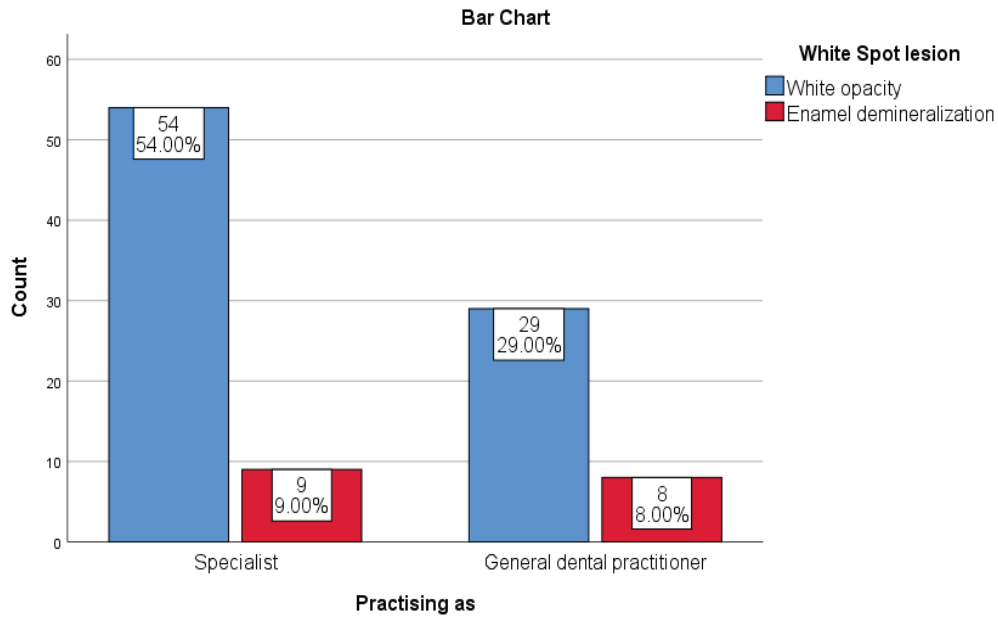
Questions	Options
What is white spot lesion?	<ul style="list-style-type: none"> • White opacity • Enamel demineralization • Decalcification • Others
How to identify white spot lesions?	<ul style="list-style-type: none"> • Visual observation • Radiography • Others
How many cases of white spot lesions will you encounter in your practice per month?	(Numbers to be mentioned)
Can we get rid of white spot lesions?	<ul style="list-style-type: none"> • Yes • No
Is white spot lesion reversible?	<ul style="list-style-type: none"> • Yes • No
Can white spot lesion be managed by using 35-37% of phosphoric acid gel?	<ul style="list-style-type: none"> • Yes • No • Not sure

Cont... Table 1 Questionnaires included in survey

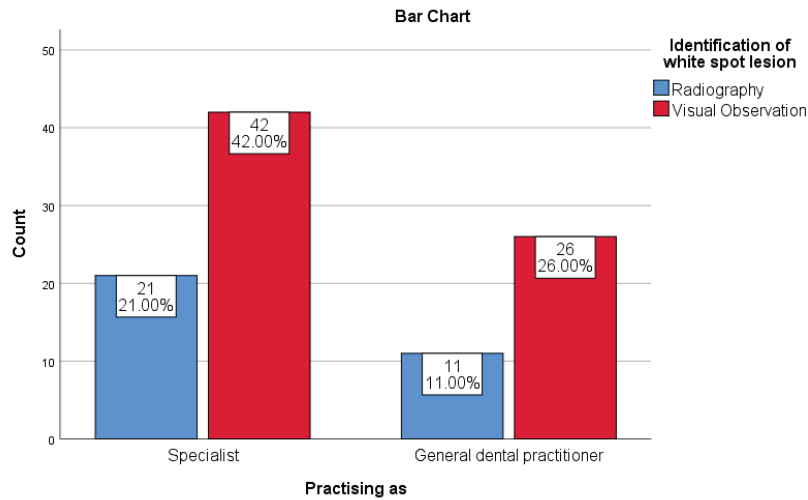
Can white spot lesion be treated by using fluoride?	<ul style="list-style-type: none"> • Yes • No • Sometimes
Is enamel microabrasion useful in the removal of white spot lesion?	<ul style="list-style-type: none"> • Yes • No
Which one do you prefer in the treatment of white spot lesions?	<ul style="list-style-type: none"> • 35-37% phosphoric acid • Fluoride • Remineralization with fluoride, calcium and phosphate. • All the above
Can white spot lesion be treated at home?	<ul style="list-style-type: none"> • Yes • No
If so how can it be treated at home?	<ul style="list-style-type: none"> • Oral hygiene • Fluoride mouthrinse • Fluoride based toothpaste • Remineralising paste (CPP-ACP) • Any other
What can we do to prevent the white spot lesion?	<ul style="list-style-type: none"> • Oral hygiene maintenance • Agents with fluorides • Antimicrobial agents • Other
Among the classes of white spot lesion which is easily curable?	<ul style="list-style-type: none"> • Class 1 • Class 2 • Class 3 • Class 4
Does white spot lesion form cavities?	<ul style="list-style-type: none"> • Yes • No • May be

Results and Discussion

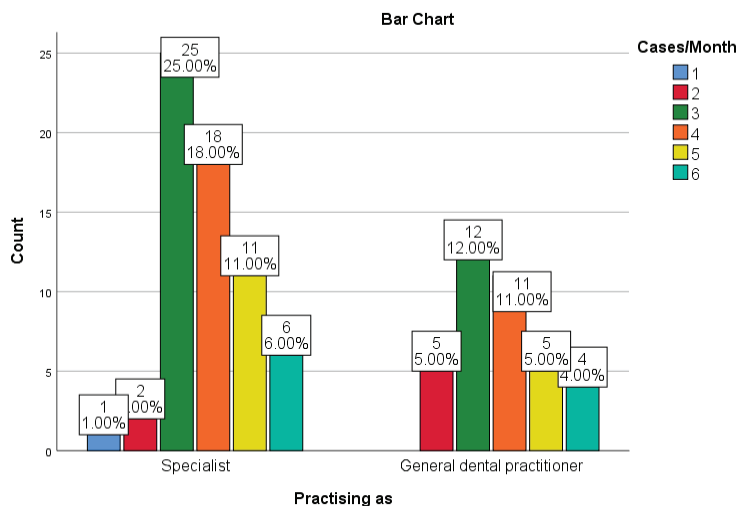
From the survey, the following results were observed and demonstrated below (graphs 1 - 6)



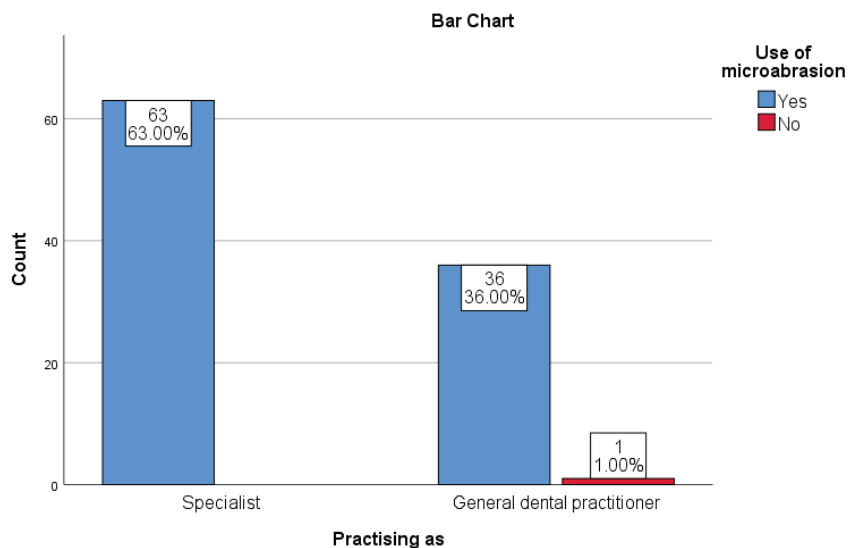
Graph 1 - Bar graph showing the association between field of practice (specialists / general practitioners) and white spot lesions. X axis represents the field of practice, Y axis represents the number of participants. Blue bar represents the dentist who turned up with answer white opacity, red represents the dentist who turned up with the answer enamel demineralization. Majority of the respondents (54% of the specialists and 29% of general practitioners) opted for white opacity. Chi square test was done and association was not significant (p value - 0.346;p >0.05) proving there was no statistical significant association between the field of practice (specialists / general practitioners) and their response to the question.



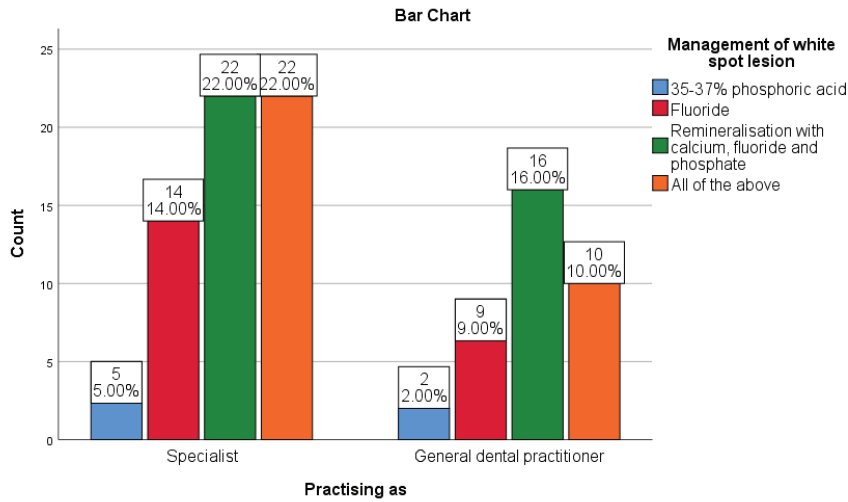
Graph 2 - Bar graph showing the association between field of practice (specialist / general practitioner) and identification of white spot lesion. X axis represents the field of practice, Y axis represents the number of participants. Blue bar represents the dentist who turned up with answer radiography, red represents the dentist who turned up with the answer visual observation. Majority of the respondents (42% of the specialists and 26% of general practitioners) opted for visual observation. Chi square test was done and association was not significant (p value - 0.709;p >0.05) proving there was no statistical significant association between the field of practice (specialists / general practitioners) and their response to the question.



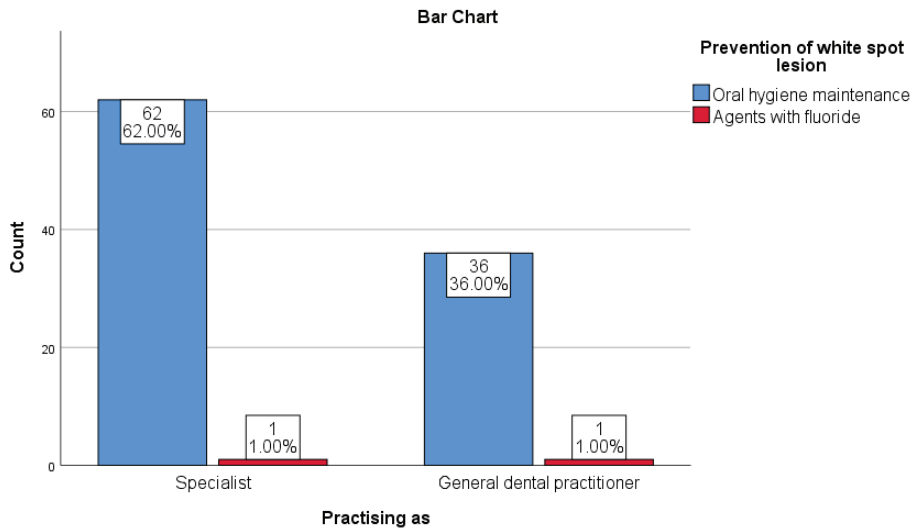
Graph 3 - Bar graph showing the association between field of practice (specialist / general practitioner) and identification of white spot lesion. X axis represents the field of practice, Y axis represents the number of participants. Blue bar represents the dentist who turned up with answer 1 patient per month, red represents the dentist who turned up with the answer 2 patient per month, green represents the dentist who turned up with the answer 3 patients per month, orange represents the dentist who turned up with the answer 4 patients per month, yellow represents the dentist who turned up with answer 5 patients per month, light blue represents the dentist who turned up with answer 6 patients per month. Majority of the respondents (25% of the specialists and 12% of general practitioners) opted for 3patients/month. Chi square test was done and association was not significant (p value - 0.447;p >0.05) proving there was no statistical significant association between the field of practice (specialists / general practitioners) and their response to the question.



Graph 4 - Bar graph showing the association between field of practice (specialist / general practitioner) and identification of white spot lesion. X axis represents the field of practice, Y axis represents the number of participants. Blue bar represents the dentist who turned up with yes, red represents the dentist who turned up with the answer no. Majority of the respondents (63% of the specialists and 36% of general practitioners) opted for yes. Chi square test was done and association was not significant (p value - 0.190;p >0.05) proving there was no statistical significant association between the field of practice (specialists / general practitioners) and their response to the question.



Graph 5 - Bar graph showing the association between field of practice (specialist / general practitioner) and identification of white spot lesion. X axis represents the field of practice, Y axis represents the number of participants. Blue bar represents the dentist who turned up with answer 35-37% phosphoric acid, red represents the dentist who turned up with the answer fluoride, green represents the dentist who turned up with the answer remineralisation using fluoride, calcium and phosphate, orange represents the dentist who turned up with answer all of the above. Majority of the respondents (22% of the specialists and 16% of general practitioners) opted for remineralisation using calcium, fluoride and phosphate. Chi square test was done and association was not significant (p value - 0.768;p >0.05) proving there was no statistical significant association between the field of practice (specialists / general practitioners) and their response to the question.



Graph 6 - Bar graph showing the association between field of practice (specialist / general practitioner) and identification of white spot lesion. X axis represents the field of practice, Y axis represents the number of participants. Blue bar represents the dentist who turned up with answer oral hygiene maintenance, red represents the dentist who turned up with the answer agents with fluoride. Majority of the respondents (62% of the specialists and 36% of general practitioners) opted for oral hygiene maintenance. Chi square test was done and association was not significant (p value - 0.700;p >0.05) proving there was no statistical significant association between the field of practice (specialists / general practitioners) and their response to the question.

The initial caries lesions are seen as a white opaque lesions on the enamel surface¹². The main and the common way of identifying a white spot lesion is by visual observation by the dentist³⁵. It is clear that the topical application of fluoride and remineralising cream on the white spot lesion helps in treating the white spot lesion. The recent studies also show that the white spot lesions can be treated by primary and secondary prevention³⁶. The use of fluoride toothpaste on a daily basis helps in reducing the white spot lesion⁴. Hence, as the white spot lesion causes cavities, operative procedures to be involved after cavitation. So as to prevent the tooth surface the white spot lesions should be prevented in early stages. The survey results helped in analysing the knowledge, awareness and practice on the management of white spot lesion, from the responses collected participants had a clear knowledge regarding the management of white spot lesion. They were aware of different treatment modalities available regarding the management of white spot lesions. The prevention of white spot lesion before the demineralisation and treatment after demineralisation are very important in managing such situations. Majority of the participants in the study were aware of the techniques used in the management of white spot lesions and implied them in their clinical practice to reverse the condition. There was no significant association found between specialists and the general practitioners in the responses obtained, which means both the general practitioners and the specialists are aware of the strategies available for the management of white spot lesions. The limitation of the study included the smaller population that was involved, some had false responses and irrelevant answers. The scope of the study was to find the knowledge about the management of the white spot lesion among the dentist.

Conclusion

Within the limitation of the study, the knowledge, attitude and practice regarding the management of white spot lesions were analysed. It showed that the majority of participated dentists were aware of different treatment strategies available for the management of white spot lesions and most of them were implying them on daily practice for the prevention and treatment of white spot lesions. There was no significant association between the field of practice (specialist /general practitioners) and their response to the question. Overall, the survey

showed good knowledge on the management of white spot lesions.

Acknowledgement: I would like to thank the Department of Conservative Dentistry and Endodontics from Saveetha Dental College, Chennai for their valuable inputs in this survey.

Conflicts of Interest: No conflicts of interest

Source of Funding: Self

Ethical Clearance: Not Required

References

1. Abdullah AlShehri BDS, So Ran Kwon, DDS, MS, PhD, MS. Etiology and Management Of White Spot Lesions [Internet]. *Decisions in Dentistry*. [cited 2020 Jun 6]. Available from: <https://decisionsindentistry.com/article/lesions-0116/>
2. Welbury R, Duggal MS, Hosey MT. *Paediatric Dentistry* [Internet]. Oxford University Press; 2012. 400 p. Available from: https://books.google.com/books/about/Paediatric_Dentistry.html?hl=&id=vvh7nqNxvyYC
3. Guo L, Shi W. Salivary biomarkers for caries risk assessment. *J Calif Dent Assoc* [Internet]. 2013 Feb;41(2):107–9, 112–8. Available from: <https://www.ncbi.nlm.nih.gov/pubmed/23505756>
4. Øgaard B. White Spot Lesions During Orthodontic Treatment: Mechanisms and Fluoride Preventive Aspects [Internet]. Vol. 14, *Seminars in Orthodontics*. 2008. p. 183–93. Available from: <http://dx.doi.org/10.1053/j.sodo.2008.03.003>
5. Kumar D, Delphine Priscilla Antony S. Calcified Canal and Negotiation-A Review [Internet]. Vol. 11, *Research Journal of Pharmacy and Technology*. 2018. p. 3727. Available from: <http://dx.doi.org/10.5958/0974-360x.2018.00683.2>
6. Zachrisson BU. A posttreatment evaluation of direct bonding in orthodontics [Internet]. Vol. 71, *American Journal of Orthodontics*. 1977. p. 173–89. Available from: [http://dx.doi.org/10.1016/s0002-9416\(77\)90394-3](http://dx.doi.org/10.1016/s0002-9416(77)90394-3)
7. Srivastava K, Tikku T, Khanna R, Sachan K. Risk factors and management of white spot lesions in orthodontics. *J Orthod Sci* [Internet]. 2013

- Apr;2(2):43–9. Available from: <http://dx.doi.org/10.4103/2278-0203.115081>
8. Bishara SE, Ostby AW. White Spot Lesions: Formation, Prevention, and Treatment [Internet]. Vol. 14, Seminars in Orthodontics. 2008. p. 174–82. Available from: <http://dx.doi.org/10.1053/j.sodo.2008.03.002>
 9. Jälevik B, Norén JG. Enamel hypomineralization of permanent first molars: a morphological study and survey of possible aetiological factors. *Int J Paediatr Dent* [Internet]. 2000 Dec;10(4):278–89. Available from: <http://dx.doi.org/10.1046/j.1365-263x.2000.00210.x>
 10. Almualllem Z, Busuttil-Naudi A. Molar incisor hypomineralisation (MIH) - an overview. *Br Dent J* [Internet]. 2018 Oct 5; Available from: <http://dx.doi.org/10.1038/sj.bdj.2018.814>
 11. Deveci C, Çınar Ç, Tirali RE. Management of White Spot Lesions [Internet]. *Dental Caries - Diagnosis, Prevention and Management*. 2018. Available from: <http://dx.doi.org/10.5772/intechopen.75312>
 12. Pathak S, Roopa K, Poornima P, Neena I. White spot lesions: A literature review [Internet]. Vol. 3, *Journal of Pediatric Dentistry*. 2015. p. 1. Available from: <http://dx.doi.org/10.4103/2321-6646.151839>
 13. Lynch RJM, Smith SR. Remineralization agents - new and effective or just marketing hype? *Adv Dent Res* [Internet]. 2012 Sep;24(2):63–7. Available from: <http://dx.doi.org/10.1177/0022034512454295>
 14. Amaechi BT. Remineralisation – the buzzword for early MI caries management [Internet]. Vol. 223, *British Dental Journal*. 2017. p. 173–82. Available from: <http://dx.doi.org/10.1038/sj.bdj.2017.663>
 15. Restrepo M, Bussaneli DG, Jeremias F, Cordeiro RCL, Raveli DB, Magalhães AC, et al. Control of White Spot Lesions with Use of Fluoride Varnish or Chlorhexidine Gel During Orthodontic Treatment A Randomized Clinical Trial. *J Clin Pediatr Dent* [Internet]. 2016;40(4):274–80. Available from: <http://dx.doi.org/10.17796/1053-4628-40.4.274>
 16. Siddique R, Sureshbabu NM, Somasundaram J, Jacob B, Selvam D. Qualitative and quantitative analysis of precipitate formation following interaction of chlorhexidine with sodium hypochlorite, neem, and tulsi. *J Conserv Dent* [Internet]. 2019 Jan;22(1):40–7. Available from: http://dx.doi.org/10.4103/JCD.JCD_284_18
 17. Noor SSSE, S Syed Shihaab, Pradeep. Chlorhexidine: Its properties and effects [Internet]. Vol. 9, *Research Journal of Pharmacy and Technology*. 2016. p. 1755. Available from: <http://dx.doi.org/10.5958/0974-360x.2016.00353.x>
 18. Bussadori SK, do Rego MA, da Silva PE, Pinto MM, Pinto ACG. Esthetic alternative for fluorosis blemishes with the usage of a dual bleaching system based on hydrogen peroxide at 35% [Internet]. Vol. 28, *Journal of Clinical Pediatric Dentistry*. 2005. p. 143–6. Available from: <http://dx.doi.org/10.17796/jcpd.28.2.g45173lp7661g078>
 19. Kim S, Kim E-Y, Jeong T-S, Kim J-W. The evaluation of resin infiltration for masking labial enamel white spot lesions. *Int J Paediatr Dent* [Internet]. 2011 Jul;21(4):241–8. Available from: <http://dx.doi.org/10.1111/j.1365-263X.2011.01126.x>
 20. Kaminer R. Bioactive Composite Used to Effectively Treat Carious White-Spot Lesion. *Compend Contin Educ Dent* [Internet]. 2019;40(suppl 1):4–6. Available from: <https://www.ncbi.nlm.nih.gov/pubmed/31478683>
 21. Rajendran R, Kunjusankaran RN, Sandhya R, Anilkumar A, Santhosh R, Patil SR. Comparative Evaluation of Remineralizing Potential of a Paste Containing Bioactive Glass and a Topical Cream Containing Casein Phosphopeptide-Amorphous Calcium Phosphate: An in Vitro Study [Internet]. Vol. 19, *Pesquisa Brasileira em Odontopediatria e Clínica Integrada*. 2019. p. 1–10. Available from: <http://dx.doi.org/10.4034/pboci.2019.191.61>
 22. Hussainy SN, Nasim I, Thomas T, Ranjan M. Clinical performance of resin-modified glass ionomer cement, flowable composite, and polyacid-modified resin composite in noncarious cervical lesions: One-year follow-up. *J Conserv Dent* [Internet]. 2018 Sep;21(5):510–5. Available from: http://dx.doi.org/10.4103/JCD.JCD_51_18
 23. Ravinthar K, Jayalakshmi. Recent Advancements in Laminates and Veneers in Dentistry [Internet]. Vol. 11, *Research Journal of Pharmacy and Technology*. 2018. p. 785. Available from: <http://dx.doi.org/10.5958/0974-360x.2018.00148.8>
 24. Kim H-J, Karanxha L, Park S-J. Non-destructive

- management of white spot lesions by using tooth jewelry. *Restor Dent Endod* [Internet]. 2012 Nov;37(4):236–9. Available from: <http://dx.doi.org/10.5395/rde.2012.37.4.236>
25. Inc. KN, Kernel Networks Inc. Remineralization Potential of GSE Gel versus CPP-ACP in Carious White Spot Lesions in Post Orthodontic Patients [Internet]. *Case Medical Research*. 2019. Available from: <http://dx.doi.org/10.31525/ct1-nct03966378>
 26. Nandakumar M, Nasim I. Comparative evaluation of grape seed and cranberry extracts in preventing enamel erosion: An optical emission spectrometric analysis. *J Conserv Dent* [Internet]. 2018 Sep;21(5):516–20. Available from: http://dx.doi.org/10.4103/JCD.JCD_110_18
 27. Ramamoorthi S, Nivedhitha MS, Divyanand MJ. Comparative evaluation of postoperative pain after using endodontic needle and EndoActivator during root canal irrigation: A randomised controlled trial. *Aust Endod J* [Internet]. 2015 Aug;41(2):78–87. Available from: <http://dx.doi.org/10.1111/aej.12076>
 28. Jose J, P. A, Subbaiyan H. Different Treatment Modalities followed by Dental Practitioners for Ellis Class 2 Fracture – A Questionnaire-based Survey [Internet]. Vol. 14, *The Open Dentistry Journal*. 2020. p. 59–65. Available from: <http://dx.doi.org/10.2174/1874210602014010059>
 29. Janani K, Palanivelu A, Sandhya R. Diagnostic accuracy of dental pulse oximeter with customized sensor holder, thermal test and electric pulp test for the evaluation of pulp vitality - An in vivo study [Internet]. Vol. 23, *Brazilian Dental Science*. 2020. Available from: <http://dx.doi.org/10.14295/bds.2020.v23i1.1805>
 30. R R, Rajakeerthi R, Ms N. Natural Product as the Storage medium for an avulsed tooth – A Systematic Review [Internet]. Vol. 22, *Cumhuriyet Dental Journal*. 2019. p. 249–56. Available from: <http://dx.doi.org/10.7126/cumudj.525182>
 31. Ramanathan S, Solete P. Cone-beam Computed Tomography Evaluation of Root Canal Preparation using Various Rotary Instruments: An in vitro Study [Internet]. Vol. 16, *The Journal of Contemporary Dental Practice*. 2015. p. 869–72. Available from: <http://dx.doi.org/10.5005/jp-journals-10024-1773>
 32. Teja KV, Ramesh S. Shape optimal and clean more. *Saudi Endodontic Journal* [Internet]. 2019 Sep 1 [cited 2020 Jun 5];9(3):235. Available from: <http://www.saudiendodj.com/article.asp?issn=1658-5984;year=2019;volume=9;issue=3;spage=235;epage=236;aulast=Teja>
 33. Manohar MP, Sharma S. A survey of the knowledge, attitude, and awareness about the principal choice of intracanal medicaments among the general dental practitioners and nonendodontic specialists. *Indian J Dent Res* [Internet]. 2018 Nov;29(6):716–20. Available from: http://dx.doi.org/10.4103/ijdr.IJDR_716_16
 34. Teja KV, Ramesh S, Priya V. Regulation of matrix metalloproteinase-3 gene expression in inflammation: A molecular study. *J Conserv Dent* [Internet]. 2018 Nov;21(6):592–6. Available from: http://dx.doi.org/10.4103/JCD.JCD_154_18
 35. Julien KC, Buschang PH, Campbell PM. Prevalence of white spot lesion formation during orthodontic treatment. *Angle Orthod* [Internet]. 2013 Jul;83(4):641–7. Available from: <http://dx.doi.org/10.2319/071712-584.1>
 36. Bergstrand F, Twetman S. A review on prevention and treatment of post-orthodontic white spot lesions - evidence-based methods and emerging technologies. *Open Dent J* [Internet]. 2011 Sep 16;5:158–62. Available from: <http://dx.doi.org/10.2174/1874210601105010158>