

Prevalence of Different Types of Keratosis in Patients in a University Setting

P. Keshaav Krishnaa¹, Manjari Chaudhary²,

¹Research Associate, Dental Research Cell, Saveetha Dental College and Hospitals, ²Senior Lecturer, Department of Oral Medicine and Radiology, ³Senior Lecturer, Department of Conservative Dentistry and Endodontics, Saveetha Dental College and Hospitals, Saveetha Institute of Medical and Technical Sciences (SIMATS), Saveetha University, Chennai, India

Abstract

The most commonly occurring type of keratosis would be tobacco pouch keratosis or smokeless tobacco associated keratosis, frictional keratosis, a chronic frictional keratosis on the buccal mucosa can lead to something called morsicatio buccarum. Although clinical features are very important and should be one of the important factors in diagnosis, epidemiology should also be considered while arriving at a concrete diagnosis. The aim of the present study was to retrospectively analyze the prevalence of different clinical variants of Keratosis in patients visiting Saveetha Dental College. Retrospective data of 195 patients was obtained and segregated. Inclusion criteria included that they should have visited the University between June 2019 and April 2020. Once the data was obtained and verified, it was statistically analyzed using SPSS by IBM version 20. Most common clinical variant was Tobacco pouch Keratosis (64.6%) followed by Frictional Keratosis (28.7%). Mean age of the patients was 37.40 + or -10.98 years. Tobacco pouch keratosis occurring most commonly in lower arch (67.46%) whereas the Frictional keratosis most commonly in relation to both arches (42.85%). All common in 21-30 years age group. Statistically significant correlation between the site of lesion and variant ($p = 0.000$) and between gender and variant ($p=0.00$) Increased Habit Prevalence as the number of Tobacco pouch Keratosis cases are greater. Further multicentered studies and awareness programs to help the society and prevent these lesions.

Key Words: Keratosis, Oral, Tobacco Pouch Keratosis, Frictional Keratosis, Chennai.

Introduction

Diagnosis of oral white lesions might be quite challenging. There are various recent trends^{1,2} These lesions represent a wide spectrum of lesions with different etiology and various prognosis. In recent years there has been development of various lesions³⁻⁶, developmental anomalies^{7,8} and various malignancies⁹. These changing trends can be attributed to the changes in

lifestyle and practices^{10,11,12}. Although there are various modalities of treatment in recent times^{13,14} diagnosis is very important¹⁵.

The diagnosis of white lesions varies from benign reactive lesions to more serious dysplastic lesions. While there are some classic features that help distinguish these lesions, similar features might give some complications in diagnosis¹⁶

Corresponding author:

Manjari Chaudhary

Senior Lecturer, Department of Oral Medicine and Radiology, Saveetha Dental College and Hospitals, Saveetha Institute of Medical and Technical Sciences (SIMATS), Saveetha University, Chennai, India
Email ID: manjaric.sdc@saveetha.com

The onset of oral white lesions can be acquired or congenital. Oral white lesions can be caused by a thickened keratotic layer or an accumulation of non-keratotic material. A gauze should be used to assess if the lesion is scrapable or non-scrapable. If non-scrapable lesions can be attributed to increased thickness of the keratin layer, which might have been induced by local factors which can lead to the formation of different types

of keratosis¹⁶⁻¹⁸. Diagnosis is an important aspect. It is important to diagnose a case of keratosis, not as leukoplakia as it is a common error that could result in serious complication¹⁹.

The most commonly occurring type of keratosis would be tobacco pouch keratosis or smokeless tobacco associated keratosis, frictional keratosis, a chronic frictional keratosis on the buccal mucosa can lead to something called morsicatio buccarum²⁰. Although clinical features are very important and should be one of the important factors in diagnosis, epidemiology should also be considered while arriving at a concrete diagnosis.

With the recent advent of time there has been varied prevalence of lesions due to changes in lifestyle habits and other factors. It is important to have an updated epidemiological perspective about a particular lesion as there can be potential changes with time. There has not been any study that provides the epidemiological view of most common keratosis as a whole. The aim of the present retrospective cross sectional study is to evaluate the prevalence of different types of keratosis in patients that visit a dental college (Saveetha Dental College and Hospitals) in Chennai.

Materials & Methods

The present retrospective study was conducted among 195 patients who were clinically diagnosed with a variant of keratosis. The study performed in the university setting (Saveetha Dental College and Hospitals, Chennai, India) thus the data available is of patients from the same geographic location and have ethnicity. The ethical approval for the retrospective data that was collected from the dental archives of the Department of Oral Medicine and Radiology, Saveetha Dental College was obtained from the Institutional Ethics Board

(SDC/SIHEC/2020/DIASDATA/0619-0320).

The data was collected and studied for the period from June 2019 to April 2020. Once the data was obtained, the same was verified with the help of photographs by two external reviewers to limit and restrict any aspect of bias towards the present study. A well-defined elaborate inclusion criterion was laid out before the commencement of the present retrospective

study. The inclusion criteria that was constructed included:

- The patient should have visited during the period of the study and treated by a resident of Saveetha Dental College (Undergraduates or Postgraduates)

- Should have been clinically diagnosed with a variant of keratosis.

On segregation of all available samples, all non specific data entries such as double entries and other types of censored data were excluded from the present study. Thus the obtained master data sheet was verified by another external reviewer. The data was tabulated and the same was analyzed using SPSS by IBM version 20. The frequencies and cross tabulations were performed followed by correlation and association using chi square test to check correlation between the different variables. The results thus obtained were analyzed.

Results and Discussion

A total of 195 patients were included as a part of the present retrospective study, out of which 178 patients were males (91.3%) and 17 patients were females (8.7%) (Graph 1). The lesion was present most commonly in the lower arch (55.4%) than being present in relation to both arches (31.8%) and upper arch (12.8%). The most commonly occurring clinical variant of keratosis was Tobacco Pouch Keratosis (64.6%) followed by Frictional Keratosis (28.7%) and least occurring was morsicatio buccarum (6.7%) (Graph 2). The mean age of the patients who had keratosis was 37.08 + or – 10.98 years. When the gender distribution of each clinical variant is observed, all three lesions were more prevalent in males than females . In males the most commonly occurring clinical variant was Tobacco Pouch Keratosis (67.97%) followed by Frictional Keratosis (26.40%). In females the most commonly occurring clinical variant was Frictional keratosis (52.94%) followed by Tobacco Pouch Keratosis (29.41%). A statistically significant ($p = 0.005$) correlation was observed between gender and clinical variant of Keratosis . When age groups are considered, Tobacco Pouch Keratosis was most common in the age group of 21- 30 years (35.71%) (Table 1), Frictional Keratosis was also most common in 21 -30 years (30.35%), similar age group common for morsicatio buccarum (46.15%) as well. statistically

significant ($p < 0.05$) correlation was obtained. When location or site of the lesion was being considered, Tobacco Pouch Keratosis was present more in lower arch (67.46%) (Graph 3). Frictional Keratosis occurs most commonly in relation to both arches (42.85%) and morscicatio buccarum also occurs most frequently in relation to both arches (69.23%). Statistically significant correlation was obtained between the location of the lesion and clinical variant ($p = 0.000$).

It is surprising that even though Keratosis is one of the most commonly occurring oral lesions, yet there are cases of misdiagnosis. This is the first of its kind study where the prevalence of different types of keratosis are seen in geographic location. The three clinical variants of Keratosis that are reported in the geographic location of the present study are Tobacco Pouch Keratosis, Frictional Keratosis, Morscicatio buccarum. Out of these three, tobacco pouch keratosis is related to tobacco usage²¹ whereas the other two are not directly related to tobacco usage.

In the present study it is observed that the tobacco pouch keratosis is more prevalent in males than in females. This can be attributed to the fact that there is more usage of tobacco products among the male gender than the female gender as reported by Bhawna G et al²² in a national survey conducted on tobacco consumption. Tobacco pouch keratosis or smokeless tobacco induced keratosis develops on habitual chewing or due to snuff dipping tobacco²³. In the present study the most common area in the oral cavity that is associated with tobacco pouch keratosis is the lower arch. This can be attributed to the fact that the most common area associated with placing tobacco in the lower vestibule. The most common age group for Tobacco Pouch Keratosis is 21-30 years as reported by Poornima Chandra et al²⁴. This age group has an increase of smokeless forms of tobacco and thus this could be the reason for prevalence of the lesion in this age group. When compared with the findings in different parts of India, the following are observed. In a study conducted by KA Kamala et al²⁵ in Maharashtra, it is observed that the prevalence in males is greater than in females which is in agreement with the findings of the present study. Similar findings recorded by Rakhi Chandak et al²⁵ in a Vidharbian population which also showed a male prevalence. Manjiri Joshi et al^{25,26} in a study in central Gujarat concluded that

there is an increased usage of smokeless tobacco than smoking and Tobacco Pouch Keratosis was associated with the same which is in line with the findings of the present study when age grouping and area is considered. In a study conducted by Anuna Laila Mathew et al²⁷ in 2007, where oral mucosal lesion prevalence is seen in the South Indian population, there is no report of even one patient with Tobacco Pouch Keratosis although tobacco users are included in the study. The present study is also placed in a south Indian population, thus the results from the previous study are contradictory to that of the present one. This can be associated with the trend change in tobacco usage through the years. Thus when the trends are compared with that of the rest of the country, it is almost in agreement with the findings of the present study. Now, let us assess the prevalence on a global scale. Hakan Mornstad et al conducted a study in Sweden which also showed a male predilection for the disease. In Sudanese population, A.M Idris et Al²⁸ reported that the lesional site in the majority of cases with tobacco pouch keratosis was the lower labial mucosa which is in agreement to the findings of the present study. However when we consider underdeveloped countries like Africa OA Ayo Yusuf et al²⁹ report an increased occurrence in an older age group greater than 60 years. Even though the common site is the lower arch is in agreement with the findings of the present study, the age prevalence is in disagreement. This can be attributed to socioeconomic status, but also gives an insight into tobacco dependence in the particular region. Thus a globally uniform regimen is brought about to educate the population and prevent the occurrence of such lesions.

The next most prevalent clinical variant in the present study is Frictional Keratosis and the least prevalent is morscicatio buccarum, which is nothing but a more chronic form of frictional keratosis of the buccal mucosa³⁰. Parafunctional habits whereby there is constant rubbing, chewing or sucking of the oral mucosa against the teeth can result in the formation of this clinical variant. The occurrence of Frictional Keratosis is markedly more in males than in females in the present study. This can be attributed to more rigorous chewing habits in males which may lead to local factors like tissue chewing or malposition of teeth. Usually there is however a female predilection³¹

The most common age group for the occurrence of frictional keratosis in the present study is 21 – 30 years. This can be explained by the fact that there is an increase in the prevalence of parafunctional habits during this age group³² which may in turn lead to the development of a clinical variant of Keratosis.

When compared with the knowledge that is available regarding the same in other parts of India, the following are observed. N C Sandeepa et al³³, in a study that was conducted on a college population observed that males are affected more commonly by Frictional Keratosis than females. This is of the present study. In the study by Ar et al^{33,34} in vidharbian also 1 predilection. In the study by Ar²⁷ the age group in which friction common was 21 – 40 years age, the age group prevalence that is study. However in the study car Vijayabala et al³⁵ it is observed occurrence in older age groups, further factors faulty restoration when the entire nation is concer in mild disagreement whereas t on prevalence of gender.

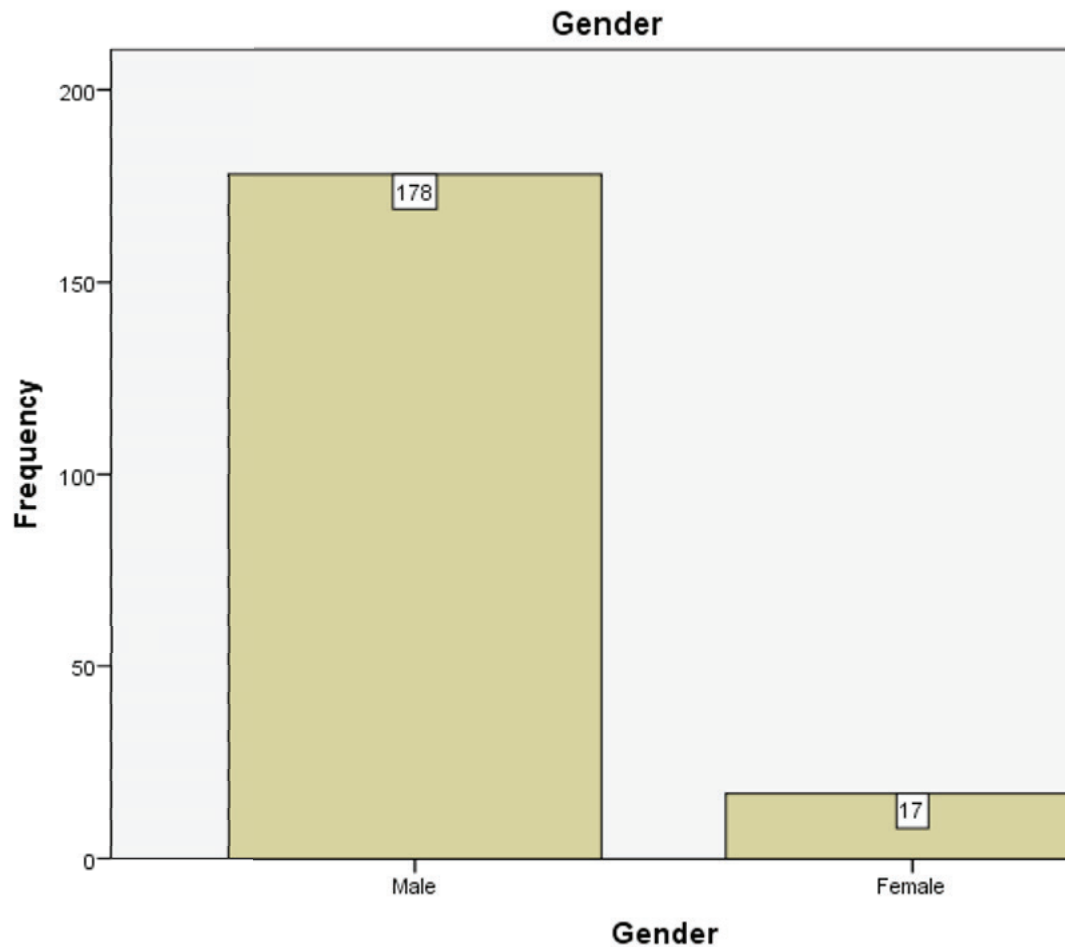
When we compare the sam following observations are seen. population of Slovenia, Marija that females are more common t Keratosis than men. The mo was reported to be in 65 – 75 contradictory to the findings of could be attributed to the ge practice patterns. FC Macigo et : population that males are mc Keratosis than females. Thus it i discussion that there is no specific gender predilection for Frictional Keratosis. However, there is disagreement on age prevalence as well, further multicentered studies are to be done to gain concise knowledge and improve diagnosis and treatment.

There are very few studies which compare the prevalence of Tobacco Pouch Keratosis and Frictional Keratosis. Rakhi Chandak et al³⁴ reported that there is an increased occurrence of Frictional Keratosis than

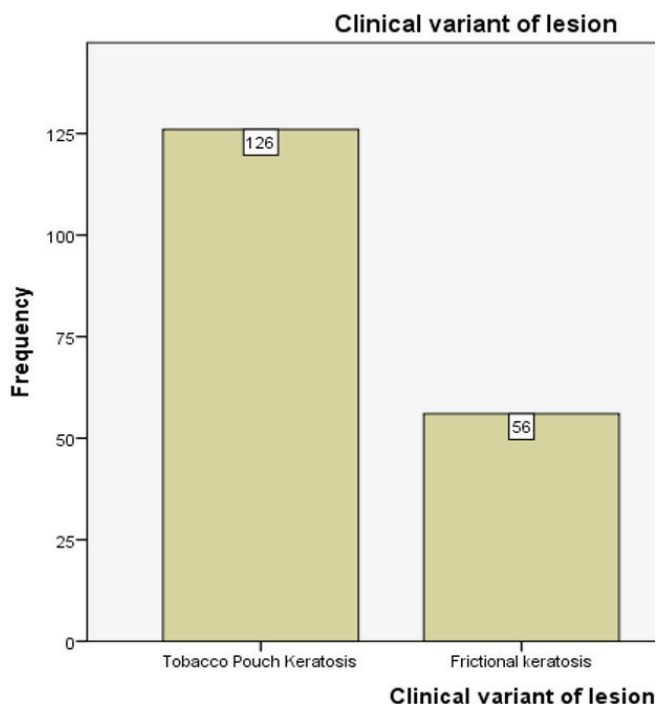
Tobacco Pouch Keratosis. However, as in the present study it is the other way around. This raises alarm as it possibly implies that there is an increased usage of smokeless tobacco. Further studies are to be done to gain appropriate knowledge and combat the knowledge and combat the issue.

The limitations of the study included that it was single centered, geographically isolated and habit history was not taken into account.

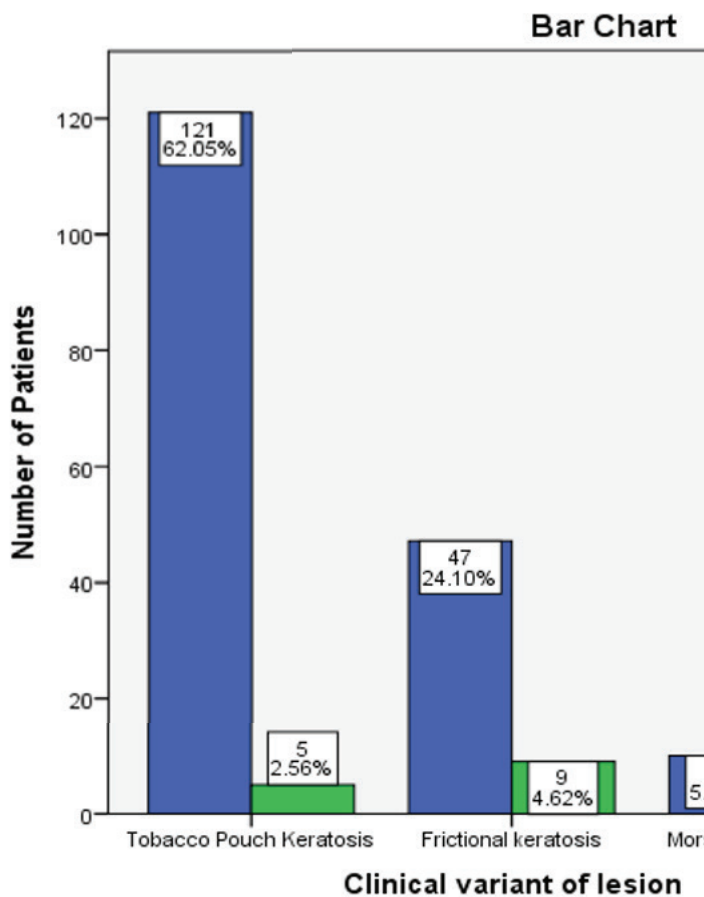
1. Tables And Graphs:



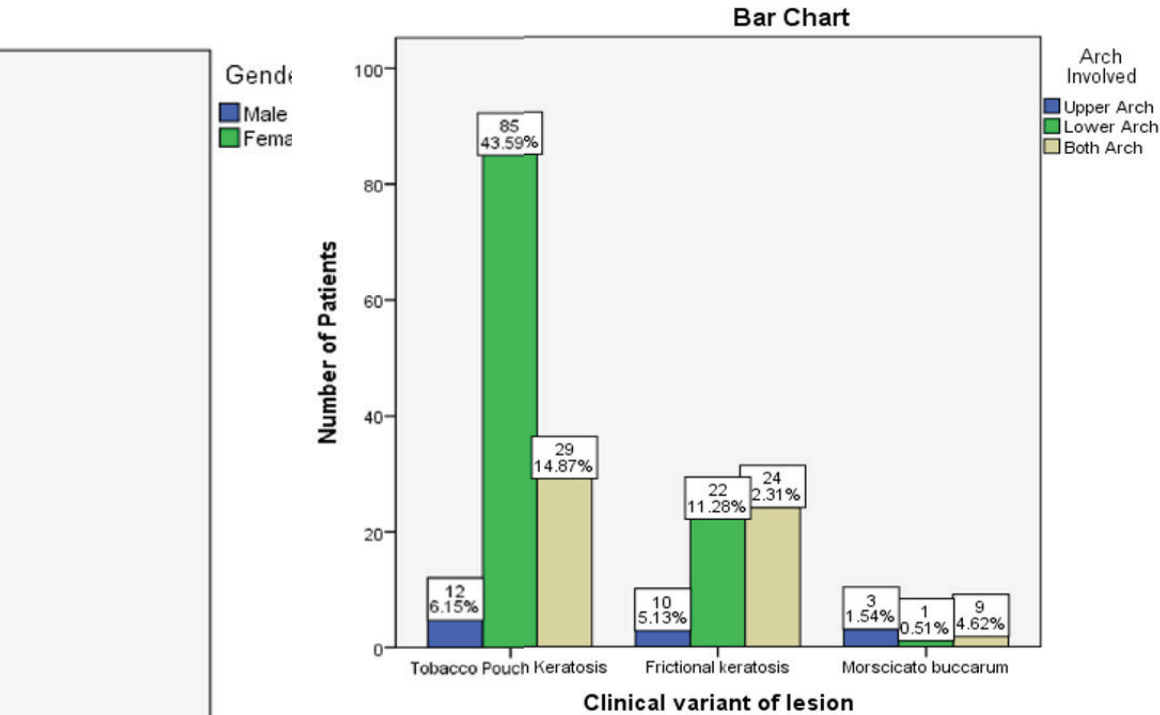
Graph 1: Bar Graph shows Distribution of keratosis in Male and females with the gender in the x axis and the frequency in the y axis. The most common gender to be affected is the male gender (91.28%)



Graph 2: Bar Graph shows Distribution of different clinical variants of lesions with the clinical variant in the x axis and the frequency in the y axis. The most common clinical variant in the present study is Tobacco Pouch Keratosis(64.61%)



Graph 3: Graph shows association between gender and different clinical variants of keratosis with the clinical variant in the x axis and number of clinical variants in the y axis. Males are represented in blue and females are represented in green. All clinical variants are seen more commonly in males than in females. In males the most common clinical variant is Tobacco Pouch Keratosis (62.05%) whereas the most common clinical variant in females is frictional keratosis (4.62%). Statistically Significant association is seen using chi square test with Value=10.745, df=2, p=0.05 (p≤ 0.05)–Statistically Significant.



Graph 3: Bar graph shows association between the location of the lesion and the clinical variant of keratosis with the clinical variant in the x axis and number of lesions in the y axis. The upper arch is represented in blue colour, lower arch in green colour and both arches in brown colour. Tobacco Pouch Keratosis is seen more commonly in the lower arch (43.59%) whereas Frictional Keratosis is seen more commonly associated with both arches (12.31%). Statistically Significant result is obtained using Chi Square test with Value= 27.087, df=4 and p=0.000(p<0.05)-Statistically Significant.

Table 1: Table shows association between age and the clinical variant of the lesion. All three clinical variants occur most commonly in a younger age group. Statistically significant association using Chi Square test, Pearson’s Chi Square Value=110.66, df=86, p=0.03

Age Groups							p value 0.03
Clinical Variant	21-30 Years	31-40 Years	41-50 Years	51-60 Years	61-70 Years	Total	
Tobacco Pouch Keratosis	45	39	30	11	1	126	
Frictional Keratosis	17	12	15	9	3	56	
Morscicato Buccarum	6	2	3	2	0	13	

(p ≤ 0.05)-Statistically Significant

Conclusion

The present study has certainly raised certain alarms, as in the limits of the study Tobacco Pouch Keratosis is more prevalent than Frictional Keratosis. Further multicentered studies to be done and awareness programmes to prevent the formation of such lesions and help the entire community.

Acknowledgements: We thank Saveetha Dental College and Hospitals, Chennai for access to the retrospective data.

Conflict of Interest: No conflict of Interest.

Source of Funding : Self.

Ethical Clearance: It is taken from “Saveetha Institute Human Ethical Committee” (Ethical Approval Number- SDC/SIHEC/2020/DIASDATA/0619-0320)

References

- Venugopal A, Maheswari TNU. Expression of matrix metalloproteinase-9 in oral potentially malignant disorders: A systematic review [Internet]. Vol. 20, *Journal of Oral and Maxillofacial Pathology*. 2016. p. 474. Available from: <http://dx.doi.org/10.4103/0973-029x.190951>
- Maheswari TNU, Venugopal A, Sureshbabu N, Ramani P. Salivary micro RNA as a potential biomarker in oral potentially malignant disorders: A systematic review [Internet]. Vol. 30, *Tzu Chi Medical Journal*. 2018. p. 55. Available from: http://dx.doi.org/10.4103/tcmj.tcmj_114_17
- Dharman S, Muthukrishnan A. Oral mucous membrane pemphigoid--Two case reports with varied clinical presentation. *J Indian Soc Periodontol*. 2016;20(6):630.
- Muthukrishnan A, Kumar LB, Ramalingam G. Medication-related osteonecrosis of the jaw: a dentist's nightmare [Internet]. *BMJ Case Reports*. 2016. p. bcr2016214626. Available from: <http://dx.doi.org/10.1136/bcr-2016-214626>
- Muthukrishnan A, Kumar LB. Actinic cheilosis: early intervention prevents malignant transformation [Internet]. *BMJ Case Reports*. 2017. p. bcr2016218654. Available from: <http://dx.doi.org/10.1136/bcr-2016-218654>
- Choudhury P. Vanishing Roots: First Case Report of Idiopathic Multiple Cervico–Apical External Root Resorption [Internet]. *JOURNAL OF CLINICAL AND DIAGNOSTIC RESEARCH*. 2015. Available from: <http://dx.doi.org/10.7860/jcdr/2015/11698.5668>
- Patil SR, Maragathavalli G, Araki K, Al-Zoubi IA, Sghaireen MG, Gudipani RK, et al. Three-Rooted Mandibular First Molars in a Saudi Arabian Population: A CBCT Study [Internet]. Vol. 18, *Pesquisa Brasileira em Odontopediatria e Clínica Integrada*. 2018. p. e4133. Available from: <http://dx.doi.org/10.4034/pboci.2018.181.87>
- Subha M, Arvind M. Role of Magnetic Resonance Imaging in Evaluation of Trigeminal Neuralgia with its Anatomical Correlation [Internet]. Vol. 12, *Biomedical and Pharmacology Journal*. 2019. p. 289–96. Available from: <http://dx.doi.org/10.13005/bpj/1640>
- Misra S, Shankar Y, Rastogi V, Maragathavalli G. Metastatic hepatocellular carcinoma in the maxilla and mandible, an extremely rare presentation [Internet]. Vol. 6, *Contemporary Clinical Dentistry*. 2015. p. 117. Available from: <http://dx.doi.org/10.4103/0976-237x.152966>
- Subashri A, Uma Maheshwari TN. Knowledge and attitude of oral hygiene practice among dental students [Internet]. Vol. 9, *Research Journal of Pharmacy and Technology*. 2016. p. 1840. Available from: <http://dx.doi.org/10.5958/0974-360x.2016.00375.9>
- Warnakulasuriya S, Muthukrishnan A. Oral health consequences of smokeless tobacco use [Internet]. Vol. 148, *Indian Journal of Medical Research*. 2018. p. 35. Available from: http://dx.doi.org/10.4103/ijmr.ijmr_1793_17
- Rohini S, Jayanth Kumar V. Incidence of dental caries and pericoronitis associated with impacted mandibular third molar-A radiographic study [Internet]. Vol. 10, *Research Journal of Pharmacy and Technology*. 2017. p. 1081. Available from: <http://dx.doi.org/10.5958/0974-360x.2017.00196.2>
- Chaitanya NC. Role of Vitamin E and Vitamin A in Oral Mucositis Induced by Cancer Chemo/Radiotherapy- A Meta-analysis [Internet]. *JOURNAL OF CLINICAL AND DIAGNOSTIC RESEARCH*. 2017. Available from: <http://dx.doi.org/10.7860/jcdr/2017/26845.9905>
- Chaitanya N, Muthukrishnan A, Krishnaprasad CMS, Sanjuprasanna G, Pillay P, Mounika B. An

- insight and update on the analgesic properties of vitamin C [Internet]. Vol. 10, Journal of Pharmacy And Bioallied Sciences. 2018. p. 119. Available from: http://dx.doi.org/10.4103/jpbs.jpbs_12_18
15. Steele JC, Clark HJ, Hong CHL, Jurge S, Muthukrishnan A, Ross Kerr A, et al. World Workshop on Oral Medicine VI: an international validation study of clinical competencies for advanced training in oral medicine [Internet]. Vol. 120, Oral Surgery, Oral Medicine, Oral Pathology and Oral Radiology. 2015. p. 143–51. e7. Available from: <http://dx.doi.org/10.1016/j.oooo.2014.12.026>
 16. Mortazavi H, Safi Y, Baharvand M, Rahmani S. Diagnostic Features of Common Oral Ulcerative Lesions: An Updated Decision Tree [Internet]. Vol. 2016, International Journal of Dentistry. 2016. p. 1–14. Available from: <http://dx.doi.org/10.1155/2016/7278925>
 17. Glick M. Burket's Oral Medicine, 12th Edition. PMPH USA; 2015. 732 p.
 18. Neville BW, Damm DD, Allen CM, Chi AC. Oral and maxillofacial pathology. 2015; Available from: <https://books.google.com/books?hl=en&lr=&id=Qs-JCgAAQBAJ&oi=fnd&pg=PP1&dq=Neville+B+Oral+and+Maxillofacial+pathology&ots=mpZ4AInD-o&sig=mnHZZ8tXOcjQJvfKGWCSZ1BR0O4>
 19. Woo SB, Grammer RL, Lerman MA. Keratosis of unknown significance and leukoplakia: a preliminary study. oral medicine, oral pathology and oral ... [Internet]. 2014; Available from: <https://www.sciencedirect.com/science/article/pii/S2212440314012681>
 20. Müller S. Frictional Keratosis, Contact Keratosis and Smokeless Tobacco Keratosis: Features of Reactive White Lesions of the Oral Mucosa. Head Neck Pathol [Internet]. 2019; Available from: <https://link.springer.com/article/10.1007/s12105-018-0986-3>
 21. Taybos G. Oral Changes Associated with Tobacco Use. Am J Med Sci. 2003 Oct 1;326(4):179–82.
 22. Bhawna G. Burden of Smoked and Smokeless Tobacco Consumption in India - Results from the Global adult Tobacco Survey India (GATS-India)- 2009-2010. Asian Pac J Cancer Prev. 2013;14(5):3323–9.
 23. Donald PM, Renjith G, Arora A. Tobacco pouch keratosis in a young individual: A brief description. Journal of Indian Society of [Internet]. 2017; Available from: <https://www.ncbi.nlm.nih.gov/pmc/articles/PMC5803885/>
 24. Chandra P, Govindraju P. Prevalence of oral mucosal lesions among tobacco users. Oral Health Prev Dent. 2012;10(2):149.
 25. Kamala KA, Sankethguddad S, Nayak AG, Sanade AR, Rani SRA. Prevalence of oromucosal lesions in relation to tobacco habit among a Western Maharashtra population. Indian J Cancer. 2019 Jan 1;56(1):15.
 26. Joshi M, Tailor M. Prevalence of most commonly reported tobacco-associated lesions in central Gujarat: A hospital-based cross-sectional study. Indian J Dent Res. 2016 Jul 1;27(4):405.
 27. Mathew AL, Pai KM, Sholapurkar AA, Vengal M. The prevalence of oral mucosal lesions in patients visiting a dental school in Southern India. Indian J Dent Res. 2008 Apr 1;19(2):99.
 28. Idris AM, Warnakulasuriya K, Ibrahim YE, Nielsen R, Cooper D, Johnson NW. Toombak-associated oral mucosal lesions in Sudanese show a low prevalence of epithelial dysplasia. J Oral Pathol Med. 1996;25(5):239–44.
 29. Ayo-Yusuf OA, Swart TJ, Ayo-Yusuf IJ. Prevalence and pattern of snuff dipping in a rural South African population. SADJ: journal of the South African Dental Association= tydskrif van die Suid-Afrikaanse Tandheelkundige Vereniging. 2000;55(11):610–4.
 30. Wollina U. Morsicatio mucosae oris [Internet]. Vol. 34, hautnah dermatologie. 2018. p. 8–8. Available from: <http://dx.doi.org/10.1007/s15012-018-2614-z>
 31. Flaitz CM. Oral frictional hyperkeratosis. 2009; Available from: <http://centrodontoiatriconocerino.it/wp/wp-content/uploads/2016/09/Oral-Frictional-Hyperkeratosis.pdf>
 32. Chatzopoulos GS, Sanchez M, Cisneros A, Wolff LF. Prevalence of temporomandibular symptoms and parafunctional habits in a university dental clinic and association with gender, age, and missing teeth. CRANIO®. 2019 May 4;37(3):159–67.
 33. Sandeepa NC, Jaishankar HP, Sharath CB, Abhinetra MS, Darshan DD, Deepika N. Prevalence of oral mucosal lesions among pre-university students of Kodava population in Coorg

- district. *Journal of international oral health: JIOH*. 2013;5(3):35.
34. Chandak R, Pandharipande R, Kulkarni S, Others. Prevalence of Oral Mucosal Lesions among Vidharbian Population: A Cross-Sectional Study. *International Journal of Health Sciences and Research*. 2018;8(5):129–34.
35. Vijayabala GS, Others. Prevalence of Oral Mucosal Abnormalities in Dental Patients in Tamil Nadu. *WORLD*. 2016;7(4):186–8.
36. Kovač-Kavčič M, Skalerič U. The prevalence of oral mucosal lesions in a population in Ljubljana, Slovenia. *J Oral Pathol Med*. 2000;29(7):331–5.
37. Macigo FG, Mwaniki DL, Guthua SW. Prevalence of oral mucosal lesions in a Kenyan population with special reference to oral leukoplakia. *East Afr Med J*. 1995;72(12):778–82.