

Analysis of Root Stumps in Middle Aged Group

Sarojini Ramya Pillay¹, Dhanraj Ganapathy²,

¹Research Associate, Dental Research Cell, ²Professor and head, Department of Prosthodontics, Remmiya Mary Varghese, ³Senior lecturer, Department of Orthodontics, Saveetha Dental College and Hospitals, Saveetha Institute of Medical and Technical Sciences, Saveetha University, Chennai

Abstract

Tooth extraction is one of the dental treatments which should be considered the last option. A decrease in the number of teeth may result in poor dietary habits and deterioration of quality of life. The number of extracted teeth can serve as an indicator of socio-economic and oral hygiene level. Extraction of permanent teeth is performed for several reasons including dental caries, periodontal disease, orthodontic reasons, impacted teeth and root stumps. To assess the prevalence of root stumps in middle aged in Chennai A retrospective cross-sectional study was conducted using the patient records from the Department of Oral maxillofacial surgery, Saveetha Dental College, Chennai from February 2019 to February 2020, and patients who had root stumps were selected by nonprobability sampling. Data was collected and then subjected to statistical analysis. Microsoft Excel/2016 data spreadsheet was used and later exported to the Statistical Package for Social Science for Windows (version 20.0, SPSS Inc., Chicago Ill., USA). The prevalence of root stumps was more in males and age groups of 50-55 years showed maximum root stumps. There is no significant difference between gender and the number of root stumps in each patient $P=0.562$. The study concluded that the prevalence of root stumps in the middle age group seems to be high when compared to other literature. Considering the limitations of this study extensive research needs to be done to find the prevalence of root stumps in other populations and to spread awareness among the public about root stumps which are in situ.

Keywords: Extraction; root caries; root stumps; dental caries

Introduction

Root stumps refers to the partial root structure that remains in the jaw. Root stumps can be retained both in dentulous and edentulous patients as a preventive measure to preserve the alveolar ridge resorption.^{1,2} However, retained roots also have the propensity to cause pain and discomfort^{3,4,5} to patients and can be a source of infection, especially if fractured during the extraction of non-vital teeth⁶⁻⁹. Retained roots can complicate the fabrication of complete dentures as they

can potentially cause pain and numbness if the denture base or flange impinges close to the root fragment, either immediately^{10,11} or after several years due to alveolar ridge resorption.^{12,13,14} Historically, in the 1920s, there was a common agreement that all root stumps should be removed, and if not removed it was believed that it can cause damage to patients which would lead to pain, infection and cyst development^{15,16}.

Recently, Studies which carried out on the prevalence of retained roots¹⁷⁻²⁰ have shown that the majority of retained root stumps cause no harm to patients and are only detected as incidental radiographic findings.^{21,22} Under certain circumstances, the study reveals that root fragments could successfully remain in situ with normal healing taking place²³ together with the formation of a cementum layer on the dentine.

Loss of teeth is an unavoidable part of human life which affects many people physiologically and also

Corresponding Author:

Dhanraj Ganapathy

Professor and Head, Department of Prosthodontics
Saveetha Dental College and Hospitals
Saveetha Institute of Medical and Technical Sciences
Saveetha University, Chennai -77
Email: dhanraj@saveetha.com

affects the aesthetic. Tooth extraction remains a major cause of commonly performed procedures in developing countries.^{24,25} Tooth loss has significant socioeconomic, quality of life, general health, and psychological consequences.^{26,27} Tooth loss has become a global public health concern of immense proportion.^{28,29} Despite being preventable, dental caries and periodontal disease remain the most common reasons for tooth extraction, especially developing nations.^{30,31,32}

The reasons for tooth extraction and the number of teeth extracted in a population have been linked to the oral hygiene, level of education, socioeconomic status, and individual quality of life.^{33,34} Degree of urbanization has also been found to affect the pattern of tooth extractions.^{35,36} Moreover, oral disease and its etiological factors exhibit regional variations.^{37,38} The main aim of the study is to assess the Prevalence of root stumps in the middle ages group in Chennai as there is no study on this literature.

Materials and Methods

Study Design And Setting

This retrospective study examined the records of patients during June 2019-April 2020 who were diagnosed with root stumps at Saveetha Dental College, Chennai. Ethical approval was obtained from the Institutional Ethics Committee. The study population included patients who had root stumps and were selected by means of non-probability sampling. Patients with mental or physical disability were excluded from the study.

Data Collection

Patient record was reviewed and analyzed at Saveetha Dental College and was used to identify 93 patients in the hospital database diagnosed with root stumps. Relevant data such as patient age, sex and tooth number was recorded. Repeated patient records and incomplete records were excluded. Data was verified by an external reviewer.

Statistical Analysis

Data was recorded in Microsoft Excel/2016 (Microsoft office 10) and later exported to the Statistical Package for Social Science for Windows (version 20.0,

SPSS Inc., Chicago Ill., USA) and subjected to statistical analysis. Chi square test was employed with a 5% level of significance .

Results and Discussion

The final dataset consisted of 93 patients of Indian origin diagnosed with root stumps. The mean age root stump was 44.99 years (standard deviation = 6.061 years). The age group associated with greatest prevalence of root stumps was 50-55 years (50.5% N=47), followed by 35-40 (31.2 % N=29) and the least was 41-45 (18.3% N=17) shown in [Figure 1] Most of the patients who underwent extraction was 41.9% (N=39) were female and 58.1. % (N=54) were males showing a male dominance in patients having root stumps [Figure 2]. A total of 52 male patients have 0-5 root stumps present whereas 35 female patients had 0-5 root stumps present. 1 Male patients reported to the clinic with 5-10 root stumps present whereas 3 female patients reported to the clinic with 5-10 root stumps. One of each male and female had above 10 root stumps present. There was no significant difference between the number of root stumps and age P value= 0.946 [Figure 3]. Root stumps were commonly seen in the maxilla of tooth 28 and 17 which had 19 root stumps in total. The least was seen in tooth 12 and 34 which has 2 each in total shown in Figure 4

The data for this retrospective study was based on residents of Chennai seeking treatment at Saveetha Dental College. Currently, there are no existing studies investigating the prevalence of root stumps present in the middle age group in Chennai. Since all the data available was included without a sorting process, no bias was expected in the selection of patients. The current study aims to shed light on the current scenario of root stumps present in many patients which is being neglected. Despite progress in various communication and technology in today's world there is still a lack of awareness and knowledge on root stumps among common people.

In the study conducted by M.P. Santhosh Kumar et al³⁹ There was an increase in number of root stumps in the age group of 34-40 years (N=42) old then followed by 41-44 (N=40) and the least being 50-55 year-old (N=38) this is contraindicating to this study as the age group in the current study is associated with greatest

number of root stumps in 50-55 years (50.5% N= 47) possible reason could be change in socioeconomic status and oral hygiene practice

According to M.P. Santhosh Kumar et al ³⁹ the study reported with 28 males having root stumps and 26 female having root stumps. In the current study males have more root stumps than female this is in accordance to the study because this study was done in the same region. However, a study done by Rashmi Saikhedkar et al ⁴⁰ in a rural dental College in Indore reported that 182 root stumps were present in a male patient and 193 root stumps present in female this is contradictory to the current study as male (N=54) has more root stumps than female (N= 39) the possible reason to this could be attributed to more of awareness and concern regarding facial aesthetics on the part of females.

According to, Simpson et al he examined a number of retained roots in humans and suggested that root

fragments, which were originally unaffected, could be safely left in position ^{41,42} Preserving the teeth or the roots preserves the periodontal ligament ⁴³ similarly Prabhu et al ¹ reported 64% of dentist in study thinks that retained root without any pathology can preserve periodontal ligament thus this justifies as to why there is a high incidence in of root stumps present in one individual where a total of 52 male patients have 0-5 root stumps present whereas 35 female patients had 0-5 root stumps present in the current study.

In the present study molar had the majority of the root stumps. In the previous study done by M.P. Santhosh Kumar et al ³⁹ molars were the teeth that had to be extracted more as compared to other teeth the main reason is due to early eruption of teeth predisposing to the environment conditions compared to the other teeth erupting later in which periodontitis can be seen at older age. Most of the studies claim different findings and results because of the type of methodology of the study and socio economic status of the patient.

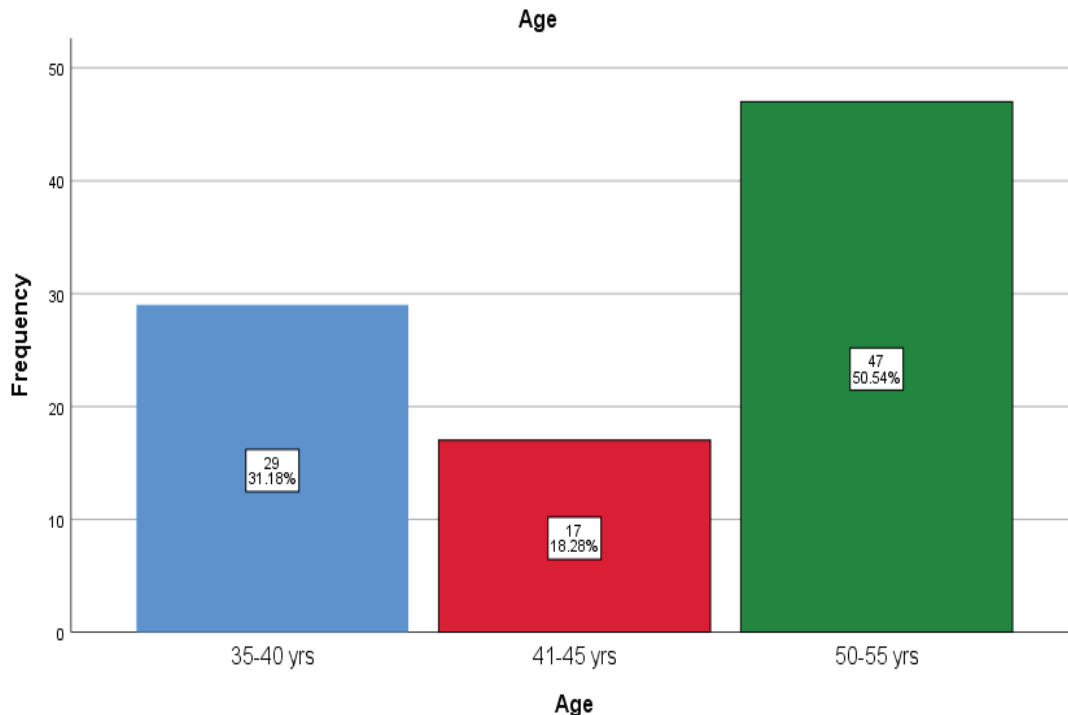


Figure 1 : Bar chart showing the distribution of age where X axis representing age and Y axis representing frequency. 50.5% belonging to the age group of 50-55 years (green), 35-40 (blue) (31.2 %) and 41-45 years (red) (18.3%)

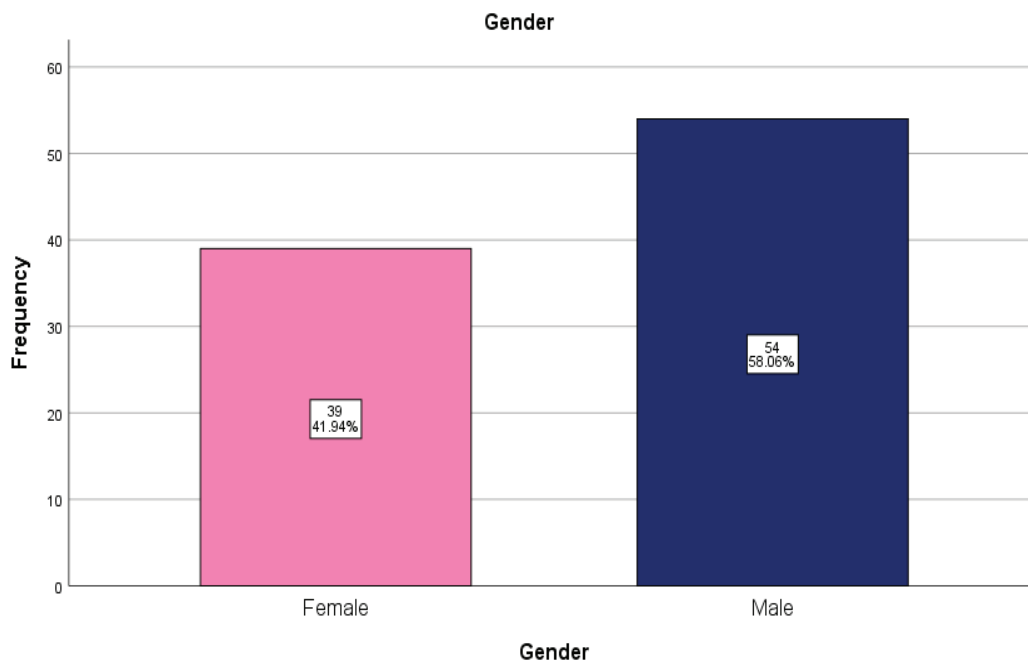


Figure 2 : Bar chart showing the distribution of gender where X axis representing gender and Y axis representing frequency.41.9% were female(pink) and 58.1. % males (dark blue)

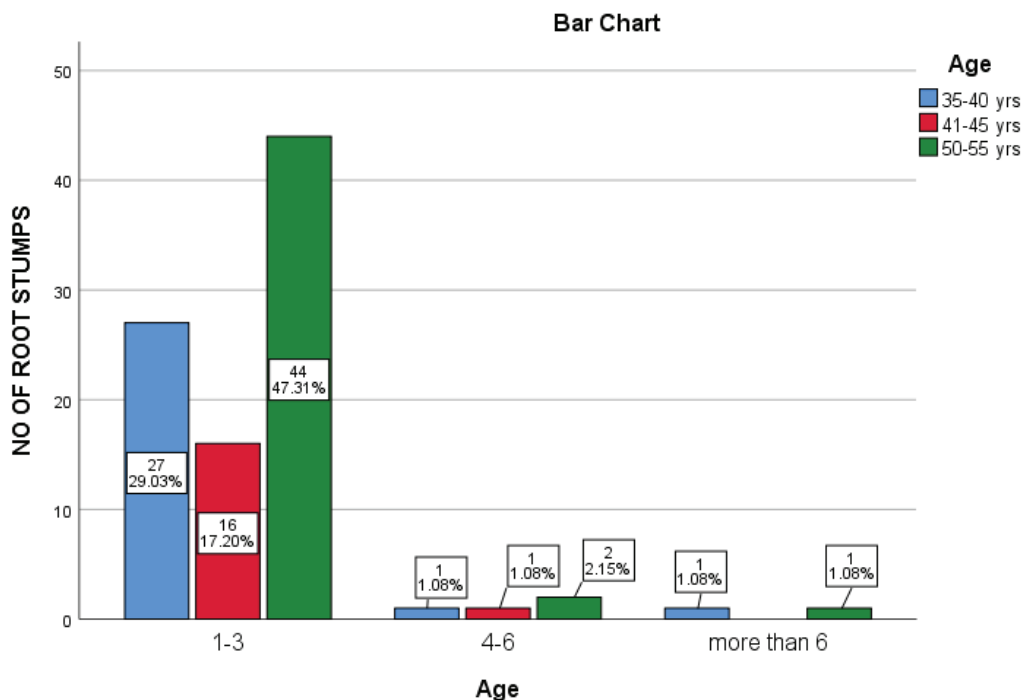


Figure 3: Bar chart showing association between number of root stumps in a patient and age. X axis representing number of root stumps in a patient and Y axis representing frequency. Blue colour denotes 35-40 years, red denotes 41-45 years and green denotes 50-55 years. Majority of the patient’s with age between 50-55 years (green) have 1-3 root stumps. However, there is no association between the number of root stumps and age found statistically. Pearson chi square value was 0.742 and P value was 0.496(>0.05).

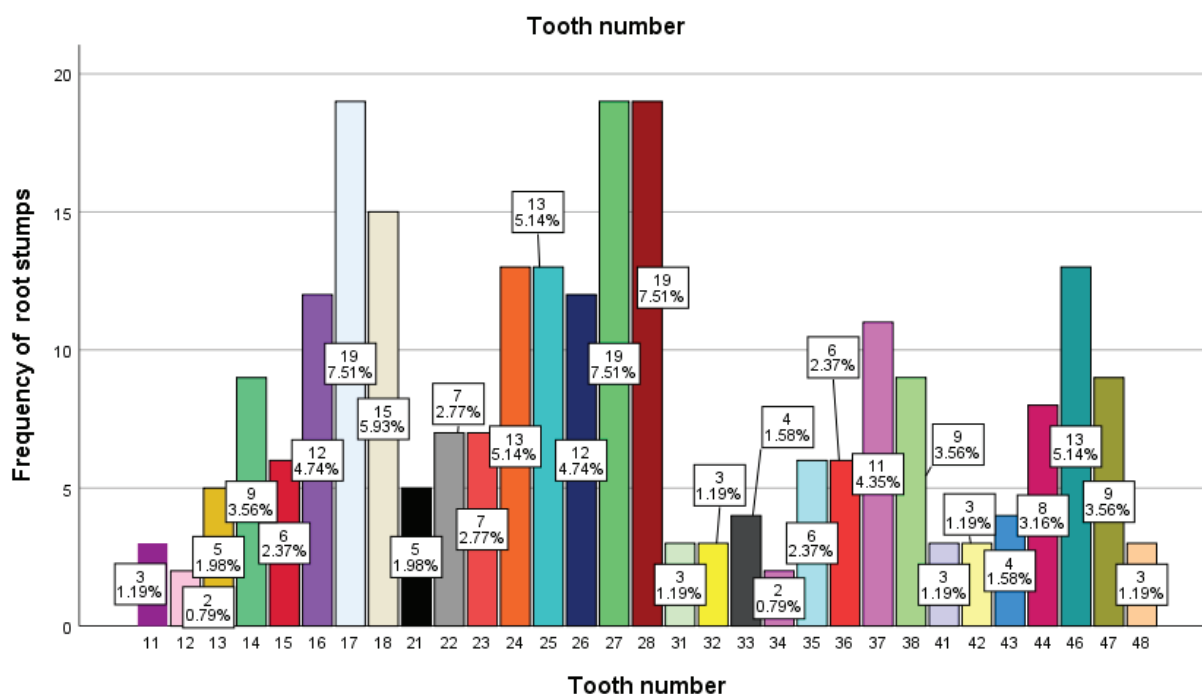


Figure 4: Bar chart showing distribution of root stumps in a patient. X axis represents the tooth number and Y axis represents frequency of root stumps. Majority of the root stumps was seen in tooth 28 (dark brown) with 7.51% and 17 (light blue) with 7.51% which had 19 root stumps in total. The least was seen in tooth 12 (light pink) with 0.79% and 34 (pink) which has 0.79%. This shows that the upper arch (from tooth number 18 to 28) had more root stumps than the lower arch (from tooth number 38 to 48).

Conclusion

Within the limitations of this study, it was found that the prevalence of root stumps in the middle age group seems to be higher when compared to literature from other regions. Considering ill effects of root stumps, it can be concluded that there exists a paramount need for more extensive research to find the prevalence of root stumps in all the age groups and in a different study population.

Conflict of Interest: Authors have no known conflict associated with this study

Acknowledgement : The authors acknowledge and thank Saveetha Dental College and Hospitals for the support.

Source of Funding: Self

Ethical Clearance: It is taken from “Saveetha Institute Human Ethical Committee” (Ethical Approval Number- SDC/SIHEC/2020/DIASDATA/0619-0320)

References

- Schuch C, de Moraes AP, Sarkis-Onofre R, Pereira-Cenci T, Boscatto N. An alternative method for the fabrication of a root-supported overdenture: a clinical report. *J Prosthet Dent* [Internet]. 2013 Jan;109(1):1–4. Available from: [http://dx.doi.org/10.1016/S0022-3913\(13\)00013-9](http://dx.doi.org/10.1016/S0022-3913(13)00013-9)
- Ajay R, Suma K, Ali S, Sivakumar JK, Rakshagan V, Devaki V, et al. Effect of surface modifications on the retention of cement-retained implant crowns under fatigue loads: An In vitro study [Internet]. Vol. 9, *Journal of Pharmacy And Bioallied Sciences*. 2017. p. 154. Available from: http://dx.doi.org/10.4103/jpbs.jpbs_146_17
- Park S-H, Sorensen WP, Wang H-L. Management and prevention of retrograde peri-implant infection from retained root tips: two case reports. *Int J Periodontics Restorative Dent* [Internet]. 2004 Oct;24(5):422–33. Available from: <http://dx.doi.org/10.11607/prd.00.0604>
- Herd JR. The retained tooth root [Internet]. Vol. 18, *Australian Dental Journal*. 1973.

- p. 125–31. Available from: <http://dx.doi.org/10.1111/j.1834-7819.1973.tb03448.x>
5. Kannan A, Venugopalan S. A systematic review on the effect of use of impregnated retraction cords on gingiva. *Research Journal of Pharmacy and Technology* [Internet]. 2018;11(5):2121–6. Available from: <http://www.indianjournals.com/ijor.aspx?target=ijor:rjpt&volume=11&issue=5&article=078>
 6. Plata RL, Kelln EE. Intentional retention of vital submerged roots in dogs [Internet]. Vol. 42, *Oral Surgery, Oral Medicine, Oral Pathology*. 1976. p. 100–8. Available from: [http://dx.doi.org/10.1016/0030-4220\(76\)90036-0](http://dx.doi.org/10.1016/0030-4220(76)90036-0)
 7. Whitaker DD, Shankle RJ. A study of the histologic reaction of submerged root segments. *Oral Surg Oral Med Oral Pathol* [Internet]. 1974 Jun;37(6):919–35. Available from: [http://dx.doi.org/10.1016/0030-4220\(74\)90445-9](http://dx.doi.org/10.1016/0030-4220(74)90445-9)
 8. Kramer S. An unexpected adverse reaction due to a retained root. *N Y State Dent J* [Internet]. 1983 Dec;49(10):768–70. Available from: <https://www.ncbi.nlm.nih.gov/pubmed/6581444>
 9. Ganapathy DM, Kannan A, Venugopalan S. Effect of Coated Surfaces influencing Screw Loosening in Implants: A Systematic Review and Meta-analysis [Internet]. Vol. 8, *World Journal of Dentistry*. 2017. p. 496–502. Available from: <http://dx.doi.org/10.5005/jp-journals-10015-1493>
 10. Ganapathy D, Sathyamoorthy A, Ranganathan H, Murthykumar K. Effect of Resin Bonded Luting Agents Influencing Marginal Discrepancy in All Ceramic Complete Veneer Crowns. *J Clin Diagn Res* [Internet]. 2016 Dec;10(12):ZC67–70. Available from: <http://dx.doi.org/10.7860/JCDR/2016/21447.9028>
 11. Caplin RL. Oral surgery: problems. *Br Dent J* [Internet]. 1989 Mar 11;166(5):171–7. Available from: <http://dx.doi.org/10.1038/sj.bdj.4806759>
 12. Nairn RI. Interference with the function of the inferior dental nerve by a root fragment. Report of a case. *Oral Surg Oral Med Oral Pathol* [Internet]. 1973 Aug;36(2):188–91. Available from: [http://dx.doi.org/10.1016/0030-4220\(73\)90235-1](http://dx.doi.org/10.1016/0030-4220(73)90235-1)
 13. Venugopalan S, Ariga P, Aggarwal P, Viswanath A. Magnetically retained silicone facial prosthesis. *Niger J Clin Pract* [Internet]. 2014 Mar;17(2):260–4. Available from: <http://dx.doi.org/10.4103/1119-3077.127575>
 14. Subasree S, Murthykumar K, Others. Effect of Aloe Vera in Oral Health-A Review. *Research Journal of Pharmacy and Technology* [Internet]. 2016;9(5):609–12. Available from: <http://www.indianjournals.com/ijor.aspx?target=ijor:rjpt&volume=9&issue=5&article=028>
 15. Heidbrink JA. Necessity for Removal of All Broken-Off Root Tips. *J Dent Res* [Internet]. 1921 Dec 1;3(4):389–90. Available from: <https://doi.org/10.1177/00220345210030040501>
 16. Vijayalakshmi B, Ganapathy D. Medical management of cellulitis. *Research Journal of Pharmacy and Technology* [Internet]. 2016; 9(11):2067–70. Available from: <http://www.indianjournals.com/ijor.aspx?target=ijor:rjpt&volume=9&issue=11&article=051>
 17. Dachi SF, Howell FV. A survey of 3,874 routine full-mouth radiographs: II. A study of impacted teeth. *Oral Surg Oral Med Oral Pathol* [Internet]. 1961 Oct 1;14(10):1165–9. Available from: <http://www.sciencedirect.com/science/article/pii/0030422061902043>
 18. Kharat DU, Saini T. Embedded root fragments in completely and partially edentulous jaws. *Saudi Dental Journal* [Internet]. 1991 [cited 2020 Jun 10];3(1):8–12. Available from: https://inis.iaea.org/search/search.aspx?orig_q=RN:41094347
 19. Sumer AP, Sumer M, Güler AU, Biçer I. Panoramic radiographic examination of edentulous mouths. *Quintessence Int* [Internet]. 2007 Jul;38(7):e399–403. Available from: <https://www.ncbi.nlm.nih.gov/pubmed/17694203>
 20. Bremner VA, Grant AA. A radiographic survey of edentulous mouths. *Aust Dent J* [Internet]. 1971 Feb;16(1):17–21. Available from: <http://dx.doi.org/10.1111/j.1834-7819.1971.tb00975.x>
 21. Basha FYS, Ganapathy D, Venugopalan S. Oral Hygiene Status among Pregnant Women [Internet]. Vol. 11, *Research Journal of Pharmacy and Technology*. 2018. p. 3099. Available from: <http://dx.doi.org/10.5958/0974-360x.2018.00569.3>
 22. Ashok V, Suvitha S. Awareness of all ceramic restoration in rural populations. *Research Journal of Pharmacy and Technology* [Internet]. 2016;9(10):1691–3. Available from: <http://www.indianjournals.com/ijor.aspx?target=ijor:rjpt&volume=9&issue=10&article=039&type=pdf>

23. Glickman I, Pruzansky S, Ostrach M. The healing of extraction wounds in the presence of retained root remnants and bone fragments. *Am J Orthod* [Internet]. 1947 Apr;33(4):263–83. Available from: [http://dx.doi.org/10.1016/0096-6347\(47\)90063-x](http://dx.doi.org/10.1016/0096-6347(47)90063-x)
24. Saheeb BD, Sede MA. Reasons and pattern of tooth mortality in a Nigerian Urban teaching hospital. *Ann Afr Med* [Internet]. 2013 Apr;12(2):110–4. Available from: <http://dx.doi.org/10.4103/1596-3519.112402>
25. Duraisamy R, Krishnan CS, Ramasubramanian H, Sampathkumar J, Mariappan S, Navarasampatti Sivaprakasam A. Compatibility of Nonoriginal Abutments With Implants: Evaluation of Microgap at the Implant-Abutment Interface, With Original and Nonoriginal Abutments. *Implant Dent* [Internet]. 2019 Jun;28(3):289–95. Available from: <http://dx.doi.org/10.1097/ID.0000000000000885>
26. Jafarian M, Etebarian A. Reasons for extraction of permanent teeth in general dental practices in Tehran, Iran. *Med Princ Pract* [Internet]. 2013;22(3):239–44. Available from: <http://dx.doi.org/10.1159/000345979>
27. Jyothi S, Robin PK, Ganapathy D, Others. Periodontal health status of three different groups wearing temporary partial denture. *Research Journal of Pharmacy and Technology* [Internet]. 2017;10(12):4339–42. Available from: <http://www.indianjournals.com/ijor.aspx?target=ijor:rjpt&volume=10&issue=12&article=046>
28. Taiwo OA, Sulaiman AO, Obileye MF, Akinshipo A, Uwumwose AO, Soremi OO. Patterns and reasons for childhood tooth extraction in Northwest Nigeria. *J Clin Pediatr Dent* [Internet]. 2014 Sep 1 [cited 2020 Jun 10];2(3):83. Available from: <http://www.jpediatrdent.org/article.asp?issn=2321-6646;year=2014;volume=2;issue=3;spage=83;epage=87;aulast=Taiwo;type=0>
29. Jain A, Ranganathan H, Ganapathy D. Cervical and incisal marginal discrepancy in ceramic laminate veneering materials: A SEM analysis [Internet]. Vol. 8, *Contemporary Clinical Dentistry*. 2017. p. 272. Available from: http://dx.doi.org/10.4103/ccd.ccd_156_17
30. Alesia K, Khalil HS. Reasons for and patterns relating to the extraction of permanent teeth in a subset of the Saudi population. *Clin Cosmet Investig Dent* [Internet]. 2013 Jul 30;5:51–6. Available from: <http://dx.doi.org/10.2147/CCIDE.S49403>
31. Selvan SR, Ganapathy D. Efficacy of fifth generation cephalosporins against methicillin-resistant *Staphylococcus aureus*-A review. *Research Journal of Pharmacy and Technology* [Internet]. 2016;9(10):1815–8. Available from: <http://www.indianjournals.com/ijor.aspx?target=ijor:rjpt&volume=9&issue=10&article=068>
32. Jain AR, Nallaswamy D, Ariga P, Ganapathy DM. Determination of correlation of width of maxillary anterior teeth using extraoral and intraoral factors in Indian population: A systematic review. *World J Dent* [Internet]. 2018;9:68–75. Available from: https://www.researchgate.net/profile/Ashish_Jain52/publication/323548671_Determination_of_correlation_of_width_of_maxillary_anterior_teeth_using_extraoral_and_intraoral_factors_in_indian_population_A_systematic_review/links/5b00347c0f7e9be94bd8caf9/Determination-of-correlation-of-width-of-maxillary-anterior-teeth-using-extraoral-and-intraoral-factors-in-indian-population-A-systematic-review.pdf
33. Dixit LP, Gurung CK, Gurung N, Joshi N. Reasons underlying the extraction of permanent teeth in patients attending Peoples Dental College and Hospital. *Nepal Med Coll J* [Internet]. 2010 Dec;12(4):203–6. Available from: <https://www.ncbi.nlm.nih.gov/pubmed/21744759>
34. La Torre G, Romeo U, Iarocci G, Brugnoletti O, Semyonov L, Galanakis A, et al. Socio-demographic inequalities and teeth extraction in the last 12 months in Italy. *Ann Stomatol* [Internet]. 2014 Oct;5(4):131–5. Available from: <https://www.ncbi.nlm.nih.gov/pubmed/25774248>
35. Luan WM, Baelum V, Chen X, Fejerskov O. Tooth mortality and prosthetic treatment patterns in urban and rural Chinese aged 20-80 years. *Community Dent Oral Epidemiol* [Internet]. 1989 Oct;17(5):221–6. Available from: <http://dx.doi.org/10.1111/j.1600-0528.1989.tb00620.x>
36. Varenne B, Petersen PE, Ouattara S. Oral health behaviour of children and adults in urban and rural areas of Burkina Faso, Africa. *Int Dent J* [Internet]. 2006 Apr;56(2):61–70. Available from: <http://dx.doi.org/10.1111/j.1875-595x.2006.tb00075.x>
37. Odai CD, Azodo CC, Ezeja EB, Obuekwe ON. Reasons for exodontia in rural Nigerian children. *Odontostomatol Trop* [Internet]. 2010 Dec;33(132):19–24. Available from: <https://www.>

ncbi.nlm.nih.gov/pubmed/21510148

jpfa.2014.02.007

38. Ashok V, Nallaswamy D, Benazir Begum S, Nesappan T. Lip Bumper Prosthesis for an Acromegaly Patient: A Clinical Report. *J Indian Prosthodont Soc* [Internet]. 2014 Dec;14(Suppl 1):279–82. Available from: <http://dx.doi.org/10.1007/s13191-013-0339-6>
39. Santhosh Kumar MP. Evaluation of various factors for extraction of permanent teeth in a dental college. 2016 Jan 1 [cited 2020 Jun 10];8(1):40–6. Available from: <http://dx.doi.org/>
40. Saikhedkar R, Neema HC. Evaluation of various factors for extraction of teeth in a rural dental college [Internet]. Vol. 28, *Journal of Pierre Fauchard Academy (India Section)*. 2014. p. 28–33. Available from: <http://dx.doi.org/10.1016/j.jpfa.2014.02.007>
41. Morrow RM, Feldmann EE, Rudd KD, Trovillion HM. Tooth-supported complete dentures: an approach to preventive prosthodontics. *J Prosthet Dent* [Internet]. 1969 May;21(5):513–22. Available from: [http://dx.doi.org/10.1016/0022-3913\(69\)90073-0](http://dx.doi.org/10.1016/0022-3913(69)90073-0)
42. Dodge CA. Prevention of complete denture problems by use of “overdentures.” *J Prosthet Dent* [Internet]. 1973 Oct;30(4 Pt 1):403–11. Available from: [http://dx.doi.org/10.1016/0022-3913\(73\)90161-3](http://dx.doi.org/10.1016/0022-3913(73)90161-3)
43. Thayer HH. Overdentures and the periodontium. *Dent Clin North Am* [Internet]. 1980 Apr;24(2):369–77. Available from: <https://www.ncbi.nlm.nih.gov/pubmed/6988245>