

*Type of Manuscript: Original Study*

# Analysis Into Extra Oral Features of Completely Edentulous Patients Pre and Post Complete Denture Treatment

Ashwin Kumar.S.P<sup>1</sup>, Suresh Venugopalan<sup>2</sup>, Sreedevi Dharman<sup>3</sup>

<sup>1</sup>Research Associate, Dental Research Cell, <sup>2</sup>Reader, Department of Prosthodontics, <sup>3</sup>Reader, Dept. of Oral Medicine and Radiology, Saveetha Dental College and Hospital, Saveetha Institute of Medical and Technical Sciences (SIMATS), Chennai, India

## Abstract

**Background** :Edentulism has been a serious public health problem in industrialized countries due to the age of the population , life quality and nutrition intake are impaired . Which is restored by the use of complete dentures. **Aim** : To assess extra oral features of complete edentulous patients pre and post complete denture treatment .**Materials and method** :Data of complete denture patients was screened and collected from the dental archives database and assessed the documentation evidences.**Results** :According to the study in Complete denture fabrication BPS showed aesthetically better post operative extra oral features compared to the conventional method (p value < 0.05 significant [chi-square test]).**Conclusion** :Within the limitation of the study ,it is evident that BPS has shown better post operative aesthetic results compared to that of the pre op than the conventional CD. The extra oral features of a complete denture patient are enhanced while using a BPS type of a complete denture.

**Keyword** : *Aesthetic; extra oral features; nasolabial fold; facial wrinkles; lip support; BPS; conventional.*

## Introduction

Edentulism has been a serious public health problem in industrialized countries due to population aging and in developing countries due to poor oral care.<sup>1</sup> The life quality and nutrition intake are impacted due to edentulism.<sup>2</sup> Complete dentures are the main choice for edentulous patients. Despite an anticipated decrease in the age-specific rates of edentulism, the demand for complete dentures will continuously increase in the next decades.<sup>3-5</sup>

Currently, complete dentures are mainly designed and fabricated using conventional methods, which

involve a broad series of clinical and laboratory procedures.<sup>6</sup> To obtain a complete denture , edentulous patients have to makeup for a minimum of 5 sightings, including preliminary impressions, final impressions, recording jaw relations, trial placement of wax denture, and placement/insertion of complete dentures. These clinical and laboratory procedures are performed to achieve good rehabilitation. But it is very challenging to ensure the quality for the designing and fabrication of dentures due to its complex fabrication techniques.

Achieving aesthetics is a foremost objective in complete denture fabrication.<sup>7-9</sup> The overall appearance of the denture is more important , but only to the extent that it contributes to an aesthetic appearance and function of the face and lips. It is essential to identify the patients expectations and to explain to him or her the limitations and possibilities of fabrication of aesthetic and functional satisfactory restorations .<sup>10</sup> Patients' appreciation of their conventional complete dentures might be affected by the quality of the dentures.<sup>11</sup>

---

### Corresponding Author:

#### Suresh Venugopalan

Reader, Department of Prosthodontics,  
Saveetha Dental College and Hospitals,  
Saveetha Institute of Medical and Technical  
Sciences(SIMATS), Saveetha University,  
Chennai 600 077, Tamilnadu, India  
Mail Id : suresh@saveetha.com,  
Ph no. : +91 95431 92858.

A pleasant smile is an expression of joy. It is extraordinarily a human signal that is not normal for the scowl of lower primates.<sup>12</sup> It is dentist's obligation to preserve, enhance or create a pleasing smile through dental treatment without impairing function.<sup>13</sup> The dentition and how it influences the formation of a pleasing smile is extremely important in the emotional development of the individual.<sup>14</sup> Characterized dentures plays a vital role in improving one's confidence.<sup>15</sup>

The Biofunctional Prosthetic System (BPS) is used for the treatment of edentulous and partially edentulous patients. Today, the use of clinical protocols and simple, reliable treatment methods that can be easily adjusted to the needs of the patient is of prime importance and usually preferred by both patients and dentists .<sup>16</sup>

It is a system consisting of a series of steps from impression making, bite registration, Set up of denture teeth, polymerization and finishing to delivery that are carried out according to the pre defined BPS procedures using Ivoclar Vivadent's devices and materials. The BPS system provides the dentist a simple, time saving procedure based on gnathological principles of the masticatory muscles . All the steps, procedures and materials are coordinated with each other to achieve ease of denture construction.<sup>17</sup>

Complete denture fabrication must be done considering both the extraoral ( facial muscle ) and intra oral factors .<sup>18,19</sup> Consider the periodontal status of the patient and explore for possibilities of implant which gives better aesthetic results on a longer run<sup>20,21,22,23</sup> . Other modified complete dentures such as tooth supported or implant supported over dentures, magnetic retainer for better retention can also be made use for a better aesthetics .<sup>24,25,26,27,28</sup>

There are various studies supporting the denture maintenance and the infection that can possibly be caused due to the lack of maintenance .<sup>29,30,31,32</sup>

Most of the literature takes into account only the oral health and satisfaction perceived by the patient's prosthetic carrier, however, an investigation of the causes and major failure factors is necessary . Conversely, a small number of researchers sought a relationship between prosthetic quality and patient satisfaction.

This research is done to assess the extra oral features of edentulous patient pre and post treatment of complete denture (BPS/Conventional).

## Materials and Method

The present study is done by screening the patients digital case sheets. The search for digital case sheets was from June 2019 to February 2020. The records searched close to 4068 reporting to clinics with the complaint of multiple missing teeth in upper and lower arch. The search was narrowed down for edentulous condition in upper and lower arch. The search led to 466 patients undergoing complete denture treatments. Further the digital documentation was evaluated for extra oral facial details at the diagnostic stage and post treatment stage. The details were screened by 2 expert reviewers. Those undergoing complete denture treatments and with adequate documentation details were involved in the study. All the complete denture patients were taken into the study with no particular age limit . Three facial features were taken into consideration for the study both pre op and post operative as follows and measured accordingly : nasolabial fold (0-prominent , 1- not so prominent ), Adequate lip support (1-adequate , 0- more or less), Facial wrinkles (0- present 1- absence) .This study was done to estimate- extraoral feature of complete denture patients undergone either BPS or conventional technique denture construction. The data was screened and relevant data was subjected to statistical analysis. Chi square test is used for statistics . Statistics software used is SPSS version 26 by IBM. Independent variables are age, gender, extra oral changes ,different denture construction methods.

## Results & Discussion

According to the study in Complete denture fabrication BPS showed aesthetically better post operative extra oral features compared to the conventional method. On assessment of complete denture and nasolabial fold post operative shows that the nasolabial fold is not so prominent in BPS (58.8%) - compared to conventional method.( Graph 1 ) (p<0.05 significant). On assessment of complete denture and facial wrinkles post operative , where the facial wrinkles were measured only on lower 2/3rd as the complete denture affects the facial change only on the lower third of the facial creases on which BPS(60.8%) showed better results compared to

conventional method.( Graph 2 ) ( $p > 0.05$  Insignificant). On assessment of complete denture and adequate lip support postoperative where the post operative of adequate lip support in BPS(88.2%) showed better results compared to conventional method.( Graph 3 )(p value  $< 0.05$  significant [chi-square test]).

Facial ageing is an inevitable fact of life. Our genes lead our body through a series of changes ranging from growth and development to maturation, ageing and finally death. This process appears to be genetically controlled but also influenced by lifestyle and environment.<sup>33</sup>

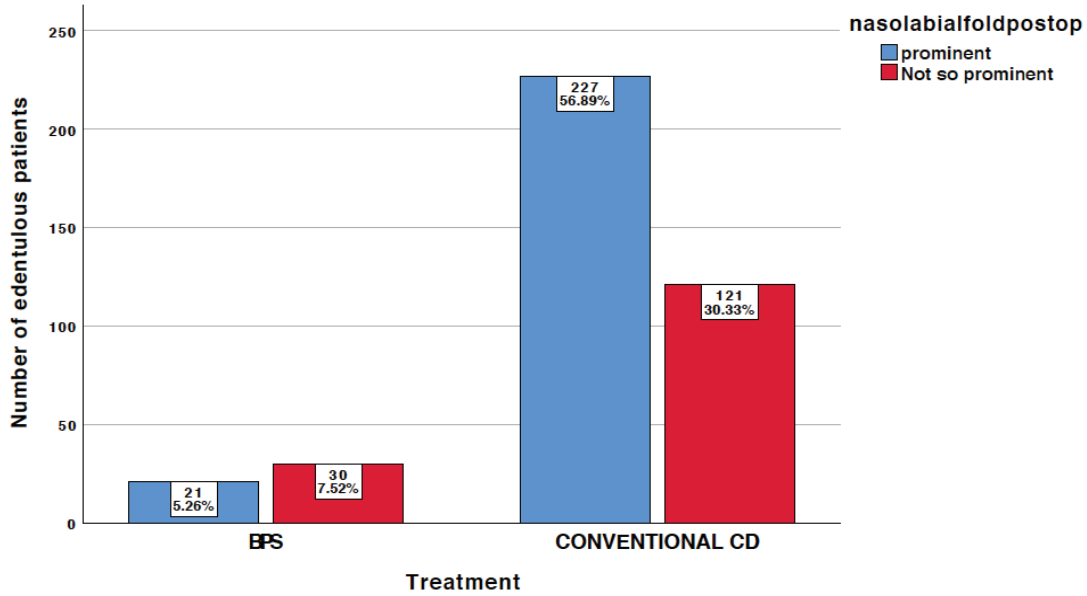
The cheeks are less mobile than the lips and are supported on three sides by the zygoma above, the mandible below, and the parotid gland overlying the masseter muscle in the posterior region . Additional is provided by the subcutaneous fat and buccal fat tissues , and this support is responsible for the soft, rounded contours of the cheeks in the lower third of the face.<sup>34</sup>

The buccal fat pads persist for a longer period compared to subcutaneous fat, even in patients with extreme thin and weak patients. The anterior parts of the cheeks are supported by the muscular framework converging into the modioli and are subject to more changes . On loss of posterior teeth, the cheek tends to collapse on varying degrees and moving medially to the laterally expanding tongue. The loss of anterior teeth and the subsequent loss of vertical dimension affects the cheek stability. Losses of subcutaneous fat and elasticity of connective tissue produces hollow cheeks.<sup>35,36</sup> As said earlier, loss of all the teeth is a major and an irreversible loss for the patients . So there is much concern that in completely edentulous patients , restoring aesthetics is a must by considering the extraoral features such as nasolabial fold ,lip support and facial wrinkle both in the conventional and BPS method of complete

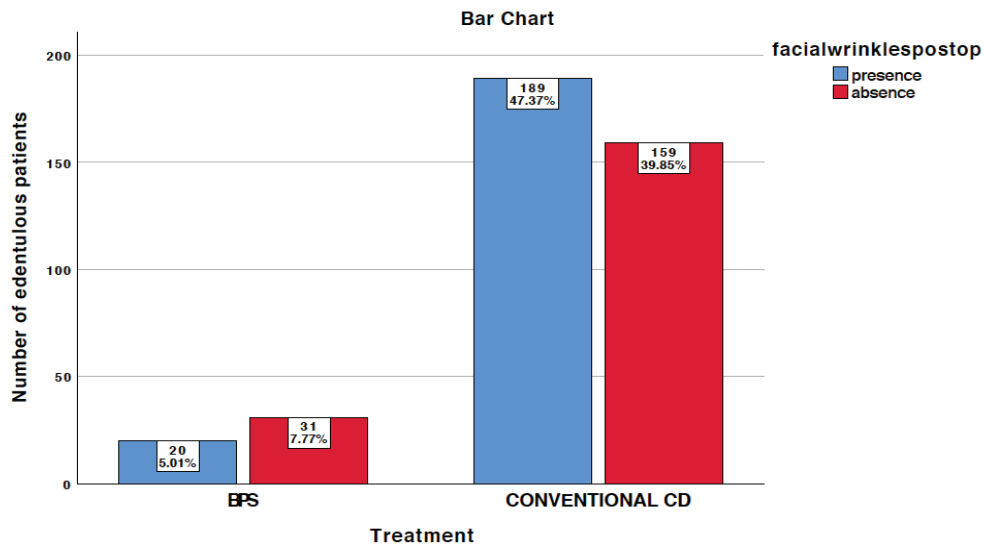
denture fabrication. It is a dentist's duty to restore the aesthetics and give confidence to the patient .

In an edentulous patients due to Complete loss of teeth the extra oral anatomical muscles of facial expressions loses their support and tonicity where the complete denture (BPS /conventional) will a important role in provide support to the facial muscles .In of the aesthetic cases BPS dentures are preferred as it has much lesser sitting and precision on fabrication aiding the better quality and confidence that the patients require.<sup>37</sup> In various other studies they have suggested to use radiographs to recorded changes of the facial muscle tension and change in the vertical dimension for edentulous patients. Electromyography which is excellent for diagnostic aid of muscle function and a reproducible method in detecting changes in electrical muscle activity has been suggested to be used to identify changes in isometric muscle tension.<sup>38-40</sup>

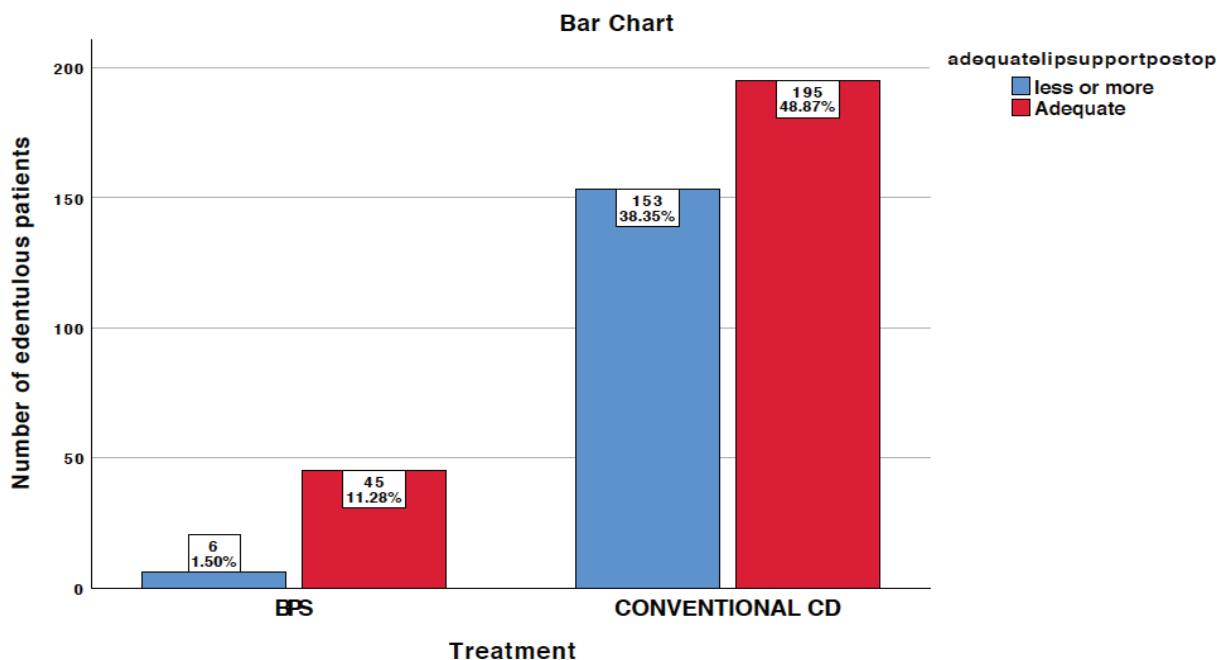
In edentulous patients basically they have difficulties with mastication and speech which is resolved by denture that gives better lip support and BPS is preferred.<sup>41</sup> Facial wrinkles were better resolved when a BPS denture was used compared to a conventional as far as the denture meets most exacting requirements and accuracy.<sup>42</sup> Not all cases are suitable for a BPS denture even though they have better stability and retention ie; better suction effect,conventional cd is preferred which can also show good results .<sup>43</sup> When we consider rehabilitation in a complete denture patient to achieve a pleasant smile aesthetics plays a vital role. <sup>44,45</sup> Future scope is a prospective study of the denture and the patient satisfactory level on a long term basis can be evaluated and can make use of Electromyography for a much precise value of the muscle activity with a review both pre op and post operative of denture placement review each month.



**Graph 1** -The graph shows the assessment of nasolabial fold in post operative of complete denture patient where the x axis shows the type of complete denture treatment (BPS/Conventional denture) and the y axis shows the sample size of edentulous patients . Blue colour graph in the bar chart represents the prominence of the nasolabial fold and the red colour represents that the nasolabial fold is not so prominent. BPS type of denture fabrication showed better nasolabial fold postoperative results compared to the conventional method. Similarly, Chi - square test of association between complete denture treatment and adequate lip support post operative shows statistically significant ( $p < 0.05$ ) where pearson chi-square = 10.941 and p value = 0.001.



**Graph 2** -The graph shows the assessment of facial wrinkles in post operative of complete denture patient as presence or absence of facial wrinkles, where the x axis shows the type of complete denture treatment (BPS/Conventional denture) and the y axis shows the sample size. Blue colour graph in the bar chart represents the presence of facial wrinkles and the red colour represents that the absence of facial wrinkles. BPS type of denture fabrication showed better facial wrinkle post operative results compared to the conventional method. However, there it is not significant statistically. Chi - square test of association between complete denture treatment and adequate lip support post operative shows statistically not significant ( $p > 0.05$ ) where pearson chi-square =5.663 and p value =0.057.



**Graph 3 -** The graph shows the assessment of adequate lip support in post operative of complete denture patient as adequate / less or more than adequate ,where the x axis shows the type of complete denture treatment (BPS/Conventional denture) and the y axis shows the sample size. Blue colour graph in the bar chart represents the less or more than the adequate lip support and the red colour represents adequate lip support. BPS type of denture fabrication showed better lip support post operative results compared to the conventional method. Similarly, Chi - square test of association between complete denture treatment and adequate lip support post operative shows statistically significant ( $p < 0.05$ ) where pearson chi-square = 19.242 and p value = 0.000

### Conclusion

Within the limitations of the study it is evident that BPS has shown better postoperative aesthetic results compared to that of the pre op than the conventional CD. The extra oral features such as nasolabial fold and lip support are enhanced while using a BPS type of a complete denture.

**Acknowledgement:** Thank the institution for granting me access to patient database

**Conflict of Interest:** None to declare.

**Source of Funding:** Self.

**Ethical Clearance:** It is taken from “Saveetha Institute Human Ethical Committee” (Ethical Approval Number- SDC/SIHEC/2020/DIASDATA/0619-0320)

### References

1. Polzer I, Schimmel M, Müller F, Biffar R. Edentulism as part of the general health problems of elderly adults. *Int Dent J.* 2010;60(3):143–55.
2. Walls AWG, Steele JG. The relationship between oral health and nutrition in older people. *Mech Ageing Dev.* 2004 Dec 1;125(12):853–7.
3. Sun Y, Lü P, Wang Y. Study on CAD&RP for removable complete denture. *Comput Methods Programs Biomed.* 2009 Mar 1;93(3):266–72.
4. Carlsson GE, Omar R. The future of complete dentures in oral rehabilitation. A critical review. *J Oral Rehabil.* 2010 Feb;37(2):143–56.
5. Douglass CW, Shih A, Ostry L. Will there be a need for complete dentures in the United States in 2020? *J Prosthet Dent.* 2002;87(1):5–8.
6. Cunha TR, Della Vecchia MP, Regis RR, Ribeiro AB, Muglia VA, Mestriner W, et al. A randomised

- trial on simplified and conventional methods for complete denture fabrication: Masticatory performance and ability. *J Dent.* 2013 Feb 1;41(2):133–42.
7. Langer A, Michman J, Seifert I. Factors influencing satisfaction with complete dentures in geriatric patients. *J Prosthet Dent.* 1961 Nov 1;11(6):1019–31.
  8. Berg E. The influence of some anamnestic, demographic, and clinical variables on patient acceptance of new complete dentures. *Acta Odontol Scand.* 1984 Jan 1;42(2):119–27.
  9. Erić J, Tihaček Šojić L, Bjelović L, Tsakos G. Changes in Oral Health Related Quality of Life (OHRQoL) and satisfaction with conventional complete dentures among elderly people. *Oral Health Prev Dent.* 2017;15(3):237–44.
  10. Alfadda SA. The relationship between various parameters of complete denture quality and patients' satisfaction. *The Journal of the American Dental Association.* 2014;145(9):941–8.
  11. Cerutti-Kopplin D, Emami E, Hilgert JB, Hugo FN, Rivaldo E, Padilha DMP. Predictors of Satisfaction with Dentures in a Cohort of Individuals Wearing Old Dentures: Functional Quality or Patient-Reported Measures? *J Prosthodont.* 2017;26(3):196–200.
  12. van Waas MAJ. The influence of clinical variables on patients' satisfaction with complete dentures. *J Prosthet Dent.* 1990 Mar 1;63(3):307–10.
  13. Tôrres ACSP, Maciel A de Q, de Farias DB, de Medeiros AKB, Vieira FPTV, Carreiro A da FP. Technical Quality of Complete Dentures: Influence on Masticatory Efficiency and Quality of Life. *J Prosthodont.* 2019 Jan 9;28(1):e21–6.
  14. Anastassiadou V, Robin Heath M. The effect of denture quality attributes on satisfaction and eating difficulties. *Gerodontology.* 2006 Mar;23(1):23–32.
  15. Magnusson T. Clinical judgement and patients' evaluation of complete dentures five years after treatment. A follow-up study. *Swed Dent J.* 1986;10(1-2):29–35.
  16. Abraham A, Deepika Lakshmi R. [No title] [Internet]. [cited 2020 Jun 5]. Available from: [https://www.researchgate.net/profile/Abby\\_Abraham2/publication/291056338\\_Complete\\_Denture\\_-\\_The\\_BPS\\_Way/links/569dc14708aed27a702fdb92/Complete-Denture-The-BPS-Way.pdf](https://www.researchgate.net/profile/Abby_Abraham2/publication/291056338_Complete_Denture_-_The_BPS_Way/links/569dc14708aed27a702fdb92/Complete-Denture-The-BPS-Way.pdf)
  17. Nabeel S. Biofunctional Dentures-A New Way to Rehabilitate Edentulous Ridges. *Dental Follicle-The E-Journal of Dentistry* [Internet]. 2012;7(9). Available from: <http://search.ebscohost.com/login.aspx?direct=true&profile=ehost&scope=site&authtype=crawler&jrnl=22309489&asa=Y&AN=88285571&h=LCvNOKI8ACgHuBIPN3bWqF5x%2FsSKWj%2BLZy8vu5iDiNpSmHXNq1SVuww5nCU15gXmSR61c4abbx9xmh5q1UYBA%3D%3D&crl=c>
  18. Jain AR, Nallaswamy D, Ariga P, Ganapathy DM. Determination of correlation of width of maxillary anterior teeth using extraoral and intraoral factors in Indian population: A systematic review. *World J Dent.* 2018;9:68–75.
  19. Ashok V, Nallaswamy D, Benazir Begum S, Nesappan T. Lip Bumper Prosthesis for an Acromegaly Patient: A Clinical Report. *J Indian Prosthodont Soc.* 2014 Dec 1;14(1):279–82.
  20. Duraisamy R, Krishnan CS, Ramasubramanian H, Sampathkumar J, Mariappan S, Navarasampatti Sivaprakasam A. Compatibility of Nonoriginal Abutments With Implants: Evaluation of Microgap at the Implant–Abutment Interface, With Original and Nonoriginal Abutments. *Implant Dent.* 2019 Jun;28(3):289.
  21. Ajay R, Suma K, Ali SA, Sivakumar JSK, Rakshagan V, Devaki V, et al. Effect of surface modifications on the retention of cement-retained implant crowns under fatigue loads: An in vitro study. *J Pharm Bioallied Sci.* 2017;9(Suppl 1):S154.
  22. Jyothi S, Robin PK, Ganapathy D, Others. Periodontal health status of three different groups wearing temporary partial denture. *Research Journal of Pharmacy and Technology.* 2017;10(12):4339–42.
  23. Kannan A, Venugopalan S. A systematic review on the effect of use of impregnated retraction cords on gingiva. *Research Journal of Pharmacy and Technology.* 2018;11(5):2121–6.
  24. Venugopalan S, Ariga P, Aggarwal P, Viswanath A. Case Report: Magnetically retained silicone facial prosthesis. *Niger J Clin Pract.* 2014 Mar 27;17(2):260–4.
  25. Kannan A, Others. Effect of Coated Surfaces influencing Screw Loosening in Implants: A Systematic Review and Meta-analysis. *WORLD.*

- 2017;8(6):496–502.
26. Ranganathan H, Ganapathy DM, Jain AR. Cervical and incisal marginal discrepancy in ceramic laminate veneering materials: a SEM analysis. *Contemp Clin Dent.* 2017;8(2):272.
  27. Ashok V, Suvitha S. Awareness of all ceramic restoration in rural population. *Research Journal of Pharmacy and Technology.* 2016;9(10):1691–3.
  28. Basha FYS, Ganapathy D, Venugopalan S. Oral Hygiene Status among Pregnant Women. *Research Journal of Pharmacy and Technology.* 2018;11(7):3099–102.
  29. Selvan SR, Ganapathy D. Efficacy of fifth generation cephalosporins against methicillin-resistant *Staphylococcus aureus*-A review. *Research Journal of Pharmacy and Technology.* 2016;9(10):1815–8.
  30. Ganapathy D, Sathyamoorthy A, Ranganathan H, Murthykumar K. Effect of resin bonded luting agents influencing marginal discrepancy in all ceramic complete veneer crowns. *J Clin Diagn Res.* 2016;10(12):ZC67.
  31. Subasree S, Murthykumar K, Others. Effect of Aloe Vera in Oral Health-A Review. *Research Journal of Pharmacy and Technology.* 2016;9(5):609–12.
  32. Vijayalakshmi B, Ganapathy D. Medical management of cellulitis. *Research Journal of Pharmacy and Technology.* 2016;9(11):2067–70.
  33. Mohindra NK, Bulman JS. The effect of increasing vertical dimension of occlusion on facial aesthetics. *Br Dent J.* 2002 Feb 1;192(3):164–8.
  34. Miralles R, Berger B, Ide W, Manns A, Bull R, Carvajal A. Comparative electromyographic study of elevator muscles in patients with complete dentures and natural dentition. *J Oral Rehabil.* 1989 May;16(3):249–55.
  35. Martone AL. Effects of complete dentures on facial esthetics. *J Prosthet Dent.* 1964 Mar 1;14(2):231–55.
  36. Tallgren A, Holden S, Lang BR, Ash M. Jaw muscle activity in complete denture wearers—A longitudinal electromyographic study. *J Prosthet Dent.* 1980 Aug 1;44(2):123–32.
  37. Prasad K, Prasad A, Buch M. EXTRA--ORAL ANATOMICAL CONSIDERATIONS FOR COMPLETE DENTURE PROSTHESIS. *Guident [Internet].* 2014;7(7). Available from: <http://search.ebscohost.com/login.aspx?direct=true& profile=ehost& scope=site& authtype=crawler&jrnl=09762248&AN=96783676&h=x%2B4M89svYTykO1L1ZYrTeadnCw06U1VikekGHuK8mALg L7IKFa%2By62jYwT6UPQMLx8gj7IihXlxDa0yAuQQNuQ%3D%3D&cr=c>
  38. Saifuddin M, Miyamoto K, Ueda HM, Shikata N, Tanne K. A quantitative electromyographic analysis of masticatory muscle activity in usual daily life. *Oral Dis.* 2001 Mar;7(2):94–100.
  39. Brzoza D, Barrera N, Contasti G, Hernandez A. Predicting vertical dimension with cephalograms, for edentulous patients. *Gerodontology.* 2005 Jun;22(2):98–103.
  40. Gervais RO, Fitzsimmons GW, Thomas NR. Masseter and Temporalis Electromyographic Activity in Asymptomatic, Subclinical, and Temporomandibular Joint Dysfunction Patients. *CRANIO®.* 1989 Jan 1;7(1):52–7.
  41. Bagchi G, Kumar Nath D. Restoration of facial symmetry in a patient with bell palsy using a modified maxillary complete denture: a case report. *Int J Prosthodont [Internet].* 2012;25(3). Available from: <http://search.ebscohost.com/login.aspx?direct=true& profile=ehost& scope=site& authtype=crawler&jrnl=08932174&asa=Y&AN=78435635&h=wIoIi2R8RY%2FRBodsxlCzijwA6uwjm1J9PPap01U%2BYmCb00vcQEDovhf0EaDUaDCvnixhLjWlErb8Ef88pBbS9g%3D%3D&cr=c>
  42. Saini V, Singla R. Biofunctional prosthetic system: A new era complete denture. *J Pharm Bioallied Sci.* 2011 Jan 1;3(1):170.
  43. Vilanova LSR, Sánchez-Ayala A, Ribeiro GR, Campos CH, Farias-Neto A. Conventional Complete Denture in Patients with Ectodermal Dysplasia. *Case Rep Dent [Internet].* 2015 Sep 6 [cited 2020 Jun 5];2015. Available from: <https://www.hindawi.com/journals/crid/2015/714963/abs/>
  44. Lagdive S, Darekar A, Lagdive S. Characterization of Denture Bases-Redefining Complete Denture Esthetics. *Int J Health Biomed Res.* 2012;1:16–20.
  45. Piancino MG, Farina D, Talpone F. Surface EMG of jaw elevator muscles and chewing pattern in complete denture wearers. *Journal of oral [Internet].* 2005; Available from: <https://onlinelibrary.wiley.com/doi/abs/10.1111/j.1365-2842.2005.01524.x>