

Circulating and Renal Endothelin-1 Expression Lead to Glomerular Impairment in High Fat-Induced Diet Wistar Rats

Haslindah Dahlan¹, Muhammad Husni Cangara², Rina Masadah²,
Irfan Idris³, Upik Anderiani Miskad², Andi Alfian Zainuddin⁴, Miswani Mukani¹

¹Research Scholar at Medicine Faculty, Pathology Anatomy, ²Lecturer at Medicine Faculty, Pathology Anatomy, ³Lecturer at Medicine Faculty, Physiology, ⁴Lecturer at Medicine Faculty, Public Health, Hasanuddin University, Jl. Perintis Kemerdekaan KM. 10, Tamalanrea Indah, Kota Makassar; Sulawesi Selatan 90245, Indonesia

Abstract

Objective: This study aimed to determine levels of expression ET-1 in serum and renal tissue associated with changes in kidney structure.

Method: The rats were divided into two groups. The Obese group was given a high-fat-induced diet chow and a standard diet chow for the control group. ET-1 protein expression and localization in the glomerulus of the kidney were examined. The serum of blood checked for ET-1 using ELISA method and assessed the ET-1 expression of the glomeruli by Immunohistochemistry (IHC). Mesangial expansion is an indicator to evaluate the degree of glomerular damage by Periodic Acid–Schiff (PAS staining). Associations between the immunoreactivity for ET-1 in glomeruli and the degree of kidney injury were examined.

Results: Lee Index was significantly higher in the obese group than in the control group ($p < 0.05$). ET-1 immunoreactivity was considerably higher in the obese group than the control rat. It was a strong correlation with enhancing mesangial expansion glomeruli using PAS staining of the renal tissue ($r_s = 0.765$; $p = 0.001$). Contrast to ET-1 levels in the serum revealed no significant in obese rat groups ($p > 0.05$).

Conclusion: These data confirm the role of ET-1 will provide changes in the levels of glomeruli impairment, but serum levels may well fail to reflect the local expression at the tissue level.

Keywords: *Endothelin-1; Obesity; Glomerular impairment; Chronic kidney disease.*

Introduction

Obesity is a complex multifactorial disease involving an excessive amount of body fat. Kelly et al projects that the prevalence of overweight and obesity will increase to 58% of the adult population by 2030.¹⁻³ Obesity is not just a cosmetic concern; it is responsible

for the growing prevalence of chronic diseases. A meta-analysis was conducted to investigate the association of obesity with more mild kidney disease, including proteinuria (CKD stages 1–2) and low kidney function estimated glomerular filtration rate (eGFR) < 60 ml/mnt / 1.73 m²). This study supports the concept that obesity is a direct cause of CKD.⁴ This effect has also been thought to have a strong relationship with the role of ET-1 as a vasoconstrictor agent in obese rats effects on kidney functions.^{5,6} Another study, Ferri C et al., revealed a significant increase in plasma ET-1 levels in obese patients.⁷ Long term incubation fat tissue increased effect of ET-1 could be a mechanism that contributes to increased basal lipolysis in human obesity.⁸ It is suggested that ET-1 plays a vital role in regulating kidney function.

Corresponding Author:

Haslindah Dahlan

Pathology Anatomy, Research Scholar at Medicine Faculty, Hasanuddin University, Jl. Perintis Kemerdekaan KM. 10, Tamalanrea Indah, Kota Makassar, Sulawesi Selatan 9024, Indonesia
e-mail: haslindahdahlan00@gmail.com

Endothelins (ET) are a family of peptides that act as potent vasoconstrictors and pro-fibrotic growth factors. ET-1 is integral to renal and cardiovascular pathophysiology and exerts effects via autocrine, paracrine, and endocrine signaling pathways tied to the regulation of aldosterone, catecholamines, and angiotensin. In the kidney, ET-1 is critical to maintaining renal perfusion and controls glomerular arteriole tone and hemodynamics. It is assumed that ET-1 influences the progression of chronic kidney disease (CKD).⁹ A correlation between ET-1 systemic levels and increased endothelin receptors in the kidney have been reported. Local expression of ET-1, especially in the obese kidney itself, is still unclear, so this is what underlies to see the relationship between levels and distribution ET-1 in kidneys in Wistar obese rats compared with Control Wistar rats.⁶ The aims of this study provide differences in the expression/levels of ET-1 in the kidneys. It can be used as a reference to see the involvement of ET-1 in kidney pathophysiology in obese patients to develop new strategies in the prevention or treatment of obese patients suffering from kidney disease to reduce patient mortality and improve quality of life.

Material and Method

This study is an experimental study with observing high fat-induced rats reach a Lee Index > 300 for the obese group and maintained obesity status 3-4 month and non-obese rats as Control were then terminated and measured the planned variables. We hoped that the design of this time could show the effect of abnormalities on kidneys due to obesity.

Animal Experiment: This study used sixteen male Wistar rats (*Rattus norvegicus*), aged 12-16 weeks with an average weight of 185 g (Laboratory of Pharmacy, Faculty of Pharmacy, Hasanuddin University). Rats were housed in cages at 23-25 °C temperature and under a 12-hour day-night cycle. All of the rats were adapted for seven days. On day 8th, rats were randomly divided into two groups. The Control Groups (n = 8) was fed a standard laboratory diet containing 4.7% crude fat (CE-2; CLEA, Japan), and the other (Obese groups; n = 8) was fed a High-Fat induced diet containing 14.13% crude fat (Quick Fat; CLEA, Japan), and were allowed to eat and drink water at any time (*ad libitum*). All of the rats were adapted for seven days in a cage made from plastic material 25 x 35 cm in size. Each cage contained a rat and was reposed by chaff and given cover by woven wire. The protocol of this study was approved

by the Medical and Health Research Ethics Committee, Faculty of Medicine, Hasanuddin University, Makassar, Indonesia (number: 1141/UN4.6.4.5.31/PP36/2019). Nutritional details of the two diets are provided in Table 1. Bodyweight and food intake were measured every three days throughout the experimental period.

Table 1. The nutritional content of two experimental diets

Ingredients	CE-2	Quick Fat
Moisture (%)	8.65	6.47
Crude protein (%)	25.1	24.7
Crude fat (%)	4.51	14.13
Crude fiber (%)	5.05	3.33
Crude ash (%)	6.97	5.6
NFE (%)	49.72	45.77
Energy (kcal)*	339.9	409.1
Hardness (kg/cm ²)	27.6	12.4
Fat energy (%)	11.94	31.46

*Calculated by multiplying crude protein (4), crude fat (9), and NFE (4)

Lee index was measured the naso-anal lengths, the body weight, and calculated the Lee index between the study groups. This index was calculated by dividing the cube root of body weight (g) by naso-anal length (cm) and multiplying the result by 1000. Lee Index > 300 indicated obese status. Obesity groups and the control groups were maintained for 3-4 months (175 days). Both groups of mice were terminated and measured the planned variables. For termination, rats were anesthetized with intraperitoneal injection using a ketamine cocktail. Xylazine and acepromazine at a dose of 0.1 mL / 10g BW, then we obtained the right kidney to 10% formalin buffer for IHC ET-1 analysis of paraffin block tissue.

ET-1 Serum Analysis: The blood has drawn from the tail, and retro-orbital vessel, then centrifuged at 3000rpm to extract serum. A commercial Rat Endothelin 1 ELISA Kit PicoKine™ (Boster Biological Technology, Pleasanton CA, USA, Catalog # EK0952) was used to assess for circulatory ET-1 level, which followed the manufacturer's manual. Data were analyzed by SPSS with all data presented by the mean and standard deviation.

Immunohistochemical Staining Procedures: We used 4 μm paraffin sections of the right kidney sample on the warming block in a 60°C oven for 30 minutes.

The next step to deparaffinization and rehydration procedure begins with successive submersion in Xylene: twice each for 5 minutes 100%, 90%, 80%, and 70% ethanol concentration for 5 minutes. The rehydration antigen is given for 10 minutes using citrate buffer at 103°C, then incubated to block endogenous peroxidase activity with 3% H₂O₂ for 10 minutes at room temperature, rinsed for three times each time for three minutes with Tris-buffered saline (TBS), and then incubated for 30 minutes in 10% bovine serum albumin (BSA) at room temperature in a humidified room. The tissue area that has been circled by the PAP pen on glass objects and dripped with primary antibodies, monoclonal anti-ET-1 (GeneTexCat No. GTX22786) that has been diluted using a 1:250 dilution and incubated at room temperature for 2 hours. The sections were rinsed three times for three minutes each with PBS and incubated for 30 minutes with an HRP conjugated secondary antibody at room temperature. Then, they are rinsed and dropped with diaminobenzidine (DAB) substrate, and then balanced with hematoxylin. The final step is dehydrated and mounted with Entellan medium.

Right kidney samples prepared with ET-1 immunostaining that were analyzed and mounted, then assessed. ET-1 expression was reported in glomeruli. In each specimen, the staining intensity of ET-1 recorded by two independent observers in 10 adjacent high power fields (±100 glomeruli) and graded as 0 (staining not detectable), 1 (minimal immunostaining in some cells), 2 (weak immunostaining intensity in all cells) and 3 (strong staining in all cells). The mean grade was calculated by an averaging grade assigned by the two authors and approximating the arithmetical mean to the nearest unity.¹⁰

Glomerular Impairment: The glomerular injury was scored based on PAS staining. Scoring was done by grading mesangial expansion by looking at the pink

color of the mesangial matrix and glomerular basal membrane. The lesions were graded on a scale from 0 to 4: 0: normal; 1: the injury involves less than 25% of the glomerulus; 2: the injury involve 25 to 50% of the glomerulus; 3: the injury involves 50 to 75% of the glomerulus; and 4: the extensive damage affecting more than 75% of the glomerulus.¹¹

Statistical Analysis: Data were analyzed using SPSS version 18. Quantitative variables were expressed in means ± SDs. Shapiro–Wilk test was used to analyze the normality of distributions. The comparison of quantitative data was compared using a t-test to analyze variables with normal distribution and equal variances. Mann–Whitney U test was used to analyze the differences when data did not correspond to a normal distribution and the graphics using Prism 6; GraphPad Software. A p-value of < 0.05 was considered statistically significant. Correlation analysis was measured by *spearman's rho*.

Results and Discussion

Obesity Status: Table 2 shows that the obesity status of each group. It offers significant differences ($p=0.000$) between the obese and the control groups after being fed for 63 days and maintenance until the day before terminated (175 days) ($p=0.002$). There was a significant increase in the Lee index of the obese group compared to the control group.

Excess weight gain and obesity may cause renal dysfunction, including glomerular hyperfiltration, sodium retention, enlargement of Bowman’s space, increased glomerular cell proliferation, mesangial matrix expansion, inflammatory cell infiltration, and tubulointerstitial lesions. These early renal alterations can progress to more intense and diffuse lesions in the kidneys, such as focal segmental glomerulosclerosis, proteinuria, and tubulointerstitial lesions, observed in prolonged obesity.¹²

Table 2. Comparison Lee index between control and obese rats group.

Variable	63 day		175 days	
	Control (Mean±std dev)	Obese (Mean±std dev)	Control (Mean±std dev)	Obese (Mean±std dev)
Weight (gr)	283.25±44.98	325.50±27.33	341.50±50.07	417.125±37.68
Length (cm)	21.94±0.73	22.00±0.65	23.00±0.65	23.56±0.68
Lee index	297.96±8.38	311.88±1.84**	303.97±7.66	316.8786±5.81*

Calculated with an independent sample t-test. * $p<0.05$; ** $p<0.001$

Systemic level of ET-1: Table 3 shows that the level of serum ET-1 is not increased significantly ($p>0.05$). This is relevant to earlier studies¹³, has been demonstrated that circulatory levels of ET-1 might not directly reflect the full physiological. Normally circumstances, ET-1 produced by endothelial cells is released abluminal and, therefore, the circulating level of ET-1 is thought to be the result of spillover, the half-life of ET-1 plasma is less than 2 min, owing to its efficient harvesting in the pulmonary or renal vascular beds.¹⁴ ET-1 appears to be

foremost a locally acting paracrine substance, rather than a circulating endocrine hormone. Besides, it is vital to bear in mind that ET-1 plasma concentration is dependent not only on generation but also on renal and receptor-mediated clearance and enzyme-mediated metabolism of the peptide.¹³ Nevertheless, ET-1 plasma concentration could be useful as an index of ET-1 synthetic activity and venous plasma. ET-1 concentrations have been used as markers for the endothelial synthesis of the peptide.^{7,13}

Table 3. Level of serum ET-1 (pg/ml)

Group	n	Mean±std dev	Median (Range)	p-value*
Control	8	9.5±1.60	9 (8-12)	
Obese	8	11.37±1.85	10.5 (10-15)*	0.062

*Calculated with a Mann Whitney U test $p>0,05$

Interpretation of ET-1 immunohistochemistry:

The glomerulus is the functional filtration unit of the kidney. Glomerular injury is frequently associated with progressive CKD. ET-1 expression is positive staining of the glomeruli by Immunohistochemistry (IHC) shows a significant difference between the obese group and the Control group, p value=0.03 ($p<0.05$)(Figure 1). William et al. investigated the immunolocalization of ET-1 in the vasculature and glomerulus of the normal kidney. It is abundantly expressed in the endothelium of glomeruli, arteries, veins, and capillaries. Although ET-1 was rarely detected in the mesangium of the normal kidney¹⁵, By contrast, in stress-induced condition shows mesangial localization of ET-1 peptide consistent in cultured human mesangial cells.^{15,16} ET-1 activation can escalate the progression of chronic kidney disease (CKD) via ET-1 and ETA mediated pro-fibrotic pathways, playing a role in conditions such as diabetic nephropathy (DN), hypertensive nephropathy and focal segmental glomerular sclerosis (FSGS).¹²

The local effect expression of ET-1 in the kidney, especially in the glomerulus, was significantly different between the obese group and the control group ($p>0.05$). Glomerular injury and scarring is the hallmark of CKD progression regardless of the underlying disease. Increased production of ET-1 has been found in multiple conditions associated with CKD, including diabetes and insulin resistance, obesity, and dyslipidemia. ET-1

binding of ETA stimulates renal fibroblasts, driving increased extracellular matrix synthesis, inducing collagen production, and mesangial cell proliferation with the secretion of fibronectin and type IV collagen furthering scar formation.¹²

Figure 1 Light microscopy of kidney sections immunostained for endothelin-1 (ET-1, 400x). Immunostaining scores were graded as follows; (1a) score 0 =No staining, (1b).score 1= minimal immunostaining in some cells; (1c). Score 2 = weak immunostaining intensity in all cells; (1d). Score 3= strong staining in all cells. 1e. Semiquantitative analyses of kidney sections stained for ET-1 scores are reported as means±SE. The significance level for the obese group compared to the control group **Mann Whitney u test $p=0,003$ ($p<0.05$)

Glomerular Impairment: The effect of increasing ET-1 expression in the glomerulus correlates with the increase in mesangial expansion in the glomerulus can be seen in figure 2. Grossly, endothelial cells comprise 45%, mesangial cells 25%, and epithelial cells 30% of all cellular elements of the glomerulus. The mesangial cell is PAS-positive (pink color). An increase in extracellular matrix implies an increase in mesangial matrix or basement membrane material. In the former instance, this may be in a uniform and diffuse pattern in all lobules or cause a nodular appearance to the mesangial healed proliferative lesions are PAS-positive. It leads to the obliteration of capillaries and solidification of all or

part of the tufts. Sclerosis may be associated with the destruction of the urinary space by collagen and an increased extracellular matrix in the capillary tufts. An older and less precise term is glomerular hyalinization. Complete sclerosis is known when the entire glomerulus is involved. When the entire glomerulus is involved, this

is known as complete sclerosis¹⁷, but no data reaches score 4 (diffuse sclerosis) in this study. Figure 2B revealed discrete and focal morphological changes in glomeruli indicate early glomerular impairment in the obesity group than in the control group ($p < 0.05$).

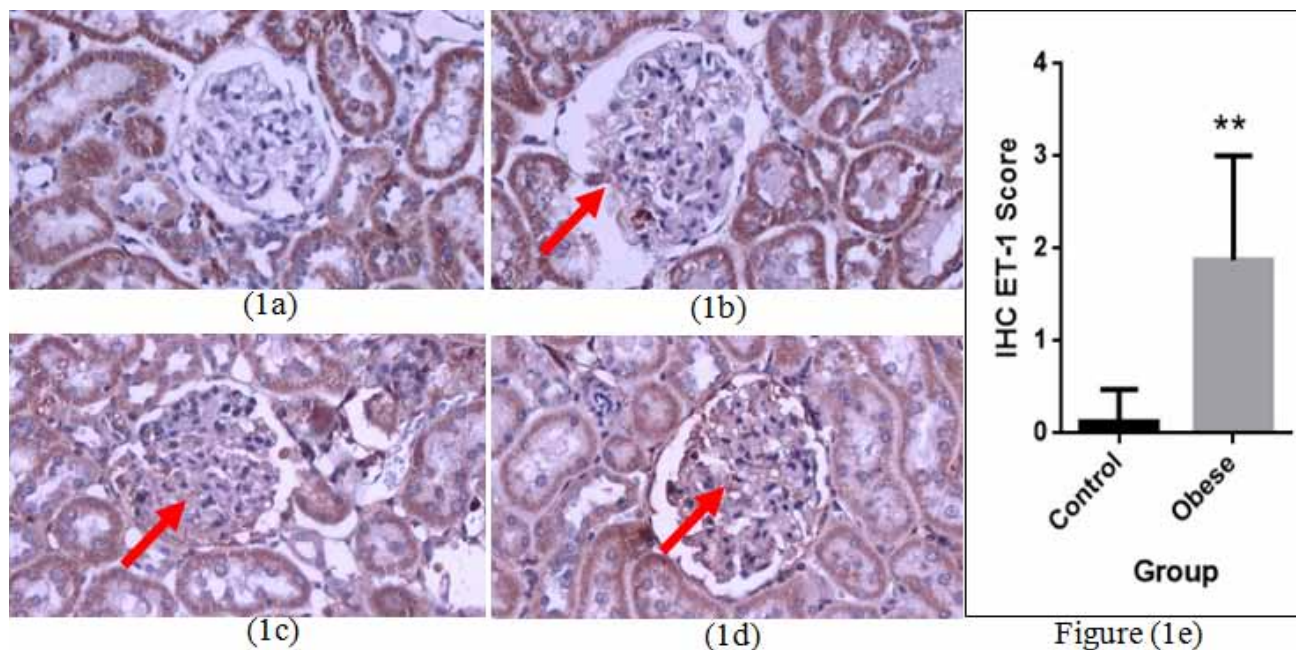


Figure 2A. Light microscopy of PAS staining of the glomerulus from Control and Obese (400x). The mesangial expansion score of glomeruli was graded as follows: 0 represents no lesion (2a), 1 represents the mesangial expansion of 25–50%=2; (2b), >50–75%=3 (2c), (2e). Semiquantitative analyses of kidney sections stained for the PAS staining score are reported as means±SE. The significance level for the obese group compared to the control group. *Mann Whitney u test $p=0,03$ ($p < 0.05$).

The Correlation Glomerular ET-1 glomerular expression and glomerular impairment: A significant correlation between ET-1 expression and glomerular impairment is based on PAS staining. The spearman’s rho correlation value is 0.765, indicates that the direction of correlation is positive with strong correlation strength at the $p = 0.001$. The mesangial matrix is a contractile function important in changing the filtration coefficient. Accumulation extracellular matrix to be responsible for progressive CKD involves glomerular sclerosis and interstitial fibrosis. Although glomerular endothelial cells are probably the principal source of ET-1 in normal conditions, glomerular ET-1 can increase in the presence of proteinuric renal disease. ET-1, probably secreted abluminal from glomerular endothelial cell modulates podocyte and mesangial cell structure and function. The mesangial cell itself makes it possible to

produce a significant amount of ET-1.¹⁷ We conclude that the effects of ET-1 can cause changes in glomerular filtration area and intraglomerular hemodynamics.

Conclusion

In summary, our results revealed the local effect expression of ET-1 in the kidney, especially in the glomerulus, leads to glomerular injury as a hallmark of CKD progression regardless of the underlying disease. However, systemic or circulating ET-1 level is detected from serum might not directly reflect the local expression at kidney injury in obesity. Further study is needed to assess the relationship between GFR, metabolic disturbances in the blood to determine the degree of kidney function, and what about the receptors (ETA and ETB receptor).

Ethical Clearance: No ethical approval is needed.

Source of Funding: Self

Conflict of Interest: Nil

References

- Kelly T., Yang W., Chen CS., Reynolds K., He J. Global burden of obesity in 2005 and projections to 2030. *Int J Obes.* 2008;32(9):1431-7, doi: 10.1038/ijo.2008.102.
- Lakkis JL., Weir MR. Obesity and kidney disease. *Prog Cardiovasc Dis.* 2018;61(2):157-67, doi: <https://doi.org/10.1016/j.pcad.2018.07.005>.
- Uzogara SG. Obesity epidemic, medical and quality of life consequences: a review. *Int J public Heal Res.* 2017;5(1):1.
- Nehus E. Obesity and chronic kidney disease. *Curr Opin Pediatr.* 2018;30(2):241-6, doi: <https://doi.org/10.1097/MOP.0000000000000586>.
- Weil BR., Westby CM., Van Guilder GP., Greiner JJ., Stauffer BL., DeSouza CA. Enhanced endothelin-1 system activity with overweight and obesity. *Am J Physiol Circ Physiol.* 2011;301(3):H689-95, doi: <https://doi.org/10.1152/ajpheart.00206.2011>.
- Idris I., Sinrang AW., Arsyad A., Alwi S., Sandira MI. The rise of circulatory endothelin (ET)-1 and endothelin receptors (ETA, ETB) expression in kidney of obese wistar rat. *Int J Physiol Pathophysiol Pharmacol.* 2019;11(2):31.
- Ferri C., Bellini C., Desideri G., Baldoncini R., Properzi G., Santucci A., et al. Circulating endothelin-1 levels in obese patients with the metabolic syndrome. *Exp Clin Endocrinol Diabetes.* 1997;105(S 02):38-40.
- Eriksson AKS., Van Harmelen V., Stenson BM., Åström G., Wåhlén K., Laurencikiene J., et al. Endothelin-1 stimulates human adipocyte lipolysis through the ET A receptor. *Int J Obes.* 2009;33(1):67-74, doi: 10.1038/ijo.2008.212.
- Rossi GP., Seccia TM., Barton M., Danser AHJ., de Leeuw PW., Dhaun N., et al. Endothelial factors in the pathogenesis and treatment of chronic kidney disease Part I. *J Hypertens.* 2018;36(3):451-61, doi: 10.1097/HJH.0000000000001599.
- Wagrowska-Danilewicz M., Danilewicz M. Immunohistochemical study of endothelin-1 (ET-1) in human acute renal allograft rejection. *Pol J Pathol.* 2003;54(2):95-100.
- Qi H., Casalena G., Shi S., Yu L., Ebefors K., Sun Y., et al. Glomerular endothelial mitochondrial dysfunction is essential and characteristic of diabetic kidney disease susceptibility. *Diabetes.* 2017;66(3):763-78, doi: 10.2337/db16-0695.
- Raina R., Chauvin A., Chakraborty R., Nair N., Shah H., Krishnappa V., et al. The Role of Endothelin and Endothelin Antagonists in Chronic Kidney Disease. *Kidney Dis.* 2020;6(1):22-34, doi: <https://doi.org/10.1159/000504623>.
- Campia U., Tesauro M., Di Daniele N., Cardillo C. The vascular endothelin system in obesity and type 2 diabetes: pathophysiology and therapeutic implications. *Life Sci.* 2014;118(2):149-55, doi: <https://doi.org/10.1016/j.lfs.2014.02.028>.
- Shah R. Endothelins in health and disease. *Eur J Intern Med.* 2007;18(4):272-82, doi: <https://doi.org/10.1016/j.ejim.2007.04.002>.
- Herman WH., Emancipator SN., Rhoten RLP., Simonson MS. Vascular and glomerular expression of endothelin-1 in normal human kidney. *Am J Physiol Physiol.* 1998;275(1):F8-17, doi: <https://doi.org/10.1152/ajprenal.1998.275.1.F8>.
- Dhaun N., Webb DJ., Kluth DC. Endothelin-1 and the kidney—beyond BP. *Br J Pharmacol.* 2012;167(4):720-31, doi: <https://doi.org/10.1111/j.1476-5381.2012.02070.x>.
- Agarwal SK., Sethi S., Dinda AK. Basics of kidney biopsy: A nephrologist's perspective. *Indian J Nephrol.* 2013;23(4):243, doi: 10.4103/0971-4065.114462.