

# Rationale of Evaluation of Potency in Medicolegal Cases of Sexual Assault by Penile Color Doppler with Injection of Papaverine

Shilpa Domkundwar<sup>1</sup>, Varsha V Jadhav<sup>2</sup>, Sonal Khandelwal<sup>3</sup>

<sup>1</sup>Professor & Head of Dept of Radiodiagnosis, Grant Govt Medical College and JJ Groups of Hospitals, Byculla, Mumbai, <sup>2</sup>Associate Professor at Dept of Radiodiagnosis, Grant Govt Medical College and JJ gr of Hospitals, Byculla, Mumbai, <sup>3</sup>Senior Resident at Dept of Radiodiagnosis, Grant Govt Medical College and JJ gr of Hospitals, Byculla, Mumbai

## Abstract

**Introduction:** Impotency in male is inability to develop or maintain a sufficient penile erection to conclude the act of intercourse to orgasm and ejaculation. The question of potency arises in many lawsuits in civil and criminal courts. In India, potency testing which includes penile color doppler with injection papaverine is done for all accused of sexual assault as a blanket rule. Penile color doppler with injection papaverine has its own limitations and side effects. Our study therefore aims to analyze and ascertain the justification of subjecting each accused of sexual assault to penile color doppler with injection papaverine.

### Aims and Objectives:

1. To analyse whether evaluating potency in every medico legal case of sexual assault referred to our department using color doppler with injection papaverine is justified.
2. To recommend changes based on our study.

**Method:** This study is a retrospective analysis of data of 166 accused of sexual assault, between the period of May 2015-April 2018. Baseline ultrasound and penile color doppler assessment of erection following papaverine injection was done.

**Results:** Procedure was performed on 166 accused of sexual assault, of whom the, 3 (1.80%) had arterial insufficiency. 6 (3.61%) accused on whom the procedure was performed developed priapism as complication. The rate of complications was found to be double than the positive result of the procedure.

**Conclusion:** We conclude from our study that, due to limited role and complications of penile doppler and change in the definition of rape and laws related to it, overburdened health infrastructure of our country, every accused of sexual assault should not be subjected to penile color doppler study

**Keyword:** *Erectile dysfunction(ED), Potency, Color Doppler, Papaverine*

---

### Corresponding author:

**Dr. Varsha V Jadhav**

Associate Professor at Dept of Radiodiagnosis, Grant Govt Medical College and JJ gr of Hospitals, Mumbai.  
Address: Rm no 25, Trimurty bldg, JJ hospital Campus, JJ Road, Byculla, Mumbai 400008.  
Phone No: 8451993566,  
Email: varshajadhav84@gmail.com

## Introduction

Erectile dysfunction is described as inconsistent ability to generate or maintain an erection of sufficient rigidity for sexual intercourse.

A male is said to be impotent when there is inability to develop or maintain a sufficient penile erection to conclude the act of intercourse to orgasm and ejaculation.

In civil courts the question of potency arises in cases like adoption, disputed paternity, nullity of marriage and divorce. In criminal courts the potency is examined in cases of crime against women and children like rape, sexual assault, molestation, sodomy<sup>11</sup>

A number of medico-legal cases assert impotency in plea. In India, potency testing for all accused of sexual assault is done as a blanket rule despite of the fact whether or not the accused claims it. Such accused are subjected to penile color doppler with injection papaverine for establishing the potency. Penile color doppler with injection papaverine, although a minimally invasive tests has its own limitations and side effects.

There are many other screening tests available to screen for erectile dysfunction.

With the change in the current legislation, the new amendment of Section 375 IPC, implies, peno-vaginal intercourse is not necessary to commit rape<sup>1</sup>.

Our study therefore aims to systematically analyze and ascertain the justification of subjecting each accused of sexual assault to penile color Doppler with injection papaverine.

### **Aims and Objectives**

3. To analyse whether evaluating potency in every medico legal case of sexual assault referred to our department using color doppler with injection papaverine is justified.

4. To recommend changes based on our study.

### **Materials and Method**

This study is a retrospective analysis of data of 278 accused(sec 375,377,376 IPC) referred to the Department of Radio-diagnosis, Sir JJ group of hospitals, Mumbai between the period of May 2015-April 2018. They were in the age group of 15-77 years. All those who consented for the procedure were included. In case of minors, informed consent was taken from the accompanying guardians.

Any accused who did not consent for the procedure were excluded from the study(110 cases). 2 of the accused had e/o local inflammation and hence the procedure was not carried out. Hence procedure was performed on 166 accused.

A base line study was performed initially. Patient was placed in supine position, preferably in a quiet cool place with penis in its anatomical position.

The penis was scanned in longitudinal and cross-sectional views using B mode high frequency linear transducer (7.5-9.0 MHz).

Cavernosa and tunica albuginea were analysed. The local area is cleaned and draped using all aseptic precautions.

Pre injection baseline diameters of the cavernosal arteries are recorded.

60 mg of papaverine (2 mL ampoule of 30 mg/mL diluted in 2 ml of distilled water) was injected intra-cavernosally using an insulin syringe under USG guidance avoiding the cavernosal artery. Precaution taken to avoid spill.

Post-injection measurements were taken at 5, 10, 15 and 20 minutes. The inner diameter of cavernosal artery, peak systolic velocity, end diastolic velocity, visual tumescence and erection were monitored.

Assessment of erection following papaverine injection:

Phase 1: sudden increase in both systolic and diastolic flow velocity in cavernosal artery with minimal tumescence

Phase 2: with further increase in intra-cavernosal pressure, there is a decrease in diastolic flow with a classical 'dicrotic' notch

Phase 3: as the intra-cavernosal pressure increases, diastolic flow reaches zero with further increase in tumescence

Phase 4: diastolic flow reversal occurs with maximum systolic velocity; this is associated with penile rigidity

Phase 5: decrease in the systolic flow velocity occurs; this is usually 15 minutes post-injection which is associated with reduction in tumescence and rigidity

Interpretation: In flaccid state, monophasic flow is seen with absent/minimal diastolic flow. With onset of erection, systolic and diastolic flow both increases. With further increase in pressure, 'dicrotic notch' appears with dip in diastolic flow. End-diastolic flow may go

down to zero or reversal may be seen. Then monophasic flow is seen with sharp systolic peak.

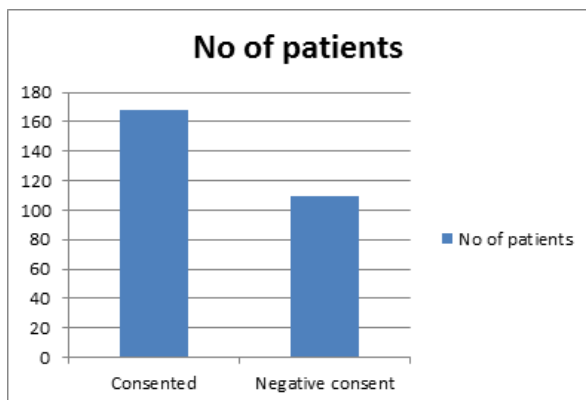
**Table 1: Penile Doppler parameters and diagnostic criteria<sup>3</sup>**

Doppler parameter	Diagnostic criteria
Peak systolic velocity of CA	Indicator of arterial influx Normal >35cm/sec Gray zone 25-35 cm/sec Abnormal <25 cm/sec
End diastolic velocity of CA	Normal <3-5cm/sec Venous leak : >5cm/sec Diastolic flow reversal is indicator of intact veno occlusive mechanism
Resistive index of CA	Normal >0.9 Venous leak <0.75
Arterial compliance of the CA	60%-75% increase in diameter , Evident pulsation
CA, cavernosal artery.	

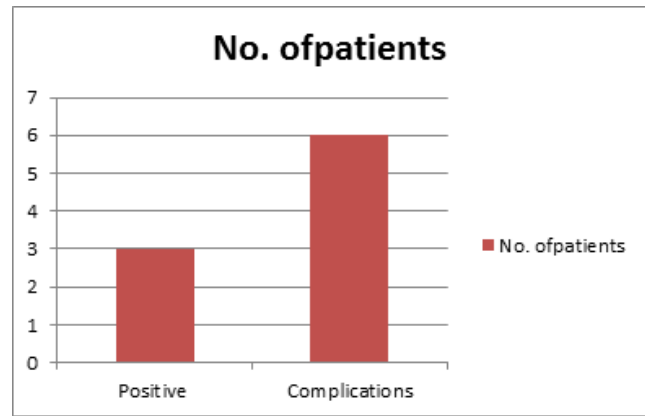
**Observations and Results**

Out of the 278 accused of sexual assault, 110 did not consent for the procedure. 3 had Peyronies disease, out of which one had normal penile doppler study and in other two procedure was not performed due to local inflammation. Procedure was performed on 166 accused of whom the, 3 (1.80%) had arterial insufficiency. 6 (3.61%) accused on whom the procedure was performed developed priapism as complication.

The rate of complications was found to be double than the positive result of the procedure.



**Fig:1. Total number of patients consenting for the procedure**



**Fig:2. The results of the procedure {positive:3(1.8%), complications:6(3.61%)}**

**Review of Literature**

Physiologic process of normal erection begins with psychological factors (mental impulse) which cause transmission of parasympathetic motor impulses to the penis. This causes relaxation of smooth muscles in wall of cavernosal sinusoids , allowing sinusoids to expand and decreasing resistance to incoming blood flow. At the same time, cavernosal arteries dilate and carry increased blood flow into the penis. As the sinusoidal spaces start filling, the corporal veno-occlusive mechanism activates, and the fibrous tunica albuginea compresses the draining veins of the corpora, and rigid erection is achieved.<sup>2</sup>

Normal erectile function requires normal psychological health, normal endocrine balance, intact innervation to penis, normal cavernosal sinusoids, adequate arterial supply and normal venous occlusion with erection. Abnormalities of any of these systems may lead to erectile dysfunction.<sup>2</sup>

Erectile dysfunction is described as inconsistent ability to generate or maintain an erection of sufficient rigidity for sexual intercourse.

Etiology of erectile dysfunction:

- I) Psychogenic- 10%
- II) Organic-Neurogenic, Arteriogenic-30%, Venogenic-15%, Morphological, Drugs

To correctly diagnose/rule out impotency other than general physical examination, following Tests/ investigations are needed to be performed-<sup>11</sup>

I) Blood test:

- a. Serum testosterone and sex hormone binding globulin- to exclude endocrine causes.

- b. Fasting glucose and glycated hemoglobin (HbA1c)- to exclude latent diabetes mellitus
- c. Lipid profile- for deranged lipid profile
- d. Thyroid hormones- for hypogonadal patients.
- e. FSH- for patients with special clinical conditions.

II)Nocturnal penile tumescence.

III)Duplex ultrasonography.

IV)Intracavernosal testing with vasoactive substance.

V)Cavernosometry – used to test for venous leaks.

VI)Cavernosography–it is radiographic visualization of the cavernous penile tissues using contrast material in order to exclude structural abnormalities within the cavernous tissues. VII)Penile arteriography.

VIII)Spongiosography.

Priapism (an erection that lasts for more than 4 hours<sup>9</sup>) is the most serious complication of the procedure which may lead to penile fibrosis. Other complications of penile Doppler with vasoactive stimulation include hypotension, pain, and hematoma.

Current legislation

Excerpts from section 375 IPC (Criminal Law (Amendment) ACT, 2013)<sup>1</sup>

A man is said to commit “rape” if he—

A.

Penetrates his penis, to any extent, into the vagina, mouth, urethra or anus of a woman or makes her to do so with him or any other person; or

B.

Inserts, to any extent, any object or a part of the body, not being the penis, into the vagina, the urethra or anus of a woman or makes her to do so with him or any other person; or

C.

manipulates any part of the body of a woman so as to cause penetration into the vagina, urethra, anus or any part of body of such woman or makes her to do so with

him or any other person; or

D.

Applies his mouth to the vagina, anus, and urethra of a woman or makes her to do so with him or any other person, under the circumstances falling under any of the following seven descriptions.

## Discussion

Vincenzo Mirone et al<sup>4</sup> in his study had proposed two tiered examination for evaluating erectile dysfunction. First level diagnostic tests included anamnesis, validated questionnaire, routine laboratory tests and hormonal profile. These tests were enough to make an etiological diagnosis of erectile dysfunction and to identify and remove any erectile dysfunction risk factors in most cases. First level tests should be performed, so that urologists can accurately diagnose erectile dysfunction and prescribe relevant treatment. Second level diagnostic evaluation included specialistic instrumental exams helpful for accurate etiological diagnosis of erectile dysfunction. These exams, included Penile dynamic color-duplex Doppler ultrasonography, nocturnal penile tumescence recording, cavernosometry/cavernosography and neurological investigation. However, they proposed that these tests should be performed when first level diagnostic assessment was not clear, or an underlying organic pathology needed to be excluded in young patients with persistent ED, when veno-occlusive or neurogenic ED was suspected.

Martins FE et al<sup>5</sup> determined the role and validity of visual erotic stimulation as a more physiological and cost-effective diagnostic modality for primary noninvasive screening of psychogenic versus organic impotence. He reported that a positive response to visual erotic stimulation is strongly indicative of a predominantly psychogenic cause of erectile dysfunction and can be performed as an initial, minimally invasive test for cost-effective screening of psychogenic impotence.

There are other ways of screening like physical examination, psychometric evaluation, nocturnal penile tumescence, serum hormone levels blood chemistry and newer methods like visual erotic stimulation, which have no test related complications.

There are complications related to color Doppler study with intracavernous papaverine injection, most important is priapism. Penile Doppler with

intracavernous injection of papaverine induced priapism rate in different previous studies has been compared with our study in table 2

**Table 2: Penile Doppler with intracavernous injection of papaverine induced priapism rate in different studies**

STUDY	Cases of intracavernous injection of papverine induced priapism(%)
Our study	3.61%
Kilic M et al. 6	2.68 %
Metawea B et al 7	10%
Shamloul R et al 8	4.7%
Sönmez M G et al 9 12.9%	
Yang Y et al.10	3.6%

Although maximum systolic velocity fairly correlates with arterial function of the penis, there are limitations to this diagnostic method. Patient’s anxiety may diminish the arterial response to vasoactive pharmacological agents to the point that maximum velocities fall below the normal range despite normal arterial function.<sup>2</sup>

A study conducted by Raheel M S et al.<sup>11</sup> concludes that since a person is assumed to be innocent by law unless proved otherwise, should be treated with dignity. They also oppose the trend of subjecting each and every accused of sexual assault to potency test without any rationale.

A similar study conducted by Ozkara H et al.<sup>12</sup> indicated that lawyers may abuse the assertion of erectile dysfunction in lawsuits for divorce and rape.

Although penile doppler ultrasound is extremely helpful in accurate estimation of erectile dysfunction it only caters to detection of arterial/venous/combined /morphological causes of erectile dysfunction. The psychogenic causes not being acknowledged. Potency unlike sterility is not permanent and depends on various factors. Person may be potent at the time of alleged rape but may be impotent at the time of medical examination or vice a versa. This is mainly relevant, when accusation is brought up after considerable time gap. Person who

is impotent towards one person may be potent to other person. Person impotent to one gender may be potent to other gender. So even after having normal result of Doppler study, which excludes organic cause, person may still be impotent at any particular situation or vice versa.

The new amendment of Section 375 IPC<sup>1</sup>, implies, peno-vaginal intercourse is not necessary to commit rape. This broadens the definition of abuse beyond the organic causes and hence further reduces the role of an invasive test as relevance in the accusation.

There is also involvement of a lot of specialised manpower (urologist, radiologist and para medical staff) who not only have to do the examination but also attend court summons in future. Also, the cost of the procedure is borne by the government. In India health sector already struggles lack of funds and manpower. There is no justification of diverting so many resources to one such issue when the study will not even have much impact on fate of the case.

Hence accused who is not asserting impotency should not be subjected to penile color doppler study and Penile color doppler with papaverine injection should be done in cases found impotent on screening.

**Conclusion**

We conclude from our study that, due to

- Limited role of penile Doppler in evaluation of causes of erectile dysfunction.
- Complications like priapism of the procedure.
- Change in the definition of rape and laws related to it.
- overburdened health infrastructure of India

Every accused of sexual assault should not be subjected to penile color doppler study

Based on our study we would also like to offer some suggestions:

- 1) Not all accused of sexual assault should be subjected to potency tests- only the accused asserting impotency should undergo potency test and color Doppler ultrasound .
- 2) Proper medical history with lab investigations

should be done.

3) Screening methods for impotency like visual erotic stimulation, NPTR (nocturnal penile tumescence and rigidity) should be done. Penile color doppler with papaverine injection should be done in cases found impotent on screening.

**Conflict of Interest:** None declared

**Source of Funding:** None

**Ethical Clearance:** None declared

### References

- 1) India. Ministry of Law and Justice. Criminal amendment act 2013. [Internet]. Available from < [http://www.prsindia.org/uploads/media/Criminal%20Law,%202013/Criminal%20Law%20\(A\),%202013.pdf](http://www.prsindia.org/uploads/media/Criminal%20Law,%202013/Criminal%20Law%20(A),%202013.pdf) > ; 2013 Cited 2015 july 07.
- 2) Zwiebel W , Benson C, Doubilet P. Duplex Ultrasound Evaluation of Male Genitalia. In: Zwiebel W, Pellerito J editor: Introduction to vascular ultrasonography, 5<sup>th</sup> edition. Philadelphia: Pennsylvania; 2005. P.659-684.
- 3) Jung D C, Park S Y, Lee J Y. Penile Doppler ultrasonography revisited. Ultrasonography. 2018 Jan; 37(1): 16–24.
- 4) Mirone V. Investigating a patient with erectile dysfunction: Is it really necessary?. Indian J Urology. 2006;22(3):220-4.
- 5) Martins FE, Reis JP. Visual erotic stimulation test for initial screening of psychogenic erectile dysfunction: A reliable noninvasive alternative?. The Journal of urology. 1997 Jan 31;157(1):134-9.
- 6) Kilic M, Serefoglu EC, Ozdemir AT, Balbay MD. The actual incidence of papaverine-induced priapism in patients with erectile dysfunction following penile colour Doppler ultrasonography. Andrologia. 2010 Feb;42(1):1-4.
- 7) Metaweia B, El-Nashar AR, Gad-Allah A, Abdul-Wahab M, Shamloul R. Intracavernous papaverine/ phentolamine-induced priapism can be accurately predicted with color Doppler ultrasonography. Urology. 2005 oct;66(4):858–60.
- 8) Shamloul R, Ghanem HM, Salem A, Kamel II, Mousa AA. The value of penile duplex in the prediction of intracavernous drug-induced priapism. International journal of impotence research. 2004 Feb;16(1):78–9.
- 9) Sonmez M G and Ozturk A .Is there a relation between priapism occurring after penile doppler ultrasonography and international erectile function index score and erection hardness score levels? .Turkish Journal of Urology. 2017 Dec; 43(4): 439–743.
- 10) Yang Y, Hu JL, Ma Y, Wang HX, Chen Z, Xia JG, et al. Oral tadalafil administration plus low dose vasodilator injection: a novel approach to erection induction for penile color duplex ultrasound. The journal of urology. 2011 July;186(1):228–32.
- 11) Raheel MS, Yadav A, Pooniya S, Gupta SK, Jaiswal AK. Potency test of a rape accused in India–Rationale, problems and suggestions in light of the Criminal Law (Amendment) Act, 2013. Egyptian Journal of Forensic Sciences. 2016 Nov ;6:333-336.
- 12) Ozkara H, Asicioglu F, Alici B, Akkus E, Hattat H. Retrospective analysis of medicolegal cases and evaluation for erectile function. The American journal of forensic medicine and pathology. 1999 Jun ;20(2):145-9.