

Management of Endo-perio Lesion by Guided Tissue Regeneration: A Case Report

Abhaya Chandra Das¹, Sourav Panda¹, Manoj Kumar¹, Gatha Mohanty², Utkalika Das³

¹Reader, Department of Periodontics and Oral Implantology, ²Senior Lecturer, Department of Periodontics and Oral Implantology, ³Tutor, Department of Periodontics and Oral Implantology, Institute of Dental Sciences, Siksha 'O' Anusandhan (Deemed to be University), Bhubaneswar, Odisha, India

Abstract

To diagnose and to treat, is a crucial part of management of an endo-perio lesion. The sign and symptoms of endo-perio lesion are difficult to account for a general dental surgeon. For that reason, it needs more detailed examination and definite treatment plan. The outcomes of endo-perio lesion are highly unpredictable due to its multiple etiological factors. The primary and secondary etiological factors of endo-perio lesions may have numerous variations and ultimately conclude the definite treatment plan complex. A 43-year-old female patient came to the Department of Periodontics, with a chief complaint of pain in the right posterior lower tooth region. On clinical examination, there was 5mm of periodontal pocket, occlusal restoration in 47. The treatment plan was made as first endodontic treatment followed by periodontal treatment. So endodontic treatment was carried out first in 47 after oral prophylaxis. Then under local anesthesia, open debridement was done in 47 and bone graft was placed in the defect. Resorbable membrane was placed over the graft. Suture was placed and periodontal dressing was given and followed up to 9 months. She was very satisfied with the result.

Keywords: Endo-perio lesion, endodontic treatment, periodontal treatment, alloplastic bone graft, resorbable membrane.

Introduction

In endo-perio lesion, there are two compartments such as periodontal and endodontal compartments. The periodontal compartment is responsible for periodontal disease and the endodontal compartment for pulpal disease. These two compartments are connected with each other by the presence of apical and lateral radicular foramina, which permit the passage of pathogens from one to another.¹ Simring and Goldberg first described the actual

relationship between periodontal and pulpal disease in 1964.² The etiopathogenesis of the endo-perio lesion is described following cases such as:

- Lesions that result from apical to coronal migration of pulpal pathogens and their toxins with or without fistula or sinus tract at the gingival margins depending upon the nature of infection.
- Originating from a marginal lesion which later on extended to the more apical periodontal compartment. The periodontal and pulp are distinct from one another and are anatomically connected through the foramina.
- Another form is the combination of the above, in which the differential diagnosis must attribute each portion of the lesion to its cause.

Periodontal disease causes a destruction of the bone in a coronal to apical direction and in an endodontic lesion it is from apex to coronal direction.³ For this reason, it

Corresponding Author:

Dr. Abhaya Chandra Das

Reader, Department of Periodontics and Oral Implantology, Institute of Dental Sciences, Siksha 'O' Anusandhan (Deemed to be University), Bhubaneswar, Odisha, India
e-mail: drabhaya2011@gmail.com

is very difficult to find out the source of origin of the presenting lesion. It has already established fact that both pulpal and periodontal disease are primarily due to the disease process of the microbial infection.⁴ Hence, both the disease process may originate as separate entities, but due course of disease progression, these may overlap each other. These diseases are frequently noticed as independent entities, which ultimately complicates the proper diagnosis.⁵ There are several classification described the endo-perio lesion as follows.⁵

Classification:

1. Simon et al. 1972

- i. Primary endodontic lesions
- ii. Primary endodontic lesions with secondary periodontal involvement
- iii. Primary periodontal lesions
- iv. Primary periodontal lesions with secondary endodontic involvement
- v. True combined lesions

2. Walton et al. 1996

- i. Endodontic origin
- ii. Periodontal origin
- iii. Combined endo-perio lesion
- iv. Separate endodontic and periodontal lesions
- v. Lesions with communication
- vi. Lesions without communications

3. World workshop 1999

- i. Endodontic periodontal lesion
- ii. Periodontal endodontal lesion
- iii. Combined lesion

The present case report discussed an endo-perio lesion which was managed by guided tissue regeneration after completion of endodontic treatment.

Case Report: A 43-year-old female patient came to Department of Periodontics, with a chief complaint of pain in lower right posterior tooth region. On clinical examination, there was 5mm of periodontal pocket, large occlusal restoration, periapical abscess with sinus in 47 as shown in figure 1. There was presence of generalized

stain and calculus. There was tender on percussion in 47. There was periapical radiolucency in intraoral periapical radiograph in relation to 47 as shown in figure 4A. The vitality test was found negative in 47.⁶ The treatment plan was made as first oral prophylaxis (remove the plaque and calculus) to reduce inflammation, then endodontic treatment followed by periodontal treatment. The patient was free from any systemic diseases, and without tobacco chewing habits.

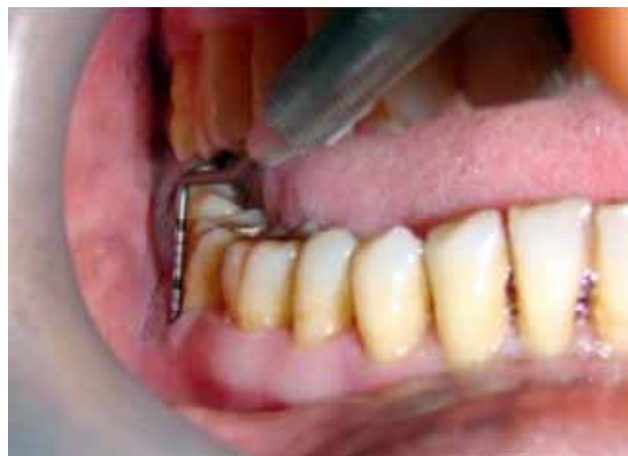

Figure 1: Preoperative view showing 5 mm periodontal pocket in 47

Treatment: Oral prophylaxis was carried out. Then endodontic treatment was carried out first in 47 after oral prophylaxis. Within 2 weeks the periapical abscess along with sinus was resolved. Then under local anesthesia (2% lignocaine hydrochloride with 1:80,000 epinephrine), full thickness flap was reflected and open debridement was carried out in 47 as shown in figure 2. Then DM bone {(Silicon Ion Containing 60% HA, 40% B-TCP), META-BIOMED CO., LTD, Osongsaengmyeong, Republic of Korea} bone graft was placed in the defect and resorbable guided tissue regeneration membrane (PerioCol GTR, Eucare Pharmaceuticals Private Limited, Chennai, Tamil Nadu) was placed over the graft as shown in figure 3. Suture was placed in such a manner that there was no exposure of membrane and graft. Then periodontal dressing (Coe-Pak, GC America INC, USA) was given to minimize the postoperative infection and hemorrhage. It also assists healing by preventing surface trauma during mastication, and protects against pain, which is induced during mastication, as a result of the wound contact with food or the tongue.

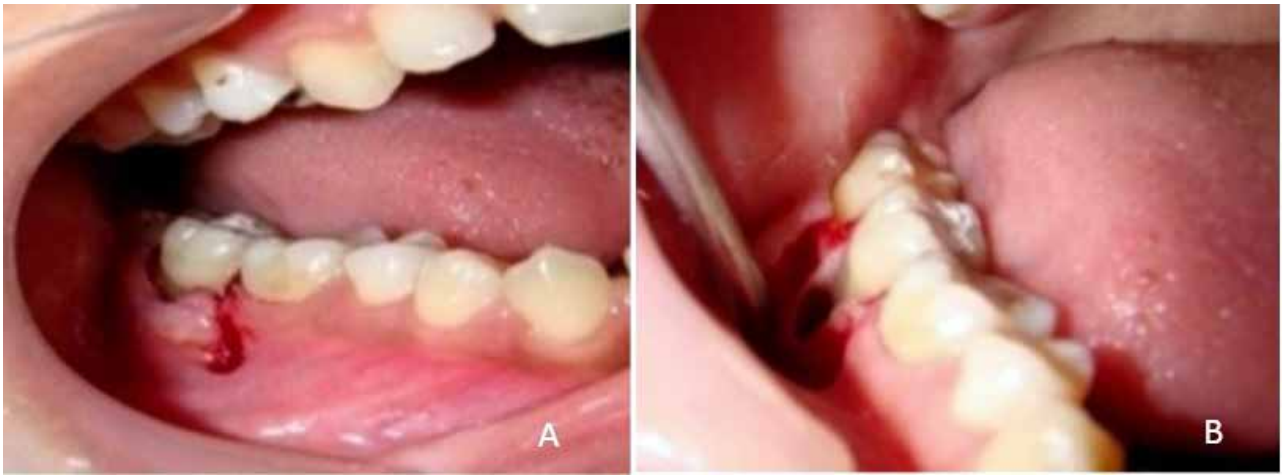


Figure 2: A (Both horizontal and vertical incision given), B (After complete debridement of the defect)

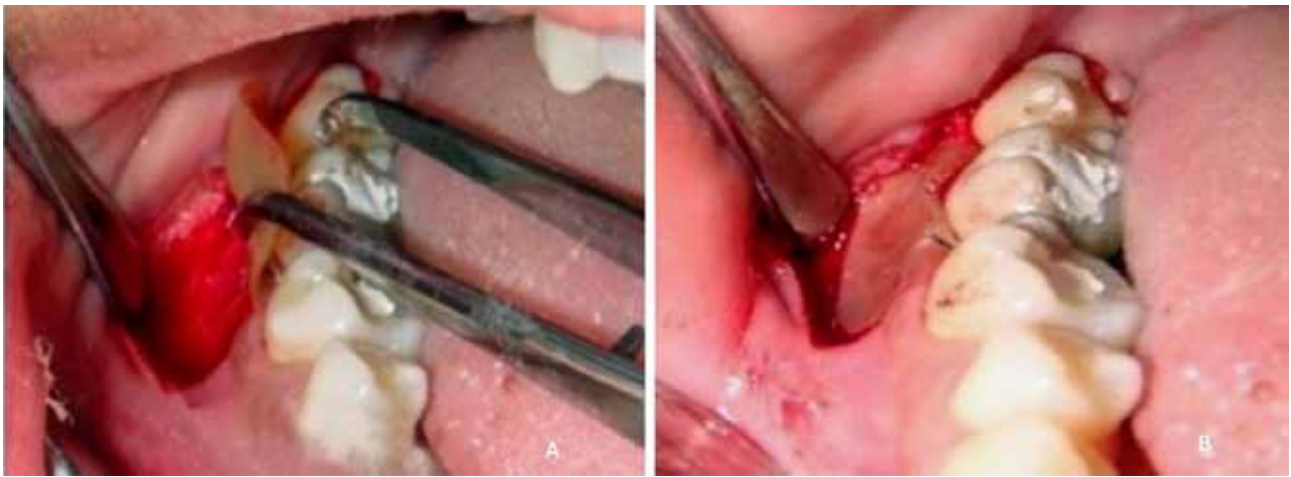


Figure 3: A (Bone graft placed in the defect), B (PerioCol GTR membrane placed)

Results

The present case was weekly follow-up visits for the first month. The reason was to have meticulous plaque control and had an optimum healing. After 2 weeks, suture was removed and washed with normal saline in the surgical site in order to clean the area. Later on, recall visits were done monthly during the next 9 month. These recall visits revealed that the patient maintained oral hygiene perfectly.

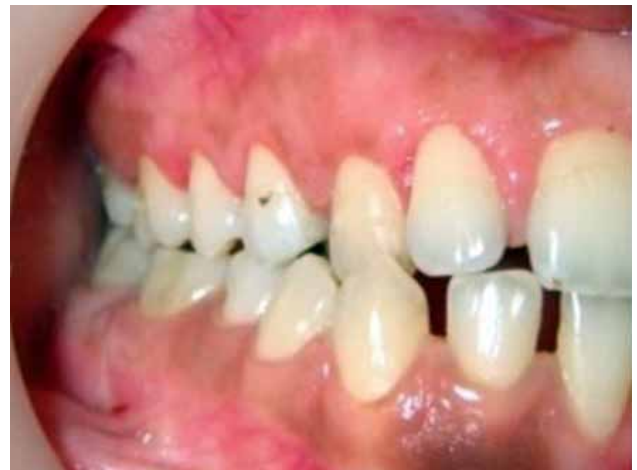

Figure 4: Postoperative view after 9 months

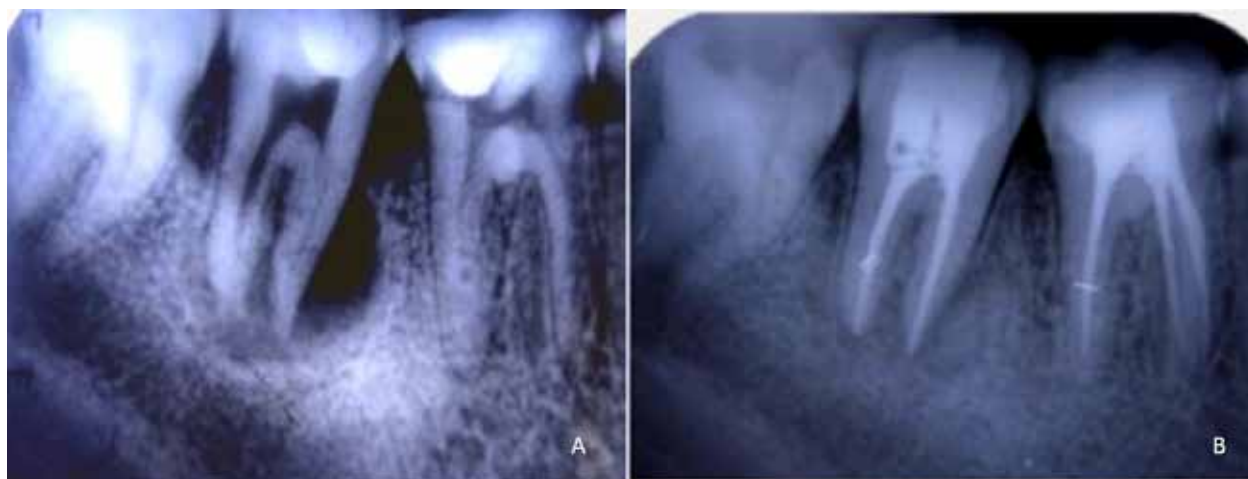

Figure 5: A (Preoperative), B (Postoperative) intraoral radiograph in relation to 47

After 9 months, IOPA in relation to 47 revealed there was completely filled up with bone and formation of lamina dura in the defect as shown in figure 5 and she was very satisfied with the result.

Discussion

Simultaneous presence of pulpal and periodontal disease, makes difficulty in diagnosis and treatment plan. Again it affects the sequence of treatment and long term prognosis too.³ But it is not difficulty in diagnosis of primary endodontic or periodontal disease. For this type case, vitality test is the only easy tool to determine the actual causes of disease. If vitality test is found positive, it means the lesion is primarily periodontal origin, and if negative means primary endodontic origin.⁶ In general, chronic inflammatory reaction of infected tooth can extend into the gingival sulcus and drains through sinus.^{4,7} In this type case, the periodontal manifestation can resolve after successful endodontic treatment. In our case report, there was resolution of sinus tract after successful endodontic therapy, but there was 5 mm periodontal pocket still present.⁸ It was also a case of primary endodontic and secondary periodontal lesion. In this type situation, endodontic treatment should be done first. As after complete debridement from root canal, there will be no infection inside the canal and also in lateral as well as accessory canals, which mainly responsible to connect from endodontal and periodontal compartments and vice versa. After hermetic seal obturation in root canal, there will be no space for any microorganisms and becomes sterile environment. In our case, endodontic treatment was carried out first

then periodontal therapy. So after endodontic therapy, periodontal treatment was carried out. In our case, proper debridement was carried out after full thickness flap reflection. Generally autogenous bone graft or any platelet concentrates is ideal regenerating materials.⁹⁻¹¹ But to harvest autogenous bone graft makes a secondary surgical site. For that reason we placed synthetic alloplastic material {DM bone (Silicon Ion Containing 60% HA, 40% B-TCP), META-BIOMED CO., LTD, Osongsaengmyeong, Republic of Korea} in the defect. We used resorbable membrane (PerioCol GTR, Eucare Pharmaceuticals Private Limited, Chennai, Tamil Nadu) in order to prevent a second surgery need for replacement of nonresorbable membrane. The role of guided tissue regeneration membrane is to prevent migration of epithelial cell, and forms a weak long junctional attachment to the root surface which is not desirable.¹² Hence we used GTR membrane in our case for the above reason.

Conclusion

To manage an endo-perio lesion is not unidirectional, but it includes various treatment options. For the successful treatment of endo-perio lesion depends upon the diagnosis and treatment plan. When both endodontal and periodontal compartments are involved with disease, endodontic treatment should first carry out followed by periodontal treatment. In addition to conventional treatment procedure, other treatment modalities using advanced surgical techniques and materials such as regenerative procedures, radisection, and hemisection, bicuspidization should be considered as per clinical

conditions, which will ultimately result in a favorable long time prognosis.

Conflict of Interests: The authors declare they have no conflicts of interests.

Ethical Issues: Approved

Funding: None

References

1. Foce E. Endo-Periodontal Lesions. London: Quintessence Publishing. 2011;3-5.
2. Simring M, Goldberg M. The Pulpal Pocket Approach: Retrograde Periodontitis. *J Periodontol.* 1964;35(1):22–48.
3. Aksel H, Serper A. A case series associated with different kinds of endo-perio lesions. *J ClinExp Dent.* 2014;6(1): e91–5.
4. Das AC, Sahoo SK, Parihar AS, Bhardwaj SS, Babaji P, Varghese JG. Evaluation of role of periodontal pathogens in endodontic periodontal diseases. *J Fam Med Prim Care.* 2020;9(1):239–42.
5. Al-Fouzan KS. A new classification of endodontic-periodontal lesions. *Int J Dent.* 2014;2014:919173.
6. Petersson K, Söderström C, Kiani-Anaraki M, Lévy G. Evaluation of the ability of thermal and electrical tests to register pulp vitality. *Endod Dent Traumatol.* 1999;15(3):127–31.
7. Das AC, Das SJ, Panda S, et al. Adjunctive Effect of Doxycycline with Conventional Periodontal Therapy on Glycemic Level for Chronic Periodontitis with Type 2 Diabetes Mellitus Subjects. *J Contemp Dent Pract.* 2019;20(12):1417–23.
8. Simon JH, Glick DH, Frank AL. The relationship of endodontic-periodontic lesions. *J Periodontol.* 1972;43(4):202–8.
9. Chatterjee SS, Das AC, Panda S. Platelet Rich Fibrin: A Promising Innovation in Periodontics. *Indian Journal of Public Health Research & Development.* 2019;10(11):772.
10. Panda S, Purkayastha A, Mohanty R, Nayak R, Satpathy A, Das AC, et al. Plasma rich in growth factors (PRGF) in non-surgical periodontal therapy: a randomized clinical trial. *Braz Oral Res.* 2020;34.
11. Panda S, Karanxha L, Goker F, Satpathy A, Taschieri S, Francetti L, et al. Autologous Platelet Concentrates in Treatment of Furcation Defects—A Systematic Review and Meta-Analysis. *Int J Mol Sci.* 2019;20(6):1347.
12. Rosenberg ES, Cytryn F, Guzman A, Maldonado B. The role of guided tissue regeneration and guided bone regeneration. *Ann R Australas Coll Dent Surg.* 1994; 12:80–8.