

Variation in the Shapes of Coronoid Process of Dry Human Mandible of Gujarat Region

Nirali Chavda¹, Priyanka Sharma², Kinjal Jethva³, Kantilal Parmar⁴, Hetal Vaishanani⁵,
A.R.Gandotra⁶, G.V.Shah⁷

¹Tutor, ²Assistant Professor, ³Associate Professor, Department of Anatomy, ⁴Associate Professor, Department of P Anatomy, ⁵Professor, ⁶HOD and Professor, Department of Anatomy, Smt.B.K.Shah Medical Institute and Research Center Sumandeep Vidyapeeth and Institution Deemed to Be university, Vadodara

Abstract

Introduction: Coronoid process is single the bony processes of the ramus of the mandible. It is a thin, triangular eminence, which is flattened from side to side. It differ in shape and size. The importance of frequency in the shapes of Coronoid process is important for maxillofacial surgeons as a graft material as well as for anthropologists for the detection of races.

Aim: To determine the different shape of Coronoid process of mandible in both sides.

Materials and Method: The Present study was conducted on 50 mandibles from the department of Anatomy, Baroda Medical College, Baroda. Variations in the shapes were observed, and photographs were taken.

Results: Triangular shape of Coronoid process was most prominent as compare to hook and round shape. Triangular shaped Coronoid was seen in 70% shaped (Type: I) followed by Rounded shaped 26%, Hook shaped was least 4% respectively.

Conclusion: This study will be helpful for maxillofacial surgeons, anatomists, forensic researchers, anthropologists.

Key Words: Mandible, Coronoid process, Triangular, Rounded, Hook.

Introduction

The mandible is the bone of the jaw bone. It is the largest, strongest, and lowest bone of the face and bears the lower teeth. The mandible is horseshoe-shaped and consists of **Three parts**: a horizontally-oriented body and two vertically oriented rami.

Body The body of the mandible is U-shaped and it presents:

1. Two surfaces

- (a) External surface.
- (b) Internal surface.

2. Two borders

(a) Superior border of the body is called alveolar process.

It bears sockets of lower 16 teeth.

(b) Inferior border or base of the mandible presents a small depression digastric fossa on either side near the median plane.

It gives attachment to the anterior belly of the digastric.

Characteristic on the external and internal surfaces of the body:

The outer surface of the body of the mandible presents the following features:

Symphysis menti : It is a faint median ridge on the external surface of the body.

It marks the line of fusion of the two halves of the mandible at the age of 2 years.

The symphysis menti expands below into a triangular elevation termed mental protuberance.

It forms the point of chin, the base of which is limited on each side by the mental tubercle.

The inner aspect of symphysis menti possesses four tubercles called genial

tubercles arranged into two pairs:

upper and lower.

The upper pair provides attachment to genioglossus muscles and lower pair to geniohyoid muscles.

Mental foramen: It lies below the interval between the premolar teeth and provides passage to mental nerve and vessels.

Oblique line: It is the continuation of the anterior border of the ramus.

It runs downwards and forwards to with regards to the mental tubercle.

Incisive fossa: It is a shallow depression just below the incisor teeth.

The internal surface of the body in each half of the mandible presents the following features

I) Mylohyoid line is a prominent oblique ridge that runs obliquely downwards and forwards from behind the 3rd molar tooth to the symphysis menti below the genial tubercles.

II) Mylohyoid groove lies below the posterior end of the mylohyoid line. Mylohyoid nerve and vessels run in this groove.

III) Sublingual fossa is a shallow area above the anterior part of the mylohyoid line and lodges sublingual gland.

IV) Submandibular fossa is a slightly hollowed out area below the posterior part of the mylohyoid line and lodges submandibular gland.

Ramus of the Mandible

It is more or less a quadrilateral vertical plate of bone that projects upwards from the posterior part of the

body.

The ramus presents the following features:

Two surfaces

(a) Lateral surface.

(b) Medial surface.

Four borders

(a) Anterior.

(b) Superior

(c) Inferior.

(d) Posterior.

3. Two processes

(a) Condylar process, a strong upward projection from postero superior part.

Its upper end is expanded to form head. Neck is the constricted part below head

and presents a depression on its anterior surface called pterygoid fossa.

(b) Coronoid process, a flattened (side to side) triangular protrusion from anterosuperior part.^(2,13)

Coronoid process derived from the Greek word "korone" meaning "like a crown.

The Coronoid process of mandible is a thin, triangular process projects upward and slightly forward.

This process gives attachment to two important muscles of mastication Temporalis muscle attached to apex whole of the medial surface and anterior part of lateral surface.

Rest of the lateral surface gives attachment to masseter.

It varies in shape and size.

The Knowledge of variation in the shapes of Coronoid process is important for maxillofacial surgeons as a graft material as well as for anthropologists for the detection of races.^(3,7)

Aims and Objectives

Aims: To determine the different shape of Coronoid process of mandible in both sides.

Objectives

Depending upon the observation was categories into 3 types.

I Type 1: Triangular: the tip of coronoid process straight upward.

II Type 2: Hook shaped in which the tip of coronoid process was pointing backward.

III Type 3: Rounded:tip is rounded.

Materials and Method

The cross sectional study was performed in Department of Anatomy in Baroda medical college.

Baroda medical college, vadodara ,Gujrat.

A total of 100 dry mandible (50 right side and 50 left side) bones were studied from teaching collection of the Anatomy department. The bones belonged to mature specimens but the exact ages and gender of the specimens were not known. All the mandible selected were dry, complete and showed normal anatomical features and bones showing pathology were excluded from study.

All measurement was carried out by the same instrument.

The data were then entered and analysed using the Microsoft Excel 2010.

The following parameters of the shape of Coronoid process mandible were observed.

SHAPE OF THE CORONOID PROCESS:

Different shape of Coronoid process of mandible in both sides.^(6,8)

OBSERVATION



TYPE:I TRIANGULAR SHAPE

Figure I showing triangular shaped coronoid process which is more observed in current study.^(6,7,13)



TYPE:II ROUNDED SHAPE . Figure II showing Rounded shaped coronoid process which is less observed in current study.

TYPE :III HOOK SHAPE



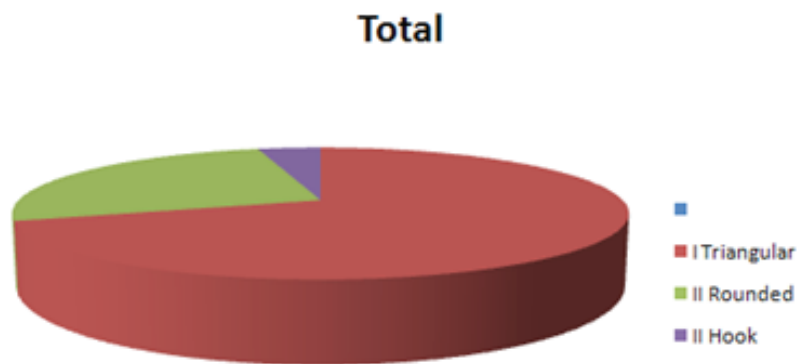
Figure III showing Hooked shaped coronoid process which is very few observed in current study.

Results

Frequency of various shape of coronoid process in total side with percentage.^(6,7,13)

Type	Shape	Total	Percentage	Bi lateral		Unilateral			
				sides	Percentage	Right	left	Total	Percentage
I	Triangular	70	70%	40	57%	20	10	30	43%
II	Rounded	26	26%	20	76%	3	3	6	24%
II	Hook	4	4%	2	50%	1	1	2	50%

Frequency of various shape of coronoid process



In this figure graph showing Frequency of various in various shape of coronoid process in percentage.

Discussion

Differentiation of Vary Studies of Coronoid Process of Mandible.

Frequency of shape of Types of coronoid Process	Triangular Shaped Percentage	Rounded Shaped Percentage	Hook Shaped Percentage
Issac B (2001)11	49	27.4	23.6
Vipul et al (2011)12	54.17	21.25	24.58
Tanveer A(2011)13	67	30	3
sNirmale et al (2012)14	65	28	7
Smita Tapas (2014)15	60	22	18
Vikas Desai (2014)16	68	24	8
Sheela Kadam (2015)17	64.97	21.02	14.01
Priyank Bhabhor (2015)18	29.65	45	25.35
quadric(2016)19	67	30	3
CURRENT STUDY	70	26	4

Tanveer A(2011)13, Vikas Desai (2014)16, A Quadri that observed variation in shape of coronoid process triangular shaped frequency near by to what observed in current study.^(6,7)

Issac B (2001)11, Nirmale *et al* (2012)14, Vikas Desai (2014)16, Sheela Kadam (2015)17 that observed variation in shape of coronoid process rounded shaped frequency near by to what observed in current study.⁽⁸⁾

Tanveer A(2011)13, Nirmale *et al* (2012)14, Vikas Desai (2014)16, quadric(2016)19 that observed variation in shape of coronoid process hook shaped frequency near by to what observed in current study.⁽¹³⁾

Conclusion

Current study, out of 50 mandibles triangular

shaped coronoid process was establish to be majority wide spread keep to rounded shaped next

hook shaped.

i) Awareness of frequency of shape of coronoid process helpful for the maxillofacial surgeons as it can be used as an excellent graft for reconstructive surgeries.⁽³⁾

ii) frequency shape of coronoid process caused by unilateral chewing habits, muscular pull on the process and hormonal factors.⁽³⁾

iii) Knowledge of Variation In Shape is useful Dental Surgeons In Oral

& Maxillofacial Surgeries.⁽⁷⁾

IV) Coronoid process can be easily garner as a donor bone.

V)The coronoid process appear to be suitable for paranasal augmentation.

application is also use because its size and morphology fits into the paranasal region, with the advantages of biocompatibility, availability, and reduced surgery time for harvesting.

Ethical Clearance : Taken Sumandeeep Vidyapeeth.

Source of Funding: Self

Conflict of Interest: Nill

References

- [1]. Basmajian J. V, Slonecker C. E . Grant's Method of Anatomy: Side of skull, temporal and infra temporal regions. 11th ed. Williams & Wilkins, Baltimore. London; 1989
- [2]. Berry, A. C . Factors affecting the incidence of non metrical skeletal variants. Journal of Anatomy ; 1975
- [3]. Clauser L, Curioni, C. and Spanio S. The use of the temporalis muscle flap in facial and craniofacial reconstructive surgery. Journal of Craniomaxillofacial Surgery 1995 23; (4): 203-214.
- [4]. Field, E. J, Harriuson, R. J. Anatomical terms: Their origin and derivation, 1st Edn; W. Heffer & Sons Ltd. Cambridge;1974: 3-4
- [5]. Hamilton, W. J. Textbook of Human Anatomy: Locomoter system 2nd Edn; Macmillan. London: 1976.
- [6]. Isaac B, Holla S.J. Variations in the Shape of the Coronoid Process In the Adult Human Mandible. Journal Anat. Soc. India. 2001 50 (2): 137-139
- [7]. Mintz S.M, Ettinger . A., Schmakel, T. and Gleason M. J. Contralateral coronoid process bone grafts for orbital floor reconstruction : an anatomic and clinical study. Journal of Oral Maxillofacial Surgery 1998 ;56 (10): 1140-1145.
- [8]. Pill-Hoon Choung, Seong-Gon Kim, Seoul Korea. The coronoid process for paranasal augmentation in the correction of midfacial concavity. SEOUL NATIONAL UNIVERSITY Oral Radiol Endod
- [9] Romanes G. J. Cunningham's manual of Practical Anatomy In: The head and neck. 15th ed ; Oxford University Press. Singapore: 1986
- [10]. Schafer E. A, Thane G. D. Quain's Elements of Anatomy. In: The bones of the head. 10th ed. Longmans, green & Co. London ; 1890
- [11]. Snell, R. S. Clinical Anatomy for Medical Students In: The head and neck. 3rd ed. Little Brown and Company Boston; 1996.
- [12]. Soames, R. W: Gray's Anatomy In: Skeletal system. 38th ed. Churchill Livingstone. New York; 1995
- [13]. Tanveer Ahamed Khan H. S, J.H. Sharieff, Observation on Morphological Features of Human Mandibles In 200 South Indian Subjects Anatomica Karnataka, 2011 5 (1) 44-49.