

# Aetiology and Findings of Recurrent Chronic Rhino Sinusitis with Nasal Polyposis after Functional Endoscopic Sinus Surgery

Ali Aziz Abed<sup>1</sup>, Ragheed Turkey Miteab<sup>2</sup>, Ali Majid<sup>2</sup>

<sup>1</sup>Surgeon (F.I.C.M.S), Division of Otolaryngology, Department of Surgery, Al-Karama Teaching Hospital, Al-Karkh Health Department, Baghdad-Iraq, <sup>2</sup>Surgeon(F.I.C.M.S), Division of Otolaryngology, Department of Surgery, Martyr Ghazi Al-Hariri Hospital for surgical specialties, Medical City, Baghdad-Iraq.

## Abstract

**Background:** Nasal polyps are the edematous sinonasal mucosa prolapsing into the nasal cavity. Allergy, asthma, aspirin intolerance and fungal rhinosinusitis have been implicated in various studies. Recurrence of nasal polyposis after functional endoscopic sinus surgery is prevalent but there are no specific causes for recurrence. Intensity of relapse varies depending on multiple factors that implicated in showing characters and findings of the recurrence.

**Objective:** To evaluate causes of nasal polyposis recurrence after FESS.

**Patients and method:** 30 adult patients age between 18 and 60 years (with recurrent nasal polyposis after FESS) were studied in the period between March 2017 and September 2018. Assessment done for all patients by taking Medical history, documented data from the primary surgery, rhinoscopy with CT-scan examination.

**Results:** In this study, most of nasal polyp recurrence occur in 1-3 years after primary surgery, patients using post-operative steroid showed delay in recurrence, post-operative antibiotic showed no effect on time of recurrence, patients with (asthma, allergy, aspirin sensitivity and allergic fungal rhinosinusitis) showed high Lund-Kennedy and Lund-Mackay scores and some patients had anatomical findings mainly (40% incomplete anterior ethmoidectomy).

**Conclusions:** Recurrence of nasal polyposis could occur at any age mainly in middle age group and male gender showed higher prevalence. Asthma, aspirin sensitivity (Samter's triad) and allergic fungal sinusitis were the most important associated diseases. CT-scan showed some anatomical variations like incomplete anterior and posterior ethmoidectomy which occupying the highest percentages. Post-operative steroid showed delay in time of recurrence.

**Keywords:** nasal polyp recurrence, functional endoscopic sinus surgery, nasal polyp associated with asthma, aspirin sensitivity and allergic fungal rhino sinusitis.

## Introduction

Nasal polyps are edematous grapelike protrusions most often originating in the upper part of the nose around the osteomeatal complex on the lateral wall. The surface epithelium tends to be smooth and consists of pale translucent tissue which distinguishes them from the more vascular mucosa of the nasal cavity.

Polyps can vary widely in size and should be considered a bilateral condition. Rare cases of unilateral polyps should only be diagnosed once all other more likely pathologies have been reliably excluded<sup>(1)</sup>

Surgical management is considered for patients who have failed to respond to maximal medical treatment and for those with complications. Functional endoscopic sinus surgery (FESS) aims to improve sinus ventilation

and drainage as well as removing polyps <sup>(1)</sup>

### Embryology of the nose and PNS

Developmentally nose and paranasal sinuses are interlinked. They are always considered together developmentally. The various sinuses may follow different calendars but their origin is the same

Nose and paranasal sinuses always considered together developmentally <sup>(2)</sup>

### **Relevant anatomy**

Nasal endoscopy of patients with nasal polyposis and anatomic examination of specimens have shown that nasal polyps are situated in the middle meatus and that they originate from the mucosa of paranasal sinuses outlets. This area, so critical for sinus pathology, and referred to as the ostiomeatal complex <sup>(3)</sup>

### **Nasal polyposis**

Nasal polyps are the oedematous sino-nasal mucosa prolapsing into the nasal cavity. Simple nasal polyps are part of the spectrum of chronic rhinosinusitis and are formed by the sino-nasal lining becoming progressively more inflamed and thicker and then pedunculating into the nasal cavity <sup>(4)</sup>

### Site of polyp formation:

Polyps usually arise from the lateral nasal wall in the middle meatus or sphenoidal recess. Those polyps that originate lateral to the middle turbinate usually take their origin from the frontal, anterior ethmoid, or maxillary sinuses. Polyps medial to the middle turbinate are usually arising from the posterior ethmoid or sphenoid sinuses. In rare cases, polyps may originate on the nasal septum or from the olfactory cleft <sup>(5)</sup>

### Diagnosis and staging

## **Rhinoscopy**

Large polyps can be identified by simple anterior rhinoscopy. In contrast to a hyperplastic turbinate, a polyp can be made to move by touching with a probe, mainly senseless and not bleed in touch. Endoscopic examination with a rigid scope is the preferred examination, as it can diagnose even small polyps in the middle meatus and give a good assessment of the extent of the disease and of anatomical abnormalities. Endoscopy is useful, not only for the diagnosis, but also for follow-up examination after medical and surgical treatment, and for staging of the disease <sup>(3)</sup>

### Imaging

CT scan of the nose and paranasal sinuses gives a demonstration of the anatomy and even pathology. It is indicated when there is a suspicion of malignancy or meningocoele, and also in all cases before endoscopic surgery. In addition, it is used for staging of the disease <sup>(3)</sup>

## TREATMENT

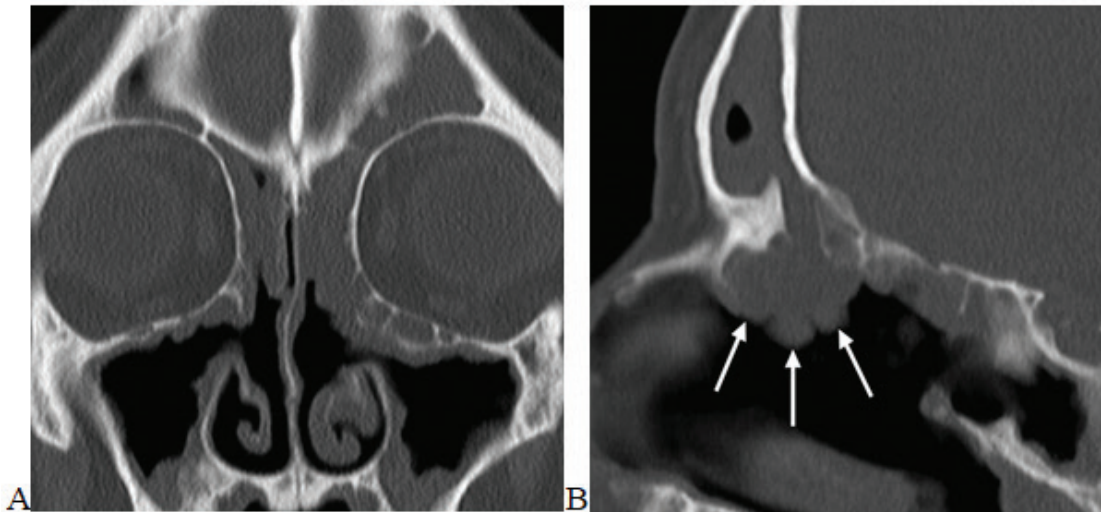
Intranasal and systemic steroids are the most common treatments for the management of nasal polyps. Endoscopic surgery is reserved for severe nasal obstruction resistant to maximal medical therapy. Nasal polyps tend to be more severe and refractory to medical and surgical treatment, especially in the subset of aspirin-sensitive asthmatics <sup>(5)</sup>

### **Endoscopic polypectomy**

For large nasal polyps or patients that fail medical treatment, endoscopic polypectomy with the microdebrider is performed <sup>(4)</sup>

### Nasal polyposis recurrence

The recurrence of NP after the sinonasal surgery is prevalent but the frequency and intensity of relapse vary based on multiple factors: Medical factors, environmental factor like smoking and iatrogenic factors <sup>(6)</sup>



**Fig. (1): (A) coronal CT scan of patient with Samter's triad showing recurrence of polyps after FESS <sup>(7)</sup> (B) Sagittal CT scan of polyps recurrence <sup>(7)</sup>**

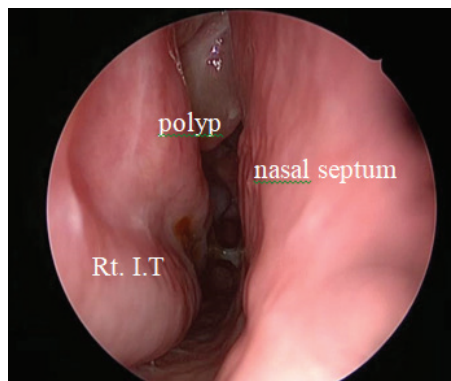
### Patients and Methods

All 30 patients in this study had previously undergone bilateral primary FESS procedure for CRSwNP. Independent variables which were assessed included patients name, age, gender, history of nasal obstruction, purulent nasal discharge, post nasal drip, facial pain, anosmia, headache, History of asthma and aspirin sensitivity and allergic fungal sinusitis.

patients information were collected from outpatient, inpatient notes and primary FESS reports.

Nasal endoscopy using 0,70 degree Hopkins rod nasal endoscope for assessment of the nasal polyp by using Lund and Kennedy score for presence of polyps, edema, scarring, crusting and discharge.

Each side was graded separately, and the scores for each side were collected to determine the overall endoscopy score.



**Fig. (2): Endoscopic examination of Rt. Nasal cavity by 0o endoscope.**

Prior to revision surgery, prescription of maximal medical therapy for each patient included:

- Ø Systemic oral steroid (0.5 mg/kg/d) for 5-10 days in case of massive polyposis.
- Ø Local corticosteroid (budesonide) spray.
- Ø Antihistamines for patients with history of allergy.

Ø Macrolide antibiotics (azithromycin tab. 500 mg. once daily for 3 days).

Ø Saline irrigations.

Medical treatment was given for 3-6 weeks before undergoing a preoperative CT scan and another endoscopy were done.

Revision ESS considered after one month of medical treatment failed.

All patients had preoperative computed tomography (CT) scans of the nose and paranasal sinuses (coronal , axial and sagittal) and scoring done according to Lund McKay scoring system.

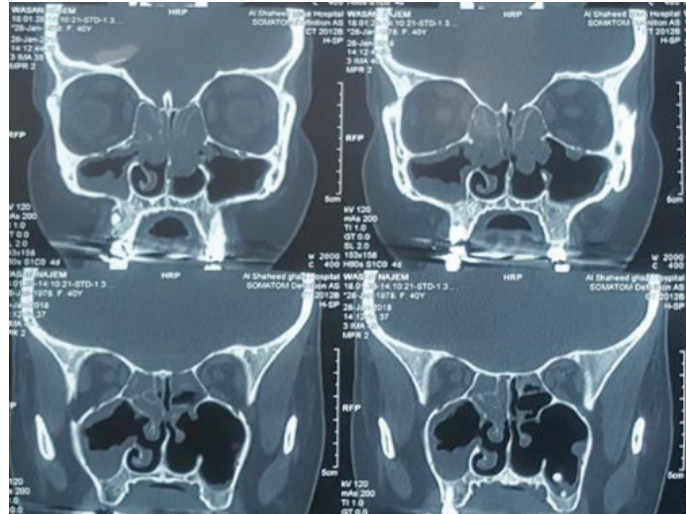


Fig. (3): CT-scan coronal sections of patient with recurrent nasal polyps after FESS

Table (1): Anatomical findings sheet:

<b>Patient name:</b> _____ <b>age:</b> _____		
<b>Anatomic findings</b>	<b>Rt side (0-1)</b>	<b>Lft side (0-1)</b>
<b>septal deviation</b>		
<b>middle turbinate lateralization</b>		
<b>residual uncinate process</b>		
<b>residual Haller (infraorbital) cells</b>		
<b>Onodi (sphenoidal) cells</b>		
<b>residual cells in the frontal recess (agger nasi or frontoethmoidal cells)</b>		
<b>MMA stenosis</b>		
<b>Incomplete anterior ethmoidectomy</b>		
<b>Incomplete posterior ethmoidectomy</b>		
<b>sphenoid sinus and its ostium</b>		
<b>concha bullosa (missed or incompletely opened)</b>		
<b>For each finding the incidence is identified in all patients included in the study</b>		

Surgical procedure:

In reverse trendelenberg position, head elevation up to 30 degree , bilateral otrivin packs was inserted for about 10 minutes as to decrease congestion.

We used 0 degree nasal rigid endoscopes and endoscopic nasal suction tip, to remove polyps from the nasal cavity by using microdebrider and Blakesely weil cupped forceps, multiple pieces taken as biopsy.

After identification of remaining landmarks, we

started removal of polyp and access all involved sinuses and remove the polyp as can as possible.

Correction of any anatomical abnormality if present like (septal deviation , middle turbinate lateralization, residual uncinat process, and other anatomical findings. then irrigation of the nasal cavity with normal saline and suction.

This follow up was done by examination of the nasal cavity endoscopically using 0, 70 degree angles, bilateral three passes nasal endoscopic examination done to identify edema, discharge, synechia, crust and recurrence of nasal polyposis.

**Result**

Gender:

male to female ratio was 1.5:1.

Symptoms (chief complaint)

There were no dominant symptoms.

Asthma, aspirin sensitivity and AFRS

some patients associated with asthma , aspirin sensitivity and allergic fungal rhinosinusitis as shown in Fig.(21)

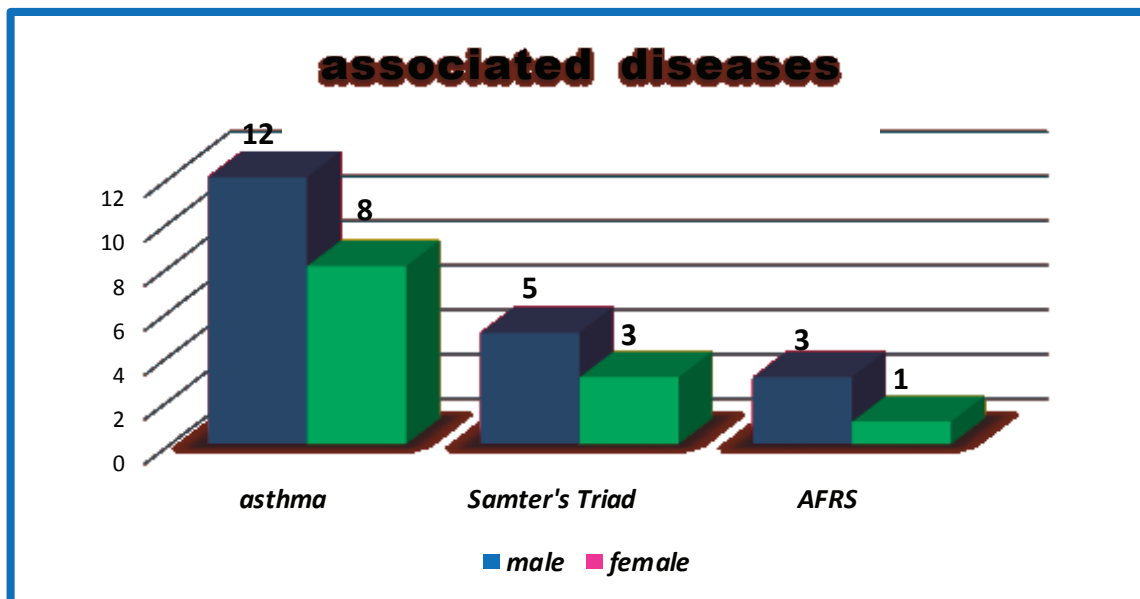


Fig.(4) patients numbers according to associated diseases.(asthma, aspirin sensitivity and AFRS).

Date of primary surgery

Our patients did the primary surgery in different times. The oldest one in 2010 and the newest one in 2016 so we divided the patients in to 3 groups according to the year of primary surgery.

We found that the largest number of the patients in our study did the primary surgery in the years between 2014 and 2016, that mean NP recurrence occurs mainly (1-3 years) after surgery

Effect of post-operative steroid

We found that patients those received steroid (local or systemic) after primary surgery showed delay in polyp recurrence.

Anatomical findings.

In some patients we found anatomical variations in CT scan and intra-operatively.

Incomplete anterior and post. ethmoidectomy had the largest percentage.

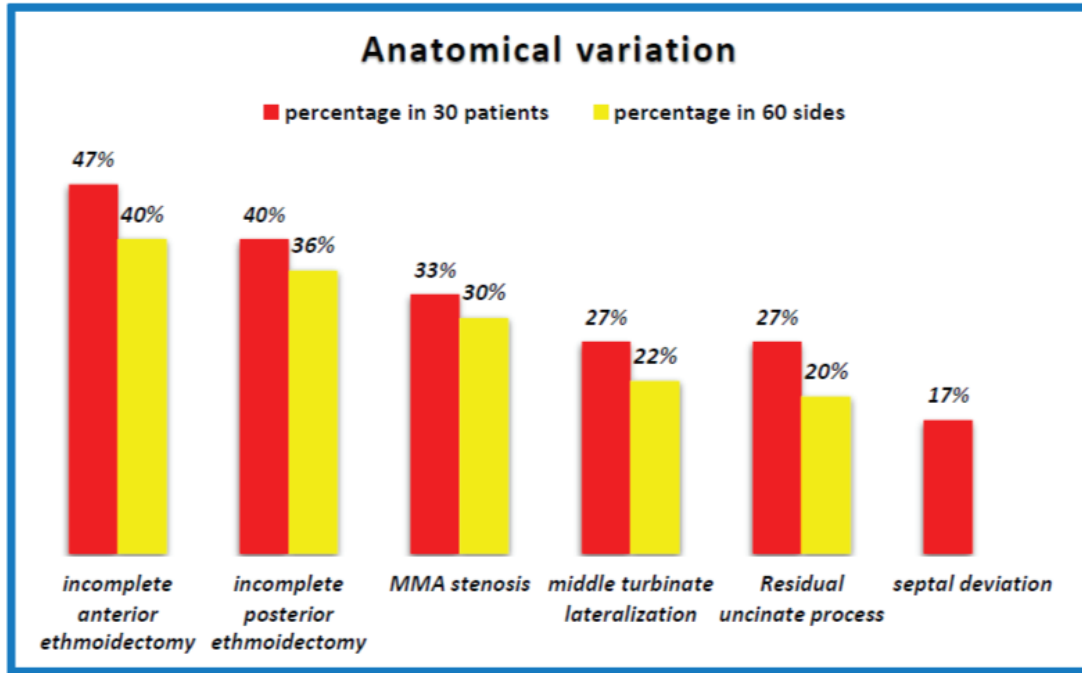


Fig. (5) Percentages of anatomical variations.

**Discussion**

Gender and age distribution

In our results male to female ratio was 1.5:1 just like what found by Manpreet Singh Nanda et al. when most patients were within the middle age group and M: F ratio of 1.6:1 (8) but not goes with Shabbir Akhtar et al. that showed the recurrences in 36 patients from 192 patients, and no association between polyp recurrence

age, gender (9)

Symptoms:

In our result there were no dominant symptoms just like Studies done by Shabbir Akhtar et al. showed recurrences developed in 36 patients. No association of recurrence with sinonasal symptoms (9)

Also Adam S. DeConde et al. studied the factors may related to nasal polyp recurrence and addressed

nasal symptom among these factors and found that there was no clinical risk factors for that <sup>(10)</sup>

#### Asthma, aspirin sensitivity with ct-scan and endoscopic finding

Wynn et al. in study patients with severe polyposis, they found (50%) patients had asthma <sup>(11)</sup> and this goes with our results.

In the study done by Fereshteh Esmatinia and Mahdi Bakhshaei, 80% of patients with asthma who had been underwent the ESS revealed the Sino-nasal polyposis recurrence <sup>(12)</sup> And this goes with but higher than our results.

AFRS: Study done by Younis RT, Ahmed J. found that patients with polyps in AFRS had high Lund-Mackay score and had higher revision rates. This does with our result <sup>(13)</sup>

Study done by Laila M. Telmesani showed there was a significant direct relationship between the CT grading of nasal polyps and polyp recurrence in nasal polyposis with and without AFRS <sup>(14)</sup> this goes with our results.

Figen Aslan et al. found the mean Lund–MacKay CT score and the mean Lund–Kennedy endoscopic score were significantly higher in patients with AFRS <sup>(15)</sup> And this consistent with our results

#### Date of primary surgery and recurrence

We found that the largest number of the patients in our study did the primary surgery 1-3 years after primary surgery. (The most recent period).

In study done by DeConde AS et al. Polyp recurrence is common after ESS, and the high recurrence rate (60%-70%) occurred just post-operative up to 18 month <sup>(10)</sup> and this goes with our result. In Yaniv Eitan et al. from 148 patients underwent FESS, polyp recurrence occurred in 74 patients in the first 2 years after surgery and an additional 17 in the next 3-4 years. During the following years, the recurrence rate was lower <sup>(16)</sup> and this also goes with our result.

Pär Stjärne et al. found the recurrence occur mainly about one year after primary surgery and this result consistent with our result <sup>(17)</sup>

#### Effect of post-operative steroid on polyp recurrence rate

Esmatinia et al. only 46% of patients consumed beclomethasone dipropionate, revealed the NP regrowth which was lower than the 87% of patients in placebo group that revealed recurrence of NP <sup>(12)</sup>

Fandiño C. et al. they found using of intranasal corticosteroid showed significant improvement in polyp score <sup>(18)</sup>

#### Anatomical findings

During examination of our patient by endoscopy and using of CT scan and intraoperative we found that some patients had anatomical variations contribute in failure of primary surgery and we documented that as an incidence in bilateral assessed sides and found: Incomplete anterior ethmoidectomy in 40%, Incomplete posterior ethmoidectomy in 36%, MMA stenosis in 30 %, Middle turbinate lateralization in 22%, Residual uncinate process in 20%, Septal deviation in 17%.

Khalil et al. They found residual anterior and posterior ethmoid cells in 97% and 92% of patients, respectively (96% and 92% of sides, respectively) <sup>(19)</sup>

Ramadan et al. reported a series of 52 patients prepared for revision FESS, among these, he observed (residual uncinate) in 15% <sup>(20)</sup>

Adam S. DeConde et al. mentioned that the examination of the association between surgical extent and polyp recurrence in a previous single institution cohort study found that more extensive surgery was protective against polyp recurrence <sup>(10)</sup> and this goes with our result.

### **Conclusion**

ü Most of nasal polyposis recurrence occurs in (1-3 years) after FESS.

ü Asthma, aspirin sensitivity (Samter's triad) and allergic fungal sinusitis were the most important associated diseases.

ü CT-scan of patient with recurrent nasal polyposis showed some anatomical variations from the primary surgery, incomplete anterior and posterior

ethmoidectomy showed the highest percentages.

ü According to the date of primary surgery, patients who received post-operative steroid showed delay in time of recurrence unlike other patients who did not receive steroid so recurrence appeared earlier.

ü Medical treatment post-operative is mandatory by nasal wash, local steroid and close follow up to decrease the rate of recurrence.

### Recommendations

ü Meticulous dissection during surgery and wide surgical exposure of nasal sinuses and removal of polypoidal mucosa are the most important points for successful surgical removal and decrease of polyp recurrence.

ü Post-operative regular and frequent follow-up is important to assess operative field for any infection, edema, crust and polyp recurrence.

ü We recommend use of post-operative steroid which showed to be so important to decrease the chance of nasal polyposis recurrence or even delay the recurrence.

ü Further study of large number of patients and long time is needed to show other etiological factors and possible ways to prevent or decrease polyp recurrence.

**Source of Funding:** Self-source

**Ethical Clearance:** Taken From Iraqi board for medical specializations in otolaryngology.

**Conflict of Interest:** Nil

### References

1. Watkinson JC, Clarke RW, Clark LJ, et al. Scott-Brown's Otorhinolaryngology Head and Neck Surgery. 8th edition. 2018; 95:1038-1043.
2. Balasubramanian T. M.S. D.L.O. Embryology of nose and paranasal sinuses. drtbalu's Otolaryngology online. Available at: [http://www.drtbalu.co.in/emb\\_nose.html](http://www.drtbalu.co.in/emb_nose.html). oct.2018
3. Gleeson M, Browning GG, Burton MJ, et al. Scott-Brown's Otorhinolaryngology, Head and Neck Surgery. 7th edition. 2008; 121:1549-1559.
4. Warner G, Burgess AS, Patel S, Devesa PM, Corbridge R. OXFORD SPECIALIST HANDBOOKS Otolaryngology and Head and Neck Surgery. 2009; 21: 580-581.
5. Johnson JT, Rosen CA, Newlands SD, et al. Bailey's Head and Neck Surgery otolaryngology. 5th edition. 2014; 34:527.
6. LIN HW, Roberts DS, Harris JP, Cummings CW. Cummings review of otolaryngology. 2017; 4: 54-74.
7. Huang BY, Lloyd KM, DelGaudio JM, Jablonowski E, Hudgins PA . Failed Endoscopic Sinus Surgery: Spectrum of CT Findings in the Frontal Recess. RadioGraphics Vol. 29, No. 1. Jan 1 2009. Available at <https://doi.org/10.1148/rg.291085118>.
8. Nanda MS et al. Int J Otorhinolaryngol Head Neck Surg. 2017 Jan;3(1):77-81
9. Akhtar S., Ikram M., Azam I., Dahri T. (2010). Factors associated with recurrent nasal polyps: a tertiary care experience. Journal of the Pakistan Medical Association, 60(2), 102-4.
10. DeConde AS, Mace JC, Levy JM, Rudmik L, Alt JA, Smith TL. Prevalence of polyp recurrence after endoscopic sinus surgery for chronic rhinosinusitis with nasal polyposis. Laryngoscope. 2016;127(3):550-555.
11. Wynn R., Har-El G. Recurrence rates after endoscopic sinus surgery for massive sinus polyposis. Laryngoscope. 2004;114:811-813.
12. Esmatinia F, Bakhshaei M. Recurrent sinonasal polyposis after the endoscopic sinus surgery. Rev Clin Med.2014;1(2):86-92.
13. Younis RT, Ahmed J. Predicting revision sinus surgery in allergic fungal and eosinophilic mucin chronic rhinosinusitis. Pubmed. Laryngoscope. 2017 Jan;127(1):59-63. Available at <https://www.ncbi.nlm.nih.gov/pubmed/27577717>
14. Telmesani LM. Prevalence of allergic fungal sinusitis among patients with nasal polyps. Ann Saudi Med. 2009;29(3):212-4. Available at: <https://www.ncbi.nlm.nih.gov/pmc/articles/PMC2813658>.
15. Aslan F, Altun E, Paksoy S, Turan G. Could Eosinophilia predict clinical severity in nasal polyps?. Multidiscip Respir Med. 2017;12:21. Published 2017 Aug 21.doi:10.1186/s40248-017-0102-7.
16. Eitan Y, Jacob S, Tamara D, Rami T, Tuvia H.

- Recurrence of nasal polyposis after functional endoscopic sinus surgery. Available at <http://www.conexiunimedical.ro/fisiere/0108.pdf>. Sept.2018 .
17. Stjärne P, Olsson P, Ålenius M. Use of Mometasone Furoate to Prevent Polyp Relapse After Endoscopic Sinus Surgery. *Arch Otolaryngol Head Neck Surg.* 2009;135(3):296–302. doi:10.1001/archoto.2009.2.
  18. Fandiño CM, Macdonald KI, Lee J, Witterick IJ. The use of postoperative topical corticosteroids in chronic rhinosinusitis with nasal polyps: A systematic review and meta-analysis. *American Journal of Rhinology & Allergy.* 2013;27(5):e146-e157. doi:10.2500/ajra.2013.27.3950.
  19. Khalil HS, Eweiss AZ, Clifton N. Radiological findings in patients undergoing revision endoscopic sinus surgery: a retrospective case series study. *BMC Ear Nose Throat Disord.* 2011;11:4.
  20. Ramadan HH. Surgical causes of failure in endoscopic sinus surgery. *Laryngoscope* 1999;109:27-9.