

Canine-premolar Transposition, Family Pedigree and Related Dental Anomalies

Mushriq Abid¹, Samher A. Al-Shaham², Zaynab MR. Al-Chalabi³

¹Assistant Professor at the Department of Orthodontics/College of Dentistry/University of Baghdad,

²Lecturer at the Department of Orthodontics/College of Dentistry/University of Baghdad,

³Orthodontists Specialist at the Ministry of Health-Iraq

Abstract

Maxillary canine-premolar transposition is a rare and complicated dental anomaly that needs special consideration by the orthodontist. The aim of the present study was to investigate the clinical features of maxillary canine-premolar transposition and report the family pedigree to determine the mode of inheritance. A cross-sectional study was performed on 39 patients having maxillary canine-premolar transposition in which both clinical and radiographic examination were performed. Moreover, 112 family members were clinically examined looking for canine transposition. Variables such as location, sex and the presence of hypodontia and peg-shaped lateral incisors were investigated. The study found that unilateral transposition (89.7%) was more common than bilateral occurrence (10.2%) affecting the left side (64.1%) more than the right side (35.9%). Females were affected more than males (74.4% and 25.6% respectively). Congenitally missing teeth were reported in 12.8% and lower second premolar was the most commonly missing tooth. Peg-shaped maxillary lateral incisor was reported in 7.7% of the sample. Family pedigree confirmed the presence of a history of transposition or ectopically positioned canine in 15.3% of the sample suggesting an autosomal dominant inheritance of the trait. In conclusion this study suggested an association between genetic factors and maxillary canine-premolar transposition. Further studies are required using genetic testing to confirm the findings of the present study.

Keywords: Canine, Transposition, genetic, dental anomaly, peg-shaped, hypodontia

Introduction

Transposition of teeth is a rare condition which has a serious impact on the occlusion and is defined as a positional interchange between two adjacent teeth¹. Previously research provided important information on the prevalence of this anomaly which varies depending on the population featuring very low incidence (0.2-0.5%)²⁻⁵.

Gender differences have been reported in different studies and are still unclear. Some research reported

no gender difference⁶, while others reported female predominance over males⁴, though conversely some studies reported more affected males than females⁷. Transposition is more frequently observed in the maxilla than the mandible⁸, moreover canine-premolar transposition is the most frequent type⁴, and unilateral presentation is more frequent than bilateral⁹.

To date several theories have been proposed to be the causative factor of transposition such as trauma¹⁰, early loss of teeth¹¹, positional interchange of the developing tooth bud¹², space deficiency¹³ and genetic factors^{3,4,10}. Genetic aetiology has been confirmed by unilateral left-sided occurrence¹, hypodontia^{7,11}, retained deciduous teeth¹¹, peg-shaped lateral incisor¹. For these reasons genetic factors have been suggested to be the fundamental aetiology of dental transposition¹.

Corresponding Author:

Mushriq F. Abid

Address: College of Dentistry/University of Baghdad-
Baghdad-Iraq

E-mail: mushriq.abid@codental.uobaghdad.edu.iq

To our knowledge there have been few studies which reported various types of transposition and the associated dental anomalies beside reporting family pedigree looking for a family history of this dental anomaly. The aim of the present study was to investigate the clinical features of maxillary canine-premolar transposition and report the family pedigree to determine the mode of inheritance.

Methods

A total of 39 patients demonstrating maxillary canine and premolar transposition consisted of 10 males and 29 females (Table 1) with age range of 13-18 years at the time of diagnosis (mean age 13.7 years). No history of craniofacial anomalies or trauma was noted for all the participants. 112 family members were clinically examined looking for canine transposition and ectopic tooth position. The study population were collected from several private clinics in Baghdad city and the Orthodontic Department at the College of Dentistry/ Baghdad University. The study was approved by a local committee in the Orthodontic Department at the College of Dentistry (Baghdad University).

The study focused on patients with maxillary canine-premolar transposition (unilateral or bilateral) who have not received any orthodontic treatment. The patients were clinically and radiographically examined using panoramic dental radiograph.

The following variables were reported:

- 1) The location of transposition, bilateral or unilateral.
- 2) Age at diagnosis.
- 3) The presence of missing teeth (hypodontia).
- 4) The presence of diminutive (peg-shaped) lateral incisor.
- 5) Family pedigree was recorded for each patients looking for a family history of transposition of teeth or

ectopically erupted maxillary tooth.

Panoramic dental radiographs were available for all the patients at the time of diagnosis. They were used to confirm the presence of canine-premolar transposition, missing teeth excluding the third molar and peg-shaped lateral incisor. A lateral incisor was considered peg-shaped when the mesiodistal width at the cervical region was greater than the incisal edge¹⁴. Descriptive statistics were used to define the characteristics of the study variables through the form of counts and percentages.

Results

A total of 39 patients with maxillary canine-premolar transposition (Figure 1) was examined both clinically and radiographically looking for the location and side of transposition and the presence of hypodontia or diminutive maxillary lateral incisor. The results revealed that unilateral transposition (n=35, 89.7%) was by far more common than bilateral transposition (n=4, 10.2%). In unilateral transposition left-sided occurrence (n=25, 64.1%) was more prevalent than right-sided (n=14, 35.9%). Unilateral occurrence was more common in females (n=25, 71.4%) than males (n=10, 28.6%). Similarly, left side occurrence was more common in females (n=17, 68%). Five of the 39 patients had congenitally missing teeth (12.8%) excluding the third molar. The lower second premolar was most frequently missing (three cases) followed by the maxillary lateral incisor. Peg-shaped maxillary lateral incisor was observed in three cases (7.7%), in some instances reduced sized lateral incisors were not recorded, since these small-sized teeth were not severe to fit the definition of peg-shaped teeth.

The family pedigree was also reported for other family members and first and second generation of the proband. The results revealed a family history of transposition or ectopically positioned maxillary canine was found in six families (15.3%). Two confirmed a similar condition in siblings while the other four mentioned an ectopically positioned tooth in a family member (Figure 2).

Table 1: Descriptive statistics of the sample.

Variable		(n, %)		(n, %)	
Location	Unilateral	(35, 89.7%)	Unilateral	Male	(10, 28.6%)
	Bilateral	(4, 10.2%)		Female	(25, 71.4%)
Side	Left	(25, 64.1%)	Left	Male	(8, 32%)
	Right	(14, 35.9%)		Female	(17, 68%)
Gender	Male	(10, 25.6%)			
	Female	(29, 74.4%)			
Congenitally missing tooth	Present	(5, 12.8%)	Affected tooth	Lower second premolar	(3, 60%)
	Not present	(34, 87.2%)		Maxillary lateral incisor	(2, 40%)
Peg-shaped lateral incisor	Present	(3, 7.7%)			
	Not present	(36, 92.3%)			

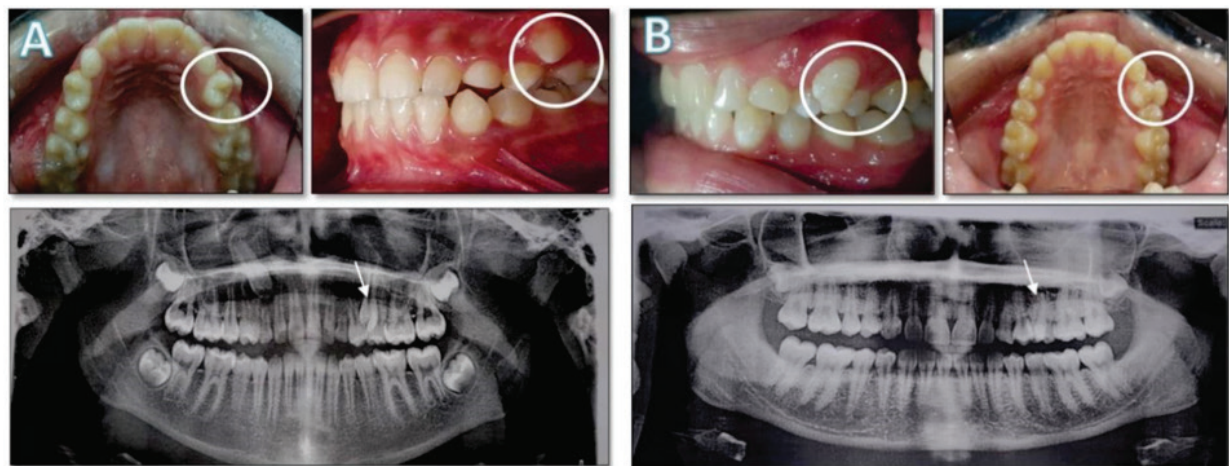


Figure 1: Intraoral photograph and panoramic radiograph showing transposition A) 12-year-old female with transposition in the maxillary left canine-premolar (encircled and arrowed). B) 16-year-old female with transposition in the maxillary left canine-premolar (encircled and arrowed).

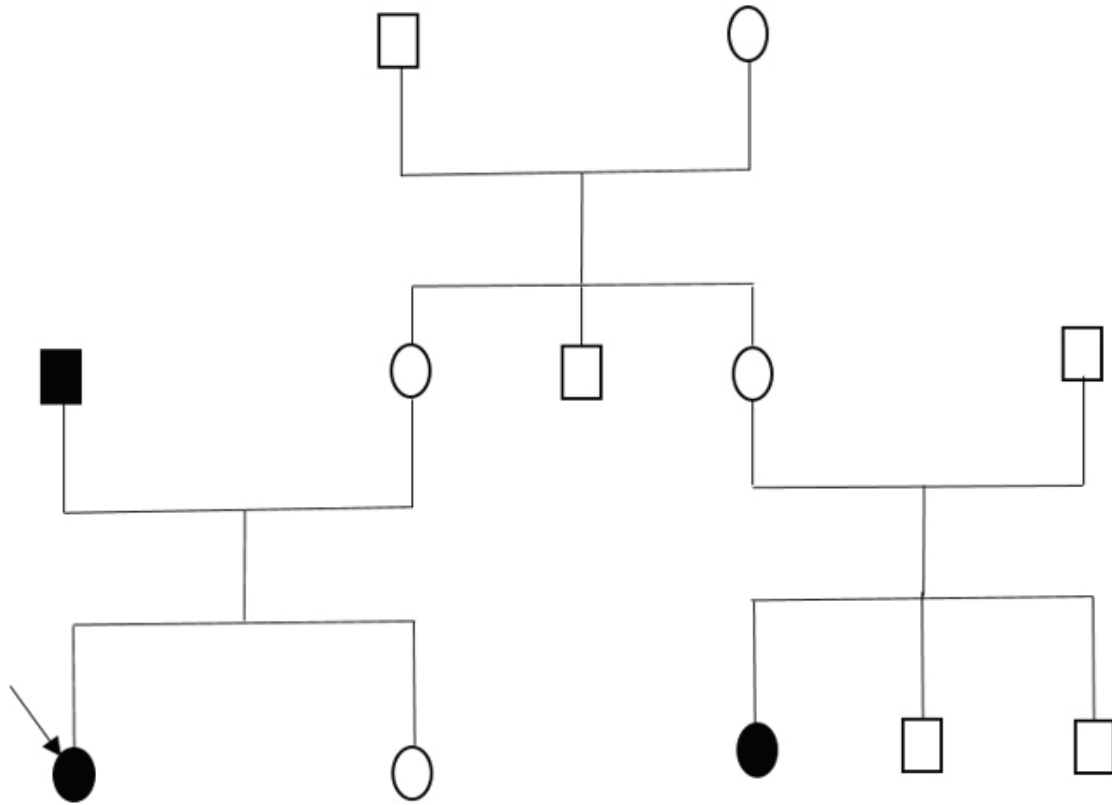


Figure 2: Family pedigree of a patients showing other affected family members. Empty circle=female, empty square=male, filled circle=affected female and arrow=proband.

Discussion

The present study focused on 39 patients with maxillary canine-premolar transposition who were clinically and radiographically examined. Previous studies reported that transposition most commonly occurred in the maxilla and canine-premolar teeth are most commonly involved^{1,3,7,11}. Unilateral transposition was found to be more common than bilateral transposition which agree with other studies^{1,3,8,11}. In bilateral cases, the same teeth were affected by the transposition which agrees with Al-Shawaf^{8,15}. Left-sided occurrence was 64.1% which was comparable to what was reported by Peck et al¹.

Females were affected more by transposition when compared to males which was reported by most previous studies^{1,8}. This phenomenon is not explained however, some reports of other anomalies such as cleft lip and palate found a left-side occurrence to be more

common than right-side¹⁶ and is dependent on the diagnostic procedure used. In this study we determined the prevalence of associated anomalies in patients with a cleft lip and/or palate, with a specific focus on cardiac anomalies. Materials and Methods: In this cross-sectional study, 526 patients with a cleft lip and/or palate admitted to the children's referral hospital between 2006 and 2011 were evaluated. All associated anomalies were detected and recorded. Patient information collected included age, gender, type and side of cleft, craniofacial anomalies and presence of other anomalies, including cardiac anomalies. Data were analyzed using SPSS version 16. Results: Of the 526 patients enrolled in the study, 58% (305). Previous studies suggested the occurrence of maxillary canine-premolar transposition in girls more than boys¹⁷. Nevertheless, research has reported that most orthodontic practice patients are females¹⁸. For this reason, higher prevalence of females with transposition cannot be accounted for in comparison to males.

The prevalence of hypodontia excluding the third molar is 12.8% and in the present study was twice as common as in the general population¹⁹. Similarly, peg-shaped lateral prevalence was 7.7% twice as common as in patients with no teeth transposition²⁰. Most of previous studies reported higher prevalence of dental anomalies including hypodontia and peg-shaped maxillary lateral incisors when compared to the figures found in the present study which could be attributed to the sample size and ethnicity^{1,8}.

Interestingly, the present study reported the family pedigree for each patient, 15.3% confirmed the presence of ectopically positioned tooth or transposition. This finding could support the genetic aetiology of transposition together with the presence of dental anomalies. The pedigree suggested an autosomal dominant inheritance of the trait. Ely et al. reported that transposition is caused by both genetic and environmental factors based on the findings of their study⁸. They supported their point by the fact that there was no previous study which reported a mutation in patients with transposition. Moreover, transposition may arise from developmental disturbances in the developing tooth dental follicle or genes that are involved in the development of dentition.

The limitations of the present study include no inferential statistics being performed due to the sample size. One of the strongest points in the present study is that the study focused on one type of transposition rather than different types of this anomaly which was seldom in previous studies.

Conclusions

The result of the present study suggested that genetics might play a role in the aetiology of maxillary canine-premolar transposition. This finding could be helpful to clinicians and can be supported by the utilization of recent technology including next-generation sequencing. Further large-scale studies are needed including larger sample and different types of transposition.

Source(s) of support: The study was self-funded.

Conflicting Interest: The authors declare no conflict of interest.

This study was approved by a local ethics committee in the Department of Orthodontics,

College of Dentistry, University of Baghdad.

References

1. Peck L, Peck S, Attia A. Maxillary canine-first premolar transposition, associated dental anomalies and genetic basis. *The Angle orthodontist*. 1993;63(2):99-109.
2. Burnett S. Prevalence of maxillary canine-first premolar transposition in a composite African sample. *Angle Orthod*. 1999;69(2):187-189.
3. Peck S, Peck L. Classification of maxillary tooth transpositions. *Am J Orthod Dentofac Orthop*. 1995;107(5):505-517. doi:10.1016/S0889-5406(95)70118-4
4. Chattopadhyay A, Srinivas K. Transposition of teeth and genetic etiology. *Angle Orthod*. 1996;66:147-152.
5. Sandham A, Harvie H. Ectopic eruption of the maxillary canine resulting in transposition with adjacent teeth. *Tandlaegebladet*. 1985;89:9-11.
6. Shapira Y, Kufinec M, Stom D. Maxillary canine-lateral incisor transposition—orthodontic management. *Am J Orthod Dentofac Orthop*. 1989;95:439-444.
7. Plunkett D, Dysart P, Kardos T. A study of transposed canines in a sample of orthodontic patients. *Br J Orthod*. 1998;25:203-208.
8. Ely N, Sherriff M, Cobourne M. Dental transposition as a disorder of genetic origin. *Eur J Orthod*. 2006;28:145-151.
9. Calpan D. Transposition of the maxillary canine and the lateral incisor. *Dent Pract Dent Rec*. 1972;22:307.
10. Weeks E, Power S. The presentations and management of transposed teeth. *Br Dent J*. 1996;181:421-424.
11. Shapira Y, Kufinec M. Maxillary tooth transpositions: characteristic features and accompanying dental anomalies. *Am J Orthod Dentofac Orthop*. 2001;119:127-134.
12. Laptok T, Silling G. Canine transposition—approaches to treatment. *J Am Dent Assoc*. 1983;107:746-758.
13. Jacoby H. The etiology of maxillary canine impactions. *Am J Orthod*. 1983;84:125-132.
14. Becker A, Smith P, Behar R. The incidence of anomalous lateral incisors in relation to palatally-

- displaced cuspids. *Angle Orthod.* 1981;51:24-49.
15. Al-Shawaf M. Bilateral asymmetrical transposition of teeth. *Ann Dent.* 1988;47:41-42.
 16. Fakhim SA, Shahidi N, Lotfi A. Prevalence of associated anomalies in cleft lip and/or palate patients. *Iran J Otorhinolaryngol.* 2016;28(2):135-139. doi:10.22038/ijorl.2016.6544
 17. Dahl T. Uber die transposition von zahnen. *Zahn Mund Kieferheilk.* 1976;76:267-270.
 18. Ringqvist M, Thilander B. The frequency of hypodontia in an orthodontic material. *Sven Tandlak Tidskr.* 1969;62:535-541.
 19. Khalaf K, Miskelly J, Voge E, Macfarlane T V. Prevalence of hypodontia and associated factors: a systematic review and meta-analysis. *J Orthod.* 2014;41:299-316.
 20. Baral R, Bajracharya D, Ojha B, Silwal G. Prevalence of Congenitally Missing Lateral Incisors and Peg Laterals in Patients Receiving Orthodontic Treatment. *Orthod J Nepal.* 2020;10(1):17-20. doi:10.3126/ojn.v10i1.30998