

# Successful Biological Treatment of Cutaneous wound Healing with Comparation of Aqueous Humour Fluid and Fat Graft; Cattle as Model

Qayes Taref Ali<sup>1</sup>, Muslem Fahim Diwan<sup>1</sup>, Amir I. Towfik<sup>2</sup>

<sup>1</sup>Lecturer, <sup>2</sup>Assistance Prof, College of Veterinary Medicine, University of Al-Qadisiyah, AlDewaniyah, Iraq

## Abstract

Aqueous humour fluid and fat graft effect on wound healing by containing growth factors. **Aim** of this study to evaluate the benefit effect of aqueous humour fluid and fat graft in wound healing in cattle. Twenty seven adult female local breed randomly divided into 3 equal groups. G1 have been treated by aqueous fluid, G2 treated with fat graft, while the last group ( control group ) left without treatment. **In conclusion** fat graft treated group appear better healing during study period compare with other groups.

**Keyword:** aqueous humour fluid, fat graft, wound healing

## Introduction

Wound is known as degradation integrity of epithelial tissue, wound healing is a four stages complex biological process <sup>(1)</sup>. Skin wound healing is a cellular function mechanism involving the interaction of several cells, growth factors and cytokines, there are many techniques used to overcome wound healing limitation, new techniques that used for treatment wound involving scaffolds activation by bioactive molecule, growth factor and genetically modified cells <sup>(2)</sup>. Two of these techniques are fat graft with their adipose-derived stem cells <sup>(3)</sup>, and use of aqueous humour fluid<sup>(4)</sup>.

Fat grafting is a common procedure in plastic and reconstructive surgery because of it is low cost, ease of harvest, safety, and high content of stem cells and growth factors<sup>(5)</sup>, also adipose tissue is available in large amount and easy to manipulate <sup>(6)</sup>. Fat grafting used in many purposes including lower limb ulcers <sup>(7)</sup>, improve healing of burns <sup>(8)</sup>, softening of surgical scars <sup>(9)</sup> and in wound healing <sup>(5)</sup>. Adipose tissue contain stem cells, secret anti-inflammatory mediator and growth factors <sup>(10)</sup>, this stem cells contributing in wound healing by

differentiated to various phenotypes wound healing cells such as keratinocytes, fibroblast and endothelial cells <sup>(11)</sup>, also encourage neovascularization and tissue regeneration <sup>(12)</sup>, this lead to suggest use fat in wound healing. Adipose derived stem cells differ from other mesenchymal stem cells by that it can be harvested with minimum donor site morbidity and without ex vivo culturing and expansion <sup>(13)</sup>. The other biological method used to overcome wound healing limitation is aqueous humour fluid, it is contain number of growth factors, cytokines capable of effecting fibroblast activity and wound healing<sup>(14)</sup>. Growth factors formed in the corneal cells in the eyes such as epidermal growth factor, transforming growth factor and keratinocyte growth factor then secreted them in the aqueous humour fluid and tear to maintain and renewal of normal tissue <sup>(15)</sup>. Composition of aqueous humour is approximately similler to cerebrospinal fluid and arterial plasma with high ascorbate, low level of plasma, protiens and blood cells <sup>(16)</sup>. Trasforming growth factor play an imprtant role in fibrosis during wound healing <sup>(17)</sup>.

## Materials and Methods

The work was conducted on twenty seven local breed cattles, their body weights 550 ±25kg aged ±2 years. lived in the Animal field of the College of Veterinary Medicine/ University of Al-Qadisiyah under

---

**Corresponding author:**  
**Muslem Fahim Diwan**  
Muslem.diwan@qu.edu.iq

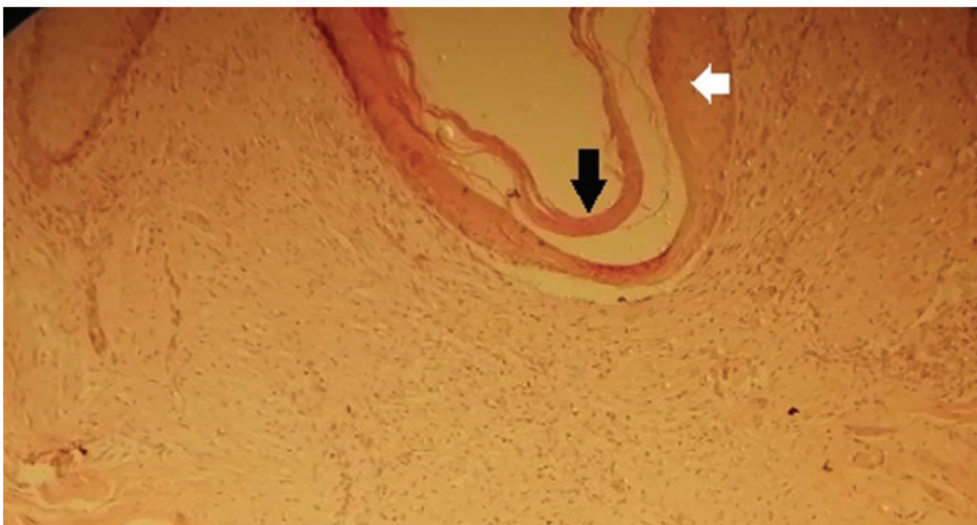standard feeding with free administration of clean water. All the procedures were accompanied with the ethics of the college committee. Animals divided randomly and equally into three groups, group 1 treated with aqueous humour fluid, group 2 treated with fat graft and group 3 leave without treatment as control group.

Fat graft (100 gm) was collected from the slaughter house of Al- Dewania/ Iraq immediately after slaughtering, immersed in 0.9% normal saline, at the same time under strict sterile conditions. Aqueous humorous fluid(AHF) (15 ML) was collected from the cow eyes after slaughtering and the two samples were preserved in ice box. and brought to the laboratory. The fat graft was washed ten times with normal saline, harvested with sharp knife and centrifuged with PBS 1% at 3000 rpm/ 5 minutes. The mid layer was collected and preserved under 4°C until used. Then we make an incision of about 1cm length in the thural area of animals in each group. G1 treated with aqueous humour fluid, 0.5ml of it locally on incision was started directly and repeated for 7 consecutive days. G2 trated with 0.5ml of fat graft and continue for 7 consecutive days.

Samples were collected from all groups at 14 and 21 days for histo-pathological examination. The histo-pathological slides were stained with hematoxiline and eosin stains and examed under light microscope (olympus Incorporation, Japan).

## Results

The histological study of G1 after 14 days post wound. There was an early stage of regeneratal layer and accumulation of inflammatory cells with fibroblast in the margin on newly formed epithelized tongue, however there was sheltered with a thin reepithelization formation of superficial crust and regenreation of epidermal layer as well as infiltration of inflammatory cells in the subepithelial area (fig.1). In 21 days post wound we reporting that slower healing wound with presence of granulation tissue below the epithelial layer also formation of new blood vessels (fig.2). In seconed group the cattle treated with fat graft,after 14 days post wound histololgic examination revealed that reepithelization regenerated epideramal layer and infiltration of inflammatory cells with formed epithelial tongue, also the wound show good regeneration of epithelial and subepithelial layers as well as infiltraion of inflammatory cells and fibroblast in the wound margin (fig.3). Like wise, in 21 days in wound area was noted that there was rapid healing of epidermis layer covered by a thin of scar tissue and formation of blood vessels due to proliferation of endothelial cell with presence of collagen (fig.4). the third untreated control group, the histological evaluation in day 14, there were afew accumulation of inflammatory cells in the sub epithelial area (fig.5). In day 21 we found that there was poor healing wound of both epidermal and subdermal layer with increase infiltration of inflammatory cell in the area (fig.6).



**Fig:1-G1( treated by aqueous humors fluid in 14 days); Skin wound shows sheltered reepithelization;**

formation of superficial crust (black arrow) and regeneration of epidermal layer (white arrow) as well as infiltration of inflammatory cells in the sub epithelial area. H&E, 100X.

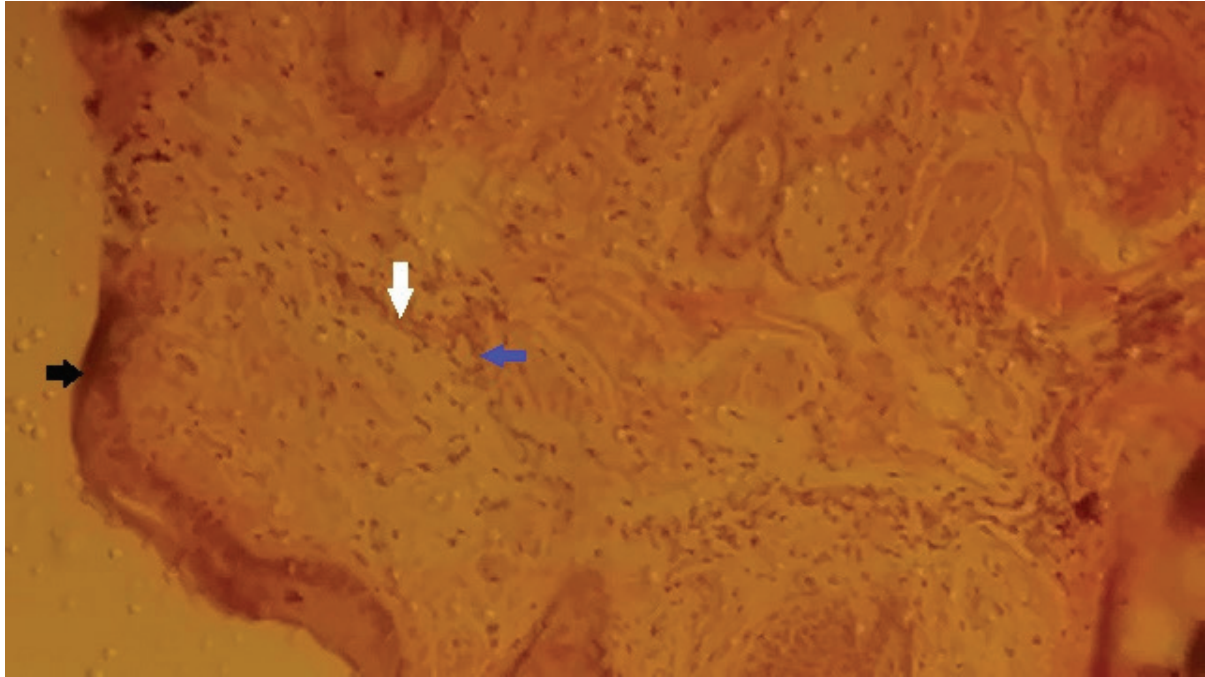


Fig:2-G1( treated with aqueous humors fluid in 21 days); Skin wound shows slower healing of epidermis layer (black arrow) and mild presence of granulation tissue as well as infiltration of few inflammatory cells (white arrows) in the sub dermal and newly formed blood vessels (blue arrow). H&E, 400X.


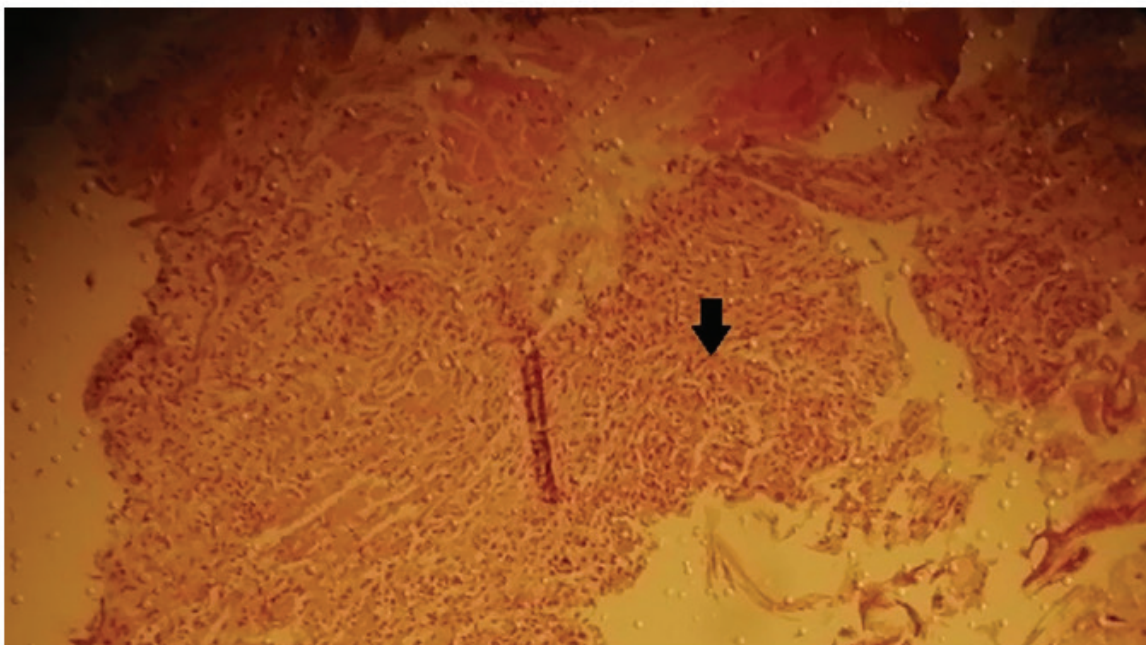


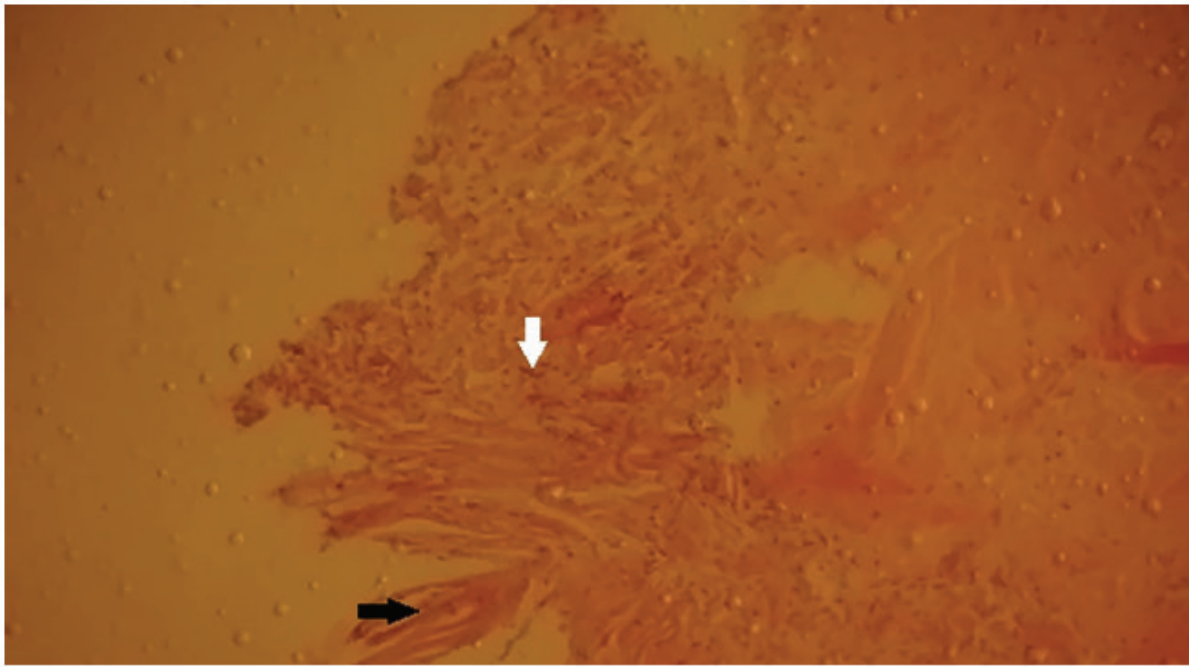
Fig:3-G2 ( treated by fat graft in 14 days); Skin wound showed in the early stage good regeneration of epithelial (black arrow)and sub epithelial layers (white arrow) as well as infiltration of inflammatory cells in the sub epithelial area (yellow arrows). H&E, 100X.



**Fig:-4-G2(treated with fat graft in 21 days); Skin wound shows rapid healing of epidermis layer (yellow arrows) covered by a thin layer of scar tissue (black arrow), and formation of blood vessels due to proliferation of endothelial cell (white arrows). H&E, 100X.**



**Fig:5-G3( control group without treated in 14 days); Skin wound shows a few accumulation of inflammatory cells in the sub epithelial area (black arrow). H&E, 100X.**



**Fig:-6- G3(control group without treated in 21 days); Skin wound shows a poor healing process of both epidermal (black arrow) and sub dermal layer (white arrow). H&E, 40X.**

### Discussion

Fat graft first used by plastic surgery in lipotrophy of the face and many studies shown that it's have a good effect on wound healing. Fat graft when used in burns reported improvement in wound healing, scar suppleness and fibrosis<sup>(18)</sup>. Which agreed with our study. Also Rahul and Sharma use fat graft in wounds and the study show significant enhancing to epithelialization from margins, production of healthy granulation tissue<sup>(8)</sup>. On the other hand aqueous humour fluid accelerated wound healing by affecting on fibroblast active also decrease scar formation<sup>(19)</sup>. The study conclude that fat graft treated group show an accelerate process of wound healing in compassion with aqueous humors fluid treated group by increase formation of blood vessels and thin scar tissue, however the two groups show better healing than control group.

**Conflict of Interest:** None

**Funding:** self

**Ethical Clearance:** Not required

### References

- 1- Ibrahem Canpolat and Alper Basa. Wound healing and current treatment techniques. *Journal of Research :agricultural & veterinary sciences*.2017, Vol.1 No.3
- 2- Erika Maria T., Rossella Dorati, Ida Genta, Enrica Chiesa, Silvia Pisani and Bice Conti. Skin wound healing process and new emerging technologies for skin wound care and regeneration. *Journal of Pharmaceutics* .2020,Vol.2, No.735
- 3- Won-Serk k., Byung-Soon P., Jong-Hyuk S., Seok-Beom P., Sahng- June K., Sahng-June K., and Jeong-Soo P. Wound healing effect of adipose –derived stem cells: A critical role of secretory factors on human dermal fibroblasts. *Journal of Dermatological science*.2007,Vol.48, No.1
- 4- Barbara Cvenkel ,Andreja Natasa K. and Alojz Ihan. Inflammatory molecules in aqueous humour and on ocular surface and glaucoma surgery outcome. *Journal of Mediators of inflammation*. 2010, Vol.1, No.4
- 5- Oliver J. Smith, Gavin Jell and Ash Mosahebi. The use of fat grafting and platelet –rich plasma for wound healing: A review of the current evidence. *Journal of International wound*. 2018, Vol.16,No.1

- 6- Ranganathan K., Wong V.C., Krebsbach P.H., Wang S.C., Cenderna P.S. and Levi B. Fat grafting for thermal injury: current state and future directions. *Journal of Burn Care Research*. 2013, Vol.32, No.2
- 7- Marino G., Moraci M., Armenia A. Therapy with autologous adipose –derived regenerative cells for the care of chronic ulcer of lower limb in patients with peripheral arterial disease. *Journal of surgery research*. 2013, Vol.185, No.1
- 8- Rahul M. and Sherma S. Role of autologous fat grafting in burns wounds. *Indian Journal of burns*.2019, Vol.26, No.1
- 9- Fredman R., Katz AJ. and Hultman CS. Fat grafting for burn, traumatic and surgical scar. *Journal of Clinical plastic surgery*.2017, Vol.44, No.4
- 10- Bertozzi N., Simonacci F., Grieco MP., Grignaffini E. and Raposio E. The biological and clinical basis for the use of adipose- derived stem cell in the field of wound healing. *Journal of Medical Surgery*. 2017, Vol.20, No.1
- 11- Joshua Luck, Oliver J. Smith, Dean Malik and Afshin Mosahebi. Protocol for a systemic review of autologous fat graft for wound healing. *Systematic review*. 2018, Vol.8, No.1.
- 12- Ferraro GA., DeFrancesco F., Nicoletti G. Human adipose CD34+CD90+stem cells and collagen scaffold constructs graft in vivo fabricate loose connective and adipose tissue. *Journal of cell Biochemical*. 2013, Vlo.114
- 13- Zuk PA., Zhu M., Mizuno H., Huang J., Futrell JW. And Katz AJ. Multi-lineage cells from human adipose tissue: implications for cell based therapies. *Journal of Tissue Engeneries*. 2001, Vol.7, No.2
- 14- Santos Lacomba M, Marcos Martin C., Gallardo Galera JM., Gomez Vidal MA., Collantes Esteve E., Ramirez Chamond R and Omar M.M. Aqueous humour and serum tumor necrosis factor- $\alpha$  in clinical uveitis. *Journal of Ophthalmic Research*.2001, Vol.33, No.5
- 15- Bettina Klenkler and Heather Seardown. Growth factors in the anterior segment: role in tissue maintenance, wound healing and ocular pathology. *Journal of Experimental Eye Research*. 2004, Vol.79, No5
- 16- David A. Rubenstein, Wei Yin and Mary D. Frame. *Bio-fluid mechanics* 2<sup>nd</sup> edition. Chapter 10. Academic Press.2016, Pp. 355-358.
- 17- Paige Teller MD. and Theresek White K. The physiology of wound healing: injury through maturation. *Journal of Surgical clinical of North America*. 2009, Vol.89, No.3
- 18- Piccolo NS., Piccolo MS. and Piccolo MT. Fat graft for treatment of burns, burn scars and other difficult wounds. *Journal of Clinical plastic surgery*.2015, Vol.42, No.2
- 19- Kyoung In Jung, Jung Eun Woo and Chan Kee Park. Effect of aqueous suppressant and prostaglandins analogues on early wound healing after glaucoma implant surgery. *Journal of Scientific Reports*.2019, Vol.9, No.1