

New Insight in the Using of Core Needle Biopsy As First Line in Preoperative Diagnosis of Thyroid Nodule

Eaman Suud Khalifa¹, Ayser Hameed Latif²

¹Lecturer, ²Assistant Professor/Pathology Department/ College of Medicine/ Mustansiriyah University

Abstract

Background: The diagnosis of thyroid nodule by core needle biopsy is different from post resection samples because of difficulties in applying histological criteria for both samples due to limitation in core needle biopsy sample .

Objective: To assess the utility of core needle biopsy in diagnosis of thyroid nodule.

Material and Method: We use core needle biopsy as first line method instead of fine needle aspiration and to reach final diagnosis after resection sample . Core needle biopsy results were divided to six groups) unsatisfactory, benign, indeterminate, follicular neoplasm, suspicious for malignancy and malignant) according to The Bethesda system for reporting thyroid cytopathology ^(1,2,3) .

Result : A total of 45 thyroid nodules taken from 45 patients (30 female and 15 male) . Malignant changes were seen in 19 nodules after surgery and 26 after core needle biopsy. Benign nodules were diagnosed in 11 cases after surgery and in 12 cases after core needle biopsy . Final diagnoses were concluded for 34 nodules (76%). Twenty one nodules were diagnosed as malignant nodules and 13 nodules were diagnosed as benign nodules .

Conclusions: Core needle biopsy is reliable and valuable tool for the diagnosis of thyroid nodule and can be used as an alternative to fine needle aspirate especially in patients with inconclusive results .

Keywords: core needle biopsy, pathological diagnosis, thyroid nodule

Introduction

The diagnosis of thyroid nodule before surgery is done by fine needle aspirate (FNA) is useful diagnostic method ^(1,2). Although cytological aspiration of the thyroid by large needle had been introduced since many years, FNA by using a needle has been an important diagnostic modality for thyroid nodules and usually it is safe and effective. An alternative to FNA, core needle biopsy (CNB) is now widely used as a preoperative diagnosis of thyroid nodule, with dependable results due to the new advances in core needle devices as thin needle and new advances in the procedure under ultrasound guidance.

On the other hand, the using of CNB for the diagnosis of thyroid nodules before surgery leads to new challenges for pathologists. The absence of widely

accepted histologic classification for CNB has led to difficult connection between pathologists and clinicians and inefficient results. Therefore, we need to achieve efficient classification for thyroid nodule by CNB for both pathologist and clinicians. New advances suggest that CNB can be safe with low complication rate (0%-4.1%) . To reduce the danger that result from the complication of CNB, it should be done by well trained hands and should be undertaken under ultrasound guidance. So careful awareness about the anatomy of the neck is required to minimize such complication ^(18,19,20) . Nodules can be detected by clinical examination and by imaging technique. Thyroid nodule can be benign but even though may require surgery especially when they reach large size or if there is a suspicious for malignancy. The diagnosis may need ultrasound imaging or cytological findings to reach the final diagnosis. Markers analysis may be useful in detecting malignancy and may

be used as adjunct to cytology if available.

v In addition to that , findings of physical examination of the thyroid gland such as increasing in nodule size , hardness and fixation of lymph nodes are important step for the diagnosis of malignant nodules . If malignancy is detected preoperatively, total thyroidectomy is the treatment of choice .

Aim of the Study

In our study, we assess the utility CNB for the diagnosis of thyroid nodules .

Material and Methods

Samples of patients with thyroid nodules followed at Baghdad medical city between July and December 2019.

We use CNB as first line method instead of FNA and to reach final diagnosis after resection sample, review process can be achieved for some cases with inconsistent or final diagnosis. CNB can be done by using thin needle after application of Lidocaine as a local anesthesia . The needle was introduced into the thyroid gland after applying firm compression then the specimen is taken. All ultrasound examinations and ultrasound guided CNBs were performed by expert radiologists . CNB results were categorized into six categories according to “The Bethesda System for Reporting Thyroid Cytopathology (TBSRTC) ^(1,2,3) into unsatisfactory, benign, indeterminate, follicular neoplasm, suspicious for malignancy and malignant”.

Statistical Analysis

“Analysis of data was carried out using the statistical package of SPSS-22. Data were presented in simple measures of frequency, percentage, mean, standard deviation, and range”. “The significance of difference of different means (quantitative data) was tested using Students-t-test for difference between two independent means. The significance of difference of different percentages (qualitative data) was tested using Pearson Chi-square test (2-test). Statistical significance was considered whenever the P value was equal or less than 0.05”

Result

A total of 45 thyroid nodules taken from 45 patients (30 female and 15 male) were included in the analysis . Malignant changes were seen in 19 nodules after surgery and 26 after core needle biopsy. Benign nodules were diagnosed in 11 cases after surgery and in 12 cases after CNB . Final diagnoses were concluded for 34 nodules (76%). Twenty one nodules were diagnosed as malignant nodules and 13 nodules were diagnosed as benign nodules (Table1).

Table 1 shows the majority of cases were diagnosed as malignant in the initial and final diagnosis but some cases appear as suspicious in CNB then later on appear as malignant in the final diagnosis. These differences in diagnosis between CNB and resection sample may be related to size of the biopsy, in CNB is smaller and less informative than the resection sample from which we can take many pieces and from different places so the diagnosis appear more perfect and valuable.

Table 1: CNB Results and Final Diagnosis for suspicious Thyroid Nodules

		Benign (n=13)	Malignant(n=21)
Non diagnostic	0	0	0
Benign	12(26.7%)	11(84.6%)	0
indeterminate	5(11.1%)	2(15.4%)	1(4.7%)
FNA or SFN	0	0	0
Suspicious of malignancy	2 (4.4%)	0	1(4.7%)
Malignancy	26(57.8%)	0	19 (90.5%)

□

Table 2 shows the basic histopathological features to differentiate benign from malignant nodule and we depend on many factors like age of the patient. Thyroid nodule in older patients is more likely to be malignant . Another important factor is the sex of the patient were the thyroid nodule in female sex carry a higher risk for malignancy. Nodule with a size of more than 1 cm, is more likely to be malignant . In addition to these factors , the features of the nodule like irregularity of the nodule border or presence of with microcalcification are important for the diagnosis of malignant nodules .

Table 2. Basic and histo-pathological characteristics

	Malignant (n=21)	Benign (n=13)	Inconclusive (n=11)	P value
Age (year)				
40-60	15	11	7	0.071
>60	6	2	4	0.218
Sex (male: female)	8 13	8 5	5 6	0.018 0.019
Nodule size (cm)				
<1cm	7	3	3	0.221
>1cm	14	10	8	0.019
Shape , n (%)				
ovoid	1	10	3	0.017
Taller than wide	17	1	8	0.018
irregular	3	1	1	
Margin ,n (%)				
Smooth	1	9	5	0.218
Speculated	18	2	6	0.081
Ill defined	2	2	1	0.285

Cont... Table 2. Basic and histo-pathological characteristics

Echogenicity,n(%)				
Hyperechoic	2	10	6	0.221
Hypoechoic	12	2	4	0.218
Markedly hypoechoic	7	1	1	0.317
Calcification ,n(%)				
Non	2	9	4	0.221
Microcalcification	18	1	5	0.172
macrocalcification	1	3	2	0.391

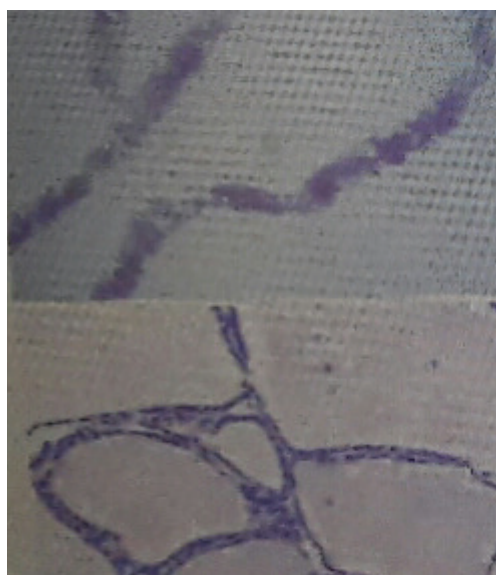

Figure 1: Core needle biopsy shows macrofollicular proliferation

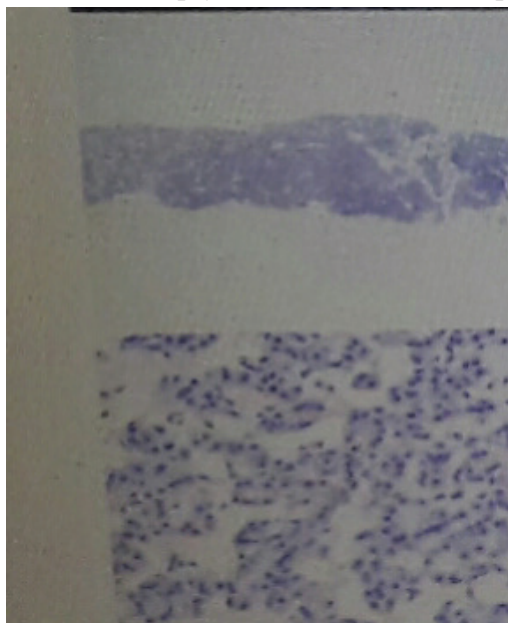


Figure 2: Core needle biopsy shows only microfollicular proliferation.

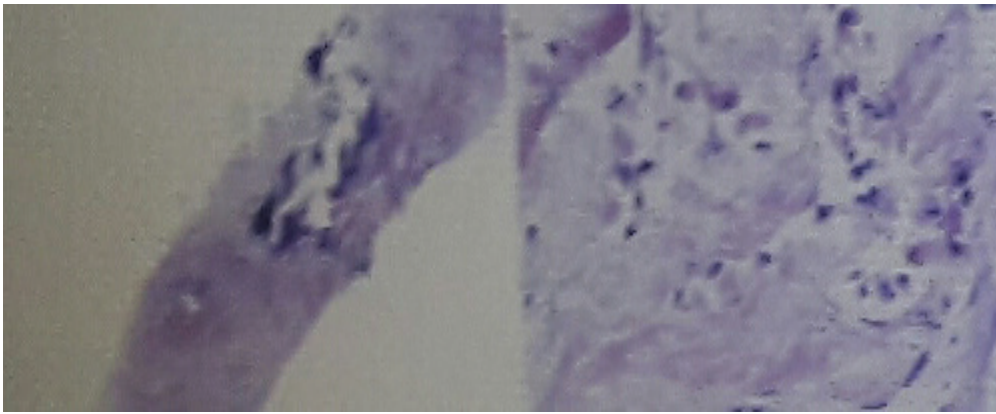


Figure 3: core needle biopsy shows calcification and suspicious atypical cells looks like malignant cells.

Discussion

Thyroid nodules are present in approximately 50 to 60% of healthy people. Usually, most of these nodules do not cause clinically significant symptoms, therefore, the main challenge in their management is to rule out malignant changes. Traditionally, FNA was the main diagnostic procedure for assessing thyroid nodules. Recently, CNB is emerging as an alternative diagnostic procedure for thyroid nodules.

According to previous reports⁽¹⁷⁾, CNB for thyroid nodule may help in improving the diagnostic results and can decrease the percentage of indeterminate or inconclusive results of traditional FNA and may be used as a first-line diagnostic procedure in the assessment of thyroid nodules at high risk of malignant changes.

The Bethesda System for Reporting Thyroid Cytopathology (TBSRTC) established a category-based reporting system for thyroid FNA samples. The 2017 revision states that thyroid FNA finding should be classified into six categories: “(I) nondiagnostic or unsatisfactory; (II) benign; (III) atypia of undetermined significance (AUS) or follicular lesion of undetermined significance (FLUS); (IV) follicular neoplasm or suspicious for a follicular neoplasm; (V) suspicious for malignancy; and (VI) malignant”.

The risk of malignancy in each category ranging from 0% to 3% for the “benign” category and may reach to 100% for the “malignant” category.

In one of previous studies¹⁵ “CNB showed low rates of Bethesda category 1 and indeterminate results and a

high diagnostic accuracy. CNB also reduce unnecessary thyroid surgery”.

In our study, there was obvious difference between original diagnosis and final diagnosis after surgery. The diagnosis of some samples in CNB was inconclusive or benign while after surgery appear as different diagnosis, it could be benign or malignant, Therefore, we need urgent and perfect histological classification that is valuable and operable.

Thyroid nodules can be diagnosed around the world mainly by FNA, however the role of CNB is also seems to be dependable.

Among forty five CNB sample, only 5 samples (11.1%) were classified as indeterminate. Twenty six samples were diagnosed as malignant after CNB (57.8%) while after surgery 19 samples (90.5%) given this diagnosis. This difference in the results between CNB and resection samples may be related to sample size. Nevertheless the features of malignancy appears as atypia and other features of neoplasia are useful in diagnosis in CNB. Although, the features of malignancy present, it could be insufficient for the diagnosis of malignancy.

The main limitation of CNB is the sample size, so the diagnosis may be difficult or inconclusive.

All CNB and surgical samples were reviewed by a thyroid cytopathologist with more than 10 years of clinical experience in thyroid cytopathology. Although the classification of thyroid nodules by CNB finding is not well established, we try to apply the Bethesda system

classification that used for histologic finding in FNA .

CNB results were classified as non diagnostic if the sample is insufficient for clear diagnosis, indeterminate or suspicious for malignancy when the features are inconclusive for complete diagnosis.

Our study results were comparable with many previous reports regarding the utility of CNB as an important additional promising tool for the diagnosis of thyroid nodule tumours .

Hahn SY et al ⁽⁵⁾, reported in there study that “ultrasonography-guided CNB is important for the diagnosis of thyroid nodules with inconclusive ultrasonography-guided FNA results. However, it is still not helpful for the differential diagnosis in 36% of nodules that are suspicious for follicular neoplasm seen on ultrasonography”

Na DG et al ⁽¹⁰⁾, reported in there study that “CNB show better results than FNA for reducing the frequency of inconclusive diagnostic results. CNB will improve the diagnostic accuracy for malignancy more than FNA in thyroid nodules that on the first FNA had nondiagnostic results”

Yeon JS et al ⁽¹³⁾, study stated that “CNB of the thyroid nodule demonstrates high rates of conclusive and accurate diagnoses in patients for whom previous FNA results were nondiagnostic, thereby reducing the need for unnecessary diagnostic surgery”

Similarly , Hakala T et al ⁽¹⁴⁾, found in there study that “CNBs had a high definitive sensitivity for malignancy (61%, CI 41% to 78%) whereas the definitive sensitivity for malignancy of FNA was significantly lower (22%, CI 10% to 42%). Moreover, CNB was not beneficial in the diagnosis of follicular thyroid lesions. When all suspected follicular tumours were excluded, the definitive sensitivity of CNB rose to 70% (CI 48% to 86%)”.

Trimboli P et al ⁽¹⁶⁾, found in there study that “the overall rate of malignancy was of 80% (CNB, 77%; FNA, 83%). However, the diagnostic accuracy of CNB (97%) was significantly ($P < 0.05$) higher than that of FNA (78%). In one benign lesion, CNB was inconclusive. Four (12%) of the 34 cancers of the FNA group were not initially diagnosed because of false

negative , indeterminate or not adequate samples”.

Furthermore , in Lee SH study ⁽³²⁾ , they found that “the rate of a second non-diagnostic result was significantly higher on repeat FNA than on CNB (33.2 vs. 2.4 %; $p < 0.001$). There was no significant difference in the malignancy risk among patients initially non-diagnostic, twice non-diagnostic, and thrice or more non-diagnostic, nor did this differ from the rate following CNB. No further malignancy was found in cases with ≥ 2 non-diagnostic CNBs. The malignancy risk was 51 % in those who underwent thyroid surgery. The sensitivity for detecting malignancy was 65 and 70 % for repeat FNA and first CNB, respectively, with no false positives seen in either test. So they reported that about one-third of repeat FNA after an initial non-diagnostic aspirate are non-diagnostic on repeat examination, and the malignancy risk may not reduce following repeated non-diagnostic FNA. However, a single CNB may be enough to exclude malignancy risk for patients with a non-diagnostic aspirate”

Study limitations

Our study was performed in a single specialist center with a small sample size and different results may be seen in other centers or general hospitals with less experienced operators .

Conclusion

CNB is reliable and valuable tool for the diagnosis of thyroid nodule and has been used as an alternative or additional diagnostic procedure to FNA especially in patients with indeterminate or inconclusive results .

Ethical Clearance: core needle biopsy and resection samples were reassess by number of expert thyroid histo-pathologists.

Source of Funding: Self

Conflict of Interest: in this article there is no any problem in regard to interest.

References

1. Baloch ZW, Cibas ES, Clark DP, Layfield LJ, Ljung BM, Pitman MB, et al. The National Cancer Institute thyroid fine needle aspiration state of the science conference: a summation. *CytoJournal*

- 2008;5:6.
2. Baek JH, Na DG, Lee JH, et al. Core needle biopsy of thyroid nodules: consensus statement and recommendations. *J Korean Soc Ultrasound Med* 2013; 32: 95–102.
 3. Cibas ES, Ali SZ. The 2017 Bethesda system for reporting thyroid cytopathology. *Thyroid* 2017;27:1341-6
 4. Baek JH. Current status of core needle biopsy of the thyroid. *Ultrasonography* 2017;36:83-5
 5. Gharib H, Papini E, Garber JR, Duick DS, Harrell RM, Hegedus L, et al. American Association of Clinical Endocrinologists, American College of Endocrinology, and Associazione Medici Endocrinologi Medical Guidelines for clinical practice for the diagnosis and management of thyroid nodules: 2016 update. *Endocr Pract* 2016;22:622-39.
 6. Hahn SY, Shin JH, Han BK, Ko EY, Ko ES, et al. Ultrasonography-guided core needle biopsy for the thyroid nodule: does the procedure hold any benefit for the diagnosis when fine-needle aspiration cytology analysis shows inconclusive results? *Br J Radiol* 2013; 86: 20130007.
 7. Ha EJ, Baek JH, Lee JH, Kim JK, Choi YJ, Sung TY, et al. Complications following US-guided core-needle biopsy for thyroid lesions: a retrospective study of 6,169 consecutive patients with 6,687 thyroid nodules. *Eur Radiol* 2017;27(3):1186–1194.
 8. Jeong EJ, Chung SR, Baek JH, Choi YJ, Kim JK, Lee JH, et al. A comparison of ultrasound-guided fine needle aspiration versus Core needle biopsy for thyroid nodules: pain, tolerability, and complications. *Endocrinol Metab* 2018;33(1):114–120.
 9. Jung CK, Hong S, Bychkov A, Kakudo K, et al. The use of fine-needle aspiration (FNA) cytology in patients with thyroid nodules in Asia: a brief overview of studies from the working Group of Asian Thyroid FNA cytology. *J Pathol Transl Med* 2017;51(6):571–578.
 10. Na DG, Baek JH, Jung SL, Kim JH, Sung JY, Kim KS, et al. Core needle biopsy of the thyroid: 2016 consensus statement and recommendations from Korean Society of Thyroid Radiology. *Korean J Radiol* 2017;18(1):217–237.
 11. Nasrollah N, Trimboli P, Rossi F, et al. Patient's comfort with and tolerability of thyroid core needle biopsy. *Endocrine* 2014; 45: 79–83
 12. Suh CH, Baek JH, Kim KW, Sung TY, Kim TY, Song DE, et al. The role of core-needle biopsy for thyroid nodules with initially nondiagnostic fine-needle aspiration results: a systematic review and meta-analysis. *Endocr Pract* 2016;22: 679-88
 13. Yeon JS, Baek JH, Lim HK, et al. Thyroid nodules with initially nondiagnostic cytologic results: the role of core-needle biopsy. *Radiology* 2013; 268: 274–80.
 14. Hakala T, Kholová I, Sand J, et al. A core needle biopsy provides more malignancy-specific results than fine-needle aspiration biopsy in thyroid nodules suspicious for malignancy. *J Clin Pathol* 2013;66:1046-50. 10.1136/jclinpath-2013-201559
 15. Teng W, Liu Y, Gao M, Huang G, Wu Y, Zhao J, et al. The Chinese society of endocrinology guidelines taskforce on thyroid nodules and differentiated thyroid cancer. *Chin J Endocrinol Metab.* 2012;28(10):779–97.
 16. Trimboli P, Nasrollah N, Guidobaldi L, et al. The use of core needle biopsy as first-line in diagnosis of thyroid nodules reduces false negative and inconclusive data reported by fine-needle aspiration. *World J Surg Oncol* 2014; 12: 61.
 17. Haugen BR, Alexander EK, Bible KC, Doherty GM, Mandel SJ, Nikiforov YE, et al. 2015 American Thyroid Association management guidelines for adult patients with thyroid nodules and differentiated thyroid cancer: The American Thyroid Association Guidelines task force on thyroid nodules and differentiated thyroid cancer. *Thyroid* 2016;26:1-133.
 18. Jung CK, Hong S, Bychkov A, Kakudo K. The use of fine needle aspiration (FNA) cytology in patients with thyroid nodules in Asia: a brief overview of studies from the Working Group of Asian Thyroid FNA Cytology. *J Pathol Transl Med* 2017;51:571-8.
 19. Baek JH. Current status of core needle biopsy of the thyroid. *Ultrasonography* 2017;36:83-5.
 20. Pitman MB, Abele J, Ali SZ, Duick D, Elsheikh TM, Jeffrey RB, et al. Techniques for thyroid FNA: a synopsis of the National Cancer Institute Thyroid Fine-Needle Aspiration State of the Science Conference. *Diagn Cytopathol* 2008;36:40724.

21. Silverman JF, West RL, Finley JL, Larkin EW, Park HK, Swanson MS, et al. Fine-needle aspiration versus large-needle biopsy or cutting biopsy in evaluation of thyroid nodules. *Diagn Cytopathol* 1986;2:25-30.
22. Wang C, Vickery AL Jr, Maloof F. Needle biopsy of the thyroid. *Surg Gynecol Obstet* 1976;143:365-8.
23. Novoa E, Gurtler N, Arnoux A, Kraft M. Role of ultrasound-guided core-needle biopsy in the assessment of head and neck lesions: a meta-analysis and systematic review of the literature. *Head Neck* 2012;34:1497-503.
24. Choi SH, Baek JH, Lee JH, Choi YJ, Hong MJ, Song DE, et al. Thyroid nodules with initially non-diagnostic, fine-needle aspiration results: comparison of core-needle biopsy and repeated fine-needle aspiration. *Eur Radiol* 2014;24:2819-26.
25. Choi YJ, Baek JH, Suh CH, Shim WH, Jeong B, Kim JK, et al. Core-needle biopsy versus repeat fine-needle aspiration for thyroid nodules initially read as atypia/follicular lesion of undetermined significance. *Head Neck* 2017;39:361-9.
26. Park KT, Ahn SH, Mo JH, Park YJ, Park DJ, Choi SI, et al. Role of core needle biopsy and ultrasonographic finding in management of indeterminate thyroid nodules. *Head Neck* 2011;33:160-5.
27. Suh CH, Baek JH, Lee JH, Choi YJ, Kim KW, Lee J, et al. The role of core-needle biopsy in the diagnosis of thyroid malignancy in 4580 patients with 4746 thyroid nodules: a systematic review and meta-analysis. *Endocrine* 2016;54: 315-28.
28. Paja M, del Cura JL, Zabala R, Corta I, Lizarraga A, Oleaga A, et al. Ultrasound-guided core-needle biopsy in thyroid nodules. A study of 676 consecutive cases with surgical correlation. *Eur Radiol* 2016;26:1-8.
29. Sung JY, Na DG, Kim KS, Yoo H, Lee H, Kim JH, et al. Diagnostic accuracy of fine-needle aspiration versus core-needle biopsy for the diagnosis of thyroid malignancy in a clinical cohort. *Eur Radiol* 2012;22:1564-72.
30. Ha EJ, Baek JH, Lee JH, Kim JK, Song DE, Kim WB, et al. Core needle biopsy could reduce diagnostic surgery in patients with anaplastic thyroid cancer or thyroid lymphoma. *Eur Radiol* 2016;26:1031-6.
31. Ha EJ, Baek JH, Na DG, Kim JH, Kim JK, Min HS, et al. The role of core needle biopsy and its impact on surgical management in patients with medullary thyroid cancer: clinical experience at 3 medical institutions. *AJNR Am J Neuroradiol* 2015;36:1512-7.
32. Lee SH, Kim MH, Bae JS, Lim DJ, Jung SL, Jung CK, et al. Clinical outcomes in patients with non-diagnostic thyroid fine needle aspiration cytology: usefulness of the thyroid core needle biopsy. *Ann Surg Oncol* 2014; 21: 1870-79 .
33. Ha EJ, Baek JH, Lee JH, Lee HY, Song DE, Kim JK, et al. A focal marked hypoechogenicity within an isoechoic thyroid nodule: is it a focal malignancy or not? *Acta Radiol* 2015;56: 814-9.
34. Ha EJ, Baek JH, Lee JH, Kim JK, Kim JK, Lim HK, et al. Core needle biopsy can minimise the non-diagnostic results and need for diagnostic surgery in patients with calcified thyroid nodules. *Eur Radiol* 2014;24:1403-9.