

Role of Sonoelastography in Predicting Positive Sperm Retrieving in Patients with Non-Obstructive Azoospermia

Saaduldeen Gali¹, Muntader Easa Alkhursan¹, Mohamad A. Mahdi², Raid Haleem Al saad³

¹Lecturer, Department of Urology, College of Medicine, University of Kufa, Iraq, ²Consultant Radiologist, Department of Radiology, AlSadder Medical City, Najaf, Iraq, ³Professor of Radiology, Department of Medicine, College of Medicine, University of Kufa, Iraq

Abstract

Background: Infertility is an important public health problem, almost 10-30% is due to azoospermia. Elastography is a new ultrasound modality which simply could evaluate the internal elasticity of the testis & finally give an idea about the presence or absence of sperms.

Objective: To evaluate the validity of sonoelastography in predicting positive sperm retrieving in patient with azoospermia.

Patients and Methods: A cross sectional study performed in Al-Sader Teaching Hospital / fertility center & radiology department during the period from 1st September 2017 to 1st September 2018, included 98 patients /196 testes) with azoospermia by B-mode U/S, Doppler study (RI) & Elastography (strain ratio), then biopsies obtained for all patients

Results: Only (136) testes were subjected to biopsy. Testicular volume & strain ratio were the most important factors which suggest that the testis will give a positive or negative sperm retrieving. Low volume + high strain NSR (bad prognosis) while high volume + low strain PSR (good prognosis).

These findings of SR were 75.7% sensitive, 93% specific, with 78% and 92% positive and negative predictive values, respectively and an accuracy of 89%.

Conclusion: Strain Elastography results have been validated and were differed significantly between patients with abnormal sperms count than those without. This Technique provides a promising way to get more accurate diagnostic results.

Keywords: Azoospermia, Definition, causes, Types, Non-obstructive Sonoelastography

Introduction

World Health Organization (WHO) and American Society Committee of Reproductive Medicine Practice (ASRM) defines infertility as "Inability of sexually active couples who do not use contraception to have a spontaneous pregnancy after a year of unprotected sex" Azoospermia, both obstructive and non-obstructive, affects almost 20% of cases with male infertility⁽¹⁾.

Azoospermia mean "no sperm in the ejaculate in at least two semen analyzes and two semen samples obtained in two weeks interval"^(2, 3). Many causes of azoospermia are divided into pre-, post-, and testicular. Azoospermia can be as a result of inappropriate hormonal stimulation, impaired spermatogenesis or obstruction. In most cases, obtaining physical and laboratory data, including semen volume, testicular volume, presence of bilateral vas deferens, and serum FSH levels, helps to distinguish between the three categories⁽⁴⁾.

Corresponding Author

Muntader Easa Alkhursan

Email: muntadhar.alkhursan@uokufa.edu.iq

Elastography is a method that has evolved and gained momentum over the past two decades. The

detected tissue stiffness can be made using the Young's modulus or elasticity (E), which is obtained as the ratio between stress (uniform compression) and the resulting deformations (Strains). The tissue stiffness can then be changed and presented in the form of an elastogram, which is usually color encoded⁽⁵⁾. There are two types of elastography; strain and shear wave elastography.

Patients and Methods

A cross sectional study was conducted from 1st September 2017 to 1st September 2018, at Al-Sadder teaching hospital / the fertility center & radiology unit included 98 patients with azoospermia proved by seminal fluid analysis (SFA). In all patients, a thorough clinical examination was performed after a full medical history obtained from all patients. ultrasound study was done by specialist expert radiologist using B-mode, Doppler study & elastography (SR). ES always done before a testicular biopsy to avoid altering the elasticity of the testis with invasive tests with bleeding or scarring. Biopsy results were obtained by two embryologists with at least 5 years of experience in this field. The results of the biopsy was presented as "no sperms, 300K, 500K, 1M& 4M , etc. ."Where K & M represent number of sperms in thousands& millions respectively. Sonoelastography also done and the SR was calculated. Based on static image, average of at least three times assessment was reported for each testis.

Patient preparation after patients consent, standard examination and operation protocols were followed strictly. Statistical analysis and data management were applied with the aid of SPSS software version 20.

Statistical analysis and tests were applied according to the type of variables at a significance level (P. value) of 0.05

Results

A total of 98 patients were enrolled in this study, of them (36) had a bilateral biopsy and the remaining (62) had a unilateral biopsy, the total number of testes was 136. The mean age of the patients was 31.7 ± 6.9 (Range : 20-60) years , the other features are shown in (Table 1)

According to the biopsy, the patients were divided into two groups ; group 1, those with positive sperm retrieving(PSR) included 33 testes and group 2 (103 testes) with negative sperm retrieving (NSR). Mean strain ratio is significantly higher in those with NSR (0.89 ± 0.04) than with PSR 0.44 ± 0.1 , ($P < 0.05$). Mean volume is significantly lower in those with NSR than PSR (8.25 ± 0.4) vs. (10.4 ± 0.5), respectively, ($P < 0.05$), (Table 2).

No significant statistically correlation was found between volume and SR as ($R = 0.100$ and $P. \text{value} = 0.300$), (Figure 1).

Using Receiver Operating Characteristics (ROC) Curve analysis revealed an area under curve was 0.871 which is an indicator of an excellent test as shown in (Figure 2). Furthermore, when strain ratio at cutoff point of 0.385 cross-tabulated against Biopsy result (PSR and NSR), it showed a Sensitivity of 75.5%, Specificity 93.2%, positive predictive value of 78% , negative predictive value of 92.3 and accuracy of 89%, ($P. \text{value} < 0.001$), (Table 3).

Table1. Baseline characteristics of the patients

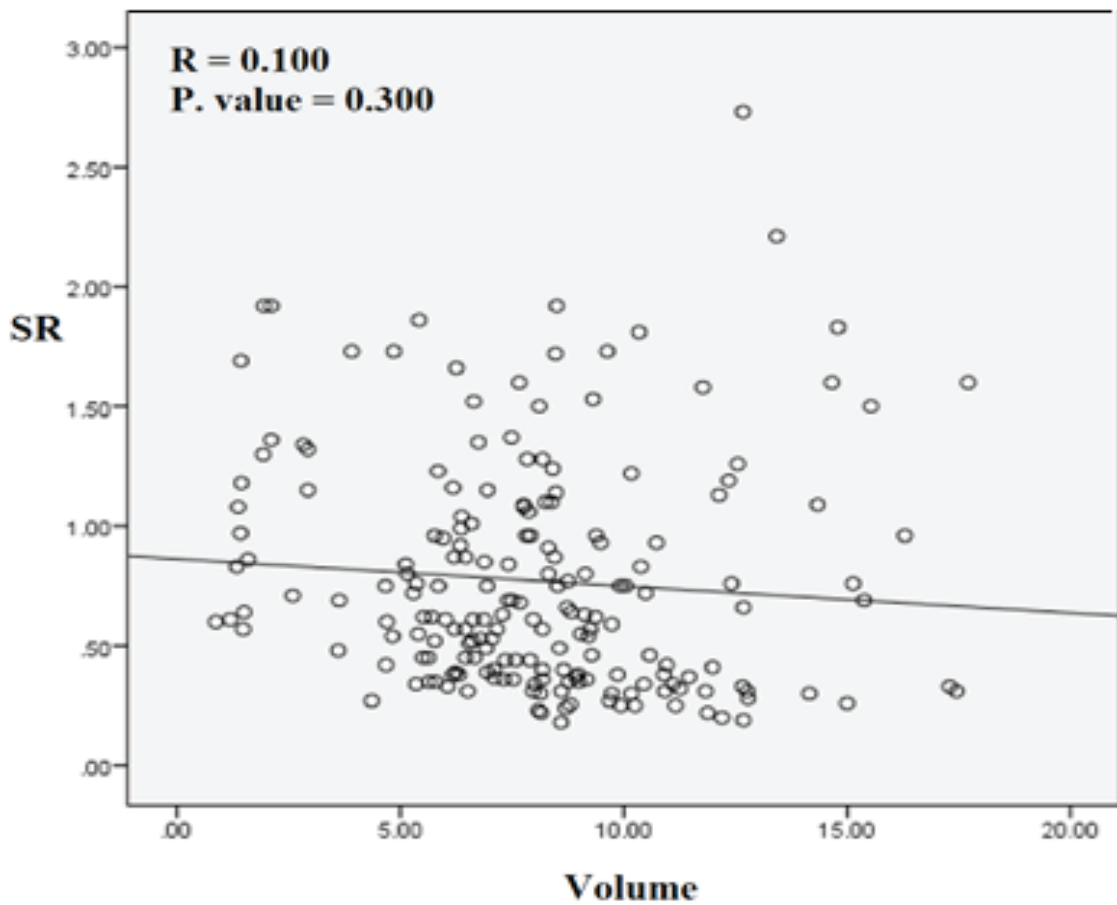
Variable		Range
Age (year) mean \pm SD	31.70 ± 6.90	20 – 60
Weight (kg) mean \pm SD	79.95 ± 7.92	61 – 96
Height (cm) mean \pm SD	169.0 ± 6.0	155 – 186
BMI (kg/m^2) mean \pm SD	28.17 ± 2.65	18.8 – 34.8
Biopsy n (%)	Unilateral	62 (63.3%)
	bilateral	36 (36.7%)
Total	98 (100.0%)	-

SD: standard deviation

Table 2. comparison of SR and testicular volume between NSR and PSR groups

Variable	NSR (n = 33)		PSR (n = 133)		P. value
	Mean	SD	Mean	SD	
SR	0.89	0.04	0.44	0.10	0.0001*
Volume	8.25	0.40	10.4	0.50	0.002*

SD: standard deviation
* Significant



High volume + low SR ➔ PSR ➔ good prognosis.
 Low volume + high SR ➔ NSR ➔ bad prognosis.

Figure 1. Correlation between testicular volume and SR .

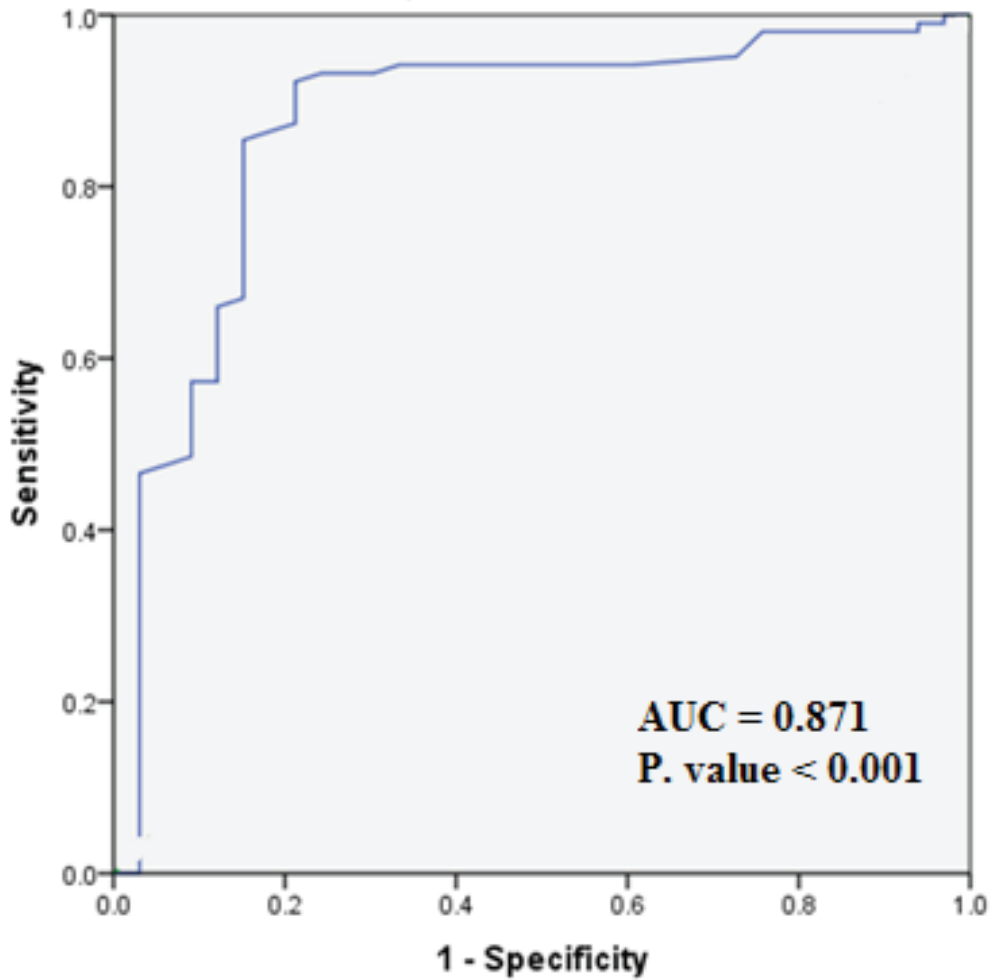


Figure 2. ROC curve for validity of strain ratio in differentiation between PSR and NSR.

**Table 3. validity of strain ratio in differentiation between PSR and NSR
(Cutoff value = 0.385)**

PSR		Biopsy		Total
		NSR		
SR	< 0.385	25 (75.8%)	7 (6.8%)	32 (23.5%)
	≥ 0.385	8 (24.2%)	96(93.2%)	104(76.5%)
Total		33(100%)	103(100.0%)	136 (100.0%)
P. value < 0.001				

Discussion

Nowadays, imaging techniques are more often used to assess the causes of infertility, traditional U / S methods (B-mode and color Doppler) using the latest technologies (SR and SWE elastography) were the first investigation line in male infertility and assessment of testicular tissue and spermatogenesis^(6,7). As the strain elastography is dependent on the criteria of compressions, it produces tissue strain, however, the deformation degree in soft tissues is larger than that in stiff one⁽⁸⁾. Few testicular focal lesions including the small diameter lesions of less than 10 mm, azoospermias and microlithiasis, especially if not palpable, have been investigated by ES^(9,10). Biopsy results from male patients with azoospermia showed that as the histological criteria increased in grade, seminiferous tubules diameter and spermatogenic epithelium height are gradually decreased, but there is a gradual increase in thickness of lamina propria⁽⁹⁾. Previous studies, proved an increased stiffness of tissues in azoospermic cases and that SR is a useful azoospermia diagnostic tool.

Other several studies have documented that SR can objectively provide data with good accuracy in diagnosis compared to elastography⁽¹⁰⁻¹²⁾. Our study have shown that in patients with abnormal parameters of sperms, the SR was much higher. On the other hand, testicular volume was suggested to be a good indicator of spermatogenesis, and a variation was proved between infertile and fertile cases⁽¹³⁾. Moreover, Seminal volume sperm motility and count appeared to be significantly correlated as documented in previous studies^(14,15). Condorelli and his colleagues⁽¹⁶⁾ found that the testicular volumes sperm parameters of bio-function were significantly associated and that testicular volume decrease exacerbated by these parameters. Elastography was approved to be useful in structural analysis of tissues since any pathological changes in tissues can be detected⁽¹⁷⁾. Our findings also show that the mean volume is much lower in patients with non-obstructive azoospermia than those with obstructive one. As the seminiferous tubules contribute to almost 80% of testicular volume, they are responsible for spermatogenesis, hence the sperms count associated with testicular volume. Using ES we can discriminate soft from hard testicular tissue regions, this based on that a backscattered sonographic signals suffer from displacement if the tissue is slightly compressed

&decompressed. Lesser displacement seen when tissue get stiffer than normal tissue. So, tissue elasticity may be correlated with pathological conditions. Unfortunately, we couldn't include the hormonal analyses of our patients because most of them didn't perform a hormonal assays before biopsy.

Conclusion

Strain Elastography results have been validated and were differed significantly between patients with abnormal sperms count than those without. This Technique provides a promising way to get more accurate diagnostic results. However, extensive research can guide the road to approve the role of imaging methods in male infertility assessment. Hence, we recommend further studies with larger sample size, to discover the beneficial applications of this modality with inclusion of hormonal status of the patients.

Ethical Clearance: All ethical issues approved by the authors and patients data were collected and Managed in accordance with the World Medical Association, declaration of Helsinki, 2013

Conflict of Interest: None

Funding: Self-funded

References

1. Gudeloglu A, Parekattil SJ. Update in the evaluation of the azoospermic male. *Clinics*. 2013;68:27-34..
2. World Health Organization, Sexual and Reproductive Health and Research team, WHO Laboratory manual for the examination and processing of human semen - 5th ed. Geneva: WHO Press, 2010; ISBN: 9789241547789: 224-6.
3. Schlegel PN. Causes of azoospermia and their management. *Reprod Fertil Dev*. 2004;16(5):561-72.
4. Cocuzza M, Alvarenga C, Pagani R. The epidemiology and etiology of azoospermia. *Clinics*. 2013;68:15-26.
5. Gennisson JL, Deffieux T, Fink M, Tanter M. Ultrasound elastography: principles and techniques. *Diagnostic and interventional imaging*. 2013 May 1;94(5):487-95..

6. Arslan H, Sakarya ME, Atilla MK. Clinical value of power Doppler sonography in the diagnosis of varicocele. *J Clin Ultrasound* 1998;26:229.
7. Zhang X, Lv F, Tang J. Shear wave elastography (SWE) is reliable method for testicular spermatogenesis evaluation after torsion. *Int J ClinExp Med* 2015;8:7089-97.
8. Ophir J, Kallel F, Varghese T, Alam SK, Krouskop T, Garra BS, et al. Elastography. *Optical and Acoustical Imaging of Biological Media* 2001;4:1193-212.
9. Li M, Du J, Wang ZQ, Li FH. The value of sonoelastography scores and the strain ratio in differential diagnosis of azoospermia. *J Urol* 2012;188:1861-6.
10. Pastore AL, Palleschi G, Maceroni P, Manfredonia G, Autieri D, Cacciotti J, et al. Correlation between semi quantitative sonoelastography and immunohistochemistry in the evaluation of testicular focal lesions. *Cancer Imaging* 2014;14:29.
11. Zhi H, Xiao XY, Yang HY, Wen YL, Ou B, Luo BM, et al. Semi quantitating stiffness of breast solid lesions in ultrasonic elastography. *AcadRadiol* 2008;15:1347-53.
12. Thomas A, Degenhardt F, Farrokh A, Wojcinski S, Slowinski T, Fischer T. Significant differentiation of focal breast lesions: calculation of strain ratio in breast sonoelastography. *AcadRadiol* 2010;17:558-63.
13. Stein RJ, Santos S, Nagatomi J, Hayashi Y, Minnery BS, Xavier M, et al. Cool (TRPM8) and hot (TRPV1) receptors in the bladder and male genital tract. *J Urol* 2004;172:1175-8.
14. TijaniKH, Oyende BO, Awosanya GO, OjewolaRW, Yusuf AO. Assessment of testicular volume: A comparison of fertile and sub-fertile West African men. *African J Urol* 2014;20:136-40.
15. Kumar S, Mohsen N, VineethVS, Malini SS. Assessment of Testicular Volume in Correlation with Spermogram of Infertile Males in South India. *Advanced Studies in Biology* 2013;5:327-35
16. Kristo A, Dani E. The Correlation between Ultrasound Testicular Volume and Conventional Semen Parameters in Albanian Subfertile Males. *Macedonian Journal of Medical Sciences* 2014;7:464-6.
17. Condorelli R, Calogero AE, La Vignera S. Relationship between testicular volume and conventional or nonconventional sperm parameters. *Int J Endocrinol* 2013; 2013:145792.