

Management of Patient with Caustic Ingestion Injury: A Case Report

Supriadi¹, Budi Widodo², Brinna Anindita³

¹Senior Resident, Department of Internal Medicine, Faculty of Medicine, Airlangga University-Dr Soetomo General Hospital, Surabaya, ²Gastroenterohepatologist, Division of Gastroentero-hepatology, Department of Internal Medicine, Faculty of Medicine, Airlangga University-Dr Soetomo General Hospital, Surabaya, ³Internist, Department of Internal Medicine, Faculty of Medicine, Airlangga University-Dr Soetomo General Hospital, Surabaya

Abstract

The ingestion of caustic substances, both accidental and voluntary, determines a complex syndrome, characterized by severe, often irreversible, visceral lesions, with still remarkable mortality in highly compromised patients. A 36-year-old woman came to Emergency-Room with the chief complaints of blackish vomiting about 4 times after drinking liquid to clean the bathroom floor. Patients with findings of grade 2B esophageal injury, pangastritis and gastric ulcer on endoscopy have high the risk of perforation and complications. Endoscopy done within 12 hours and no later than 24 hours following caustic ingestion to classify mucosal injury subsequent to caustic ingestion is useful to determine the severity of injury, particularly in suicidal cases, and thus helpful in predicting outcomes. Patient treated with rehydration with normal saline, total parenteral nutrition, pump omeprazole, injection of methylprednisolone, antibiotic, and sucralfate. Consultation with the Psychiatry department has been conducted psychoeducation and psychotherapy.

Keywords: caustic ingestion injury, endoscopy, suicidal cases.

Introduction

The ingestion of caustic substances, both accidental and voluntary, determines a complex syndrome, characterized by severe, often irreversible, visceral lesions, with still remarkable mortality in highly compromised patients. The most severe esophageal and gastric damage is notoriously related to voluntary and pseudo-voluntary ingestion of high amount or concentration of strong acids or alkali compounds.¹⁾ Corrosive substances can be acidic or alkaline.

Mucosal damage caused by corrosive material can appear one to two months after the contact.²⁾

Ten-percent of patients sustaining caustic mucosal injury-(CMI) will experience immediate complication. The most common serious immediate complications after caustic material ingestion therefore include: perforation, bleeding, but late findings include fistula formation. Reported mortality approaches 10–20%. Among those sustaining caustic injury in a suicide attempt, mortality may approach 75%. The delayed complications include stricture formation leading to malnutrition and long term risk of developing malignant transformation.¹⁾

Corresponding author:

Supriadi

Department of Internal Medicine, Faculty of Medicine, Airlangga University, Jl. Mayjen Prof. Dr. Moestopo 47, Surabaya, East Java, Indonesia Phone: +6231-5020251, Email: supriadi.ipdunair@gmail.com
Orcid ID: 0000-0003-4461-3269

We report a young adult woman with caustic ingestion injury. The aim of this case report is endoscopy following caustic ingestion to classify mucosal injury subsequent to caustic ingestion is useful to determine the severity of injury, particularly in suicidal cases, and thus helpful in predicting outcomes.

Case Description

A 36-year-old woman came to Emergency-Room with the chief complaints of blackish vomiting about 4 times after drinking liquid to clean the bathroom floor. When in the ER patient continued to vomit about 3 times. According to her husband, the patient did this to commit suicide due to their domestic problems. On physical examination general condition alert and weak. Blood pressure 160/80mmHg, pulse 112x/minute, regular-rhythm, respiratory rate 28x/minute, axillary temperature 36.7°C. On abdominal examination, contour was flat, supple on palpation, no tenderness.

Laboratory tests showed Hb 13.5-g/dL, leucocyte-112210/mm³, thrombocyte 414000/mm³, Sodium 145--mmol/L, potassium 3.4--mmol/L, chloride 113--mmol/L, blood-glucose 89--mg/dl, AST 14--U/L,

ALT 11--U/L, albumin 4.64--g/dL, urea 7--mg/dL, creatinine-0.64--mg/dL, HbsAg non-reactive. Chest-X-ray and BOF: within normal limit.

Based upon all findings we assessed the patient with intoxication of caustic substance and tentamen suicide, therapy with rehydration with normal saline, total parenteral nutrition, pump omeprazole 8mg/hour, injection of methylprednisolone 62.5mg/8hours intravenously, injection of ceftriaxone 1gram/12hours intravenously, orally sucralfate 10ml/8hours. Consultation with the Psychiatry department has been conducted psychoeducation and psychotherapy.

On 2nd day of treatment, cito endoscopy was performed on patients and grade IIB esophageal injury, pancreatitis, and gastric ulcer were obtained. On 3rd day of treatment the patient feels better, she and her family refused further hospital care due to cost problems.

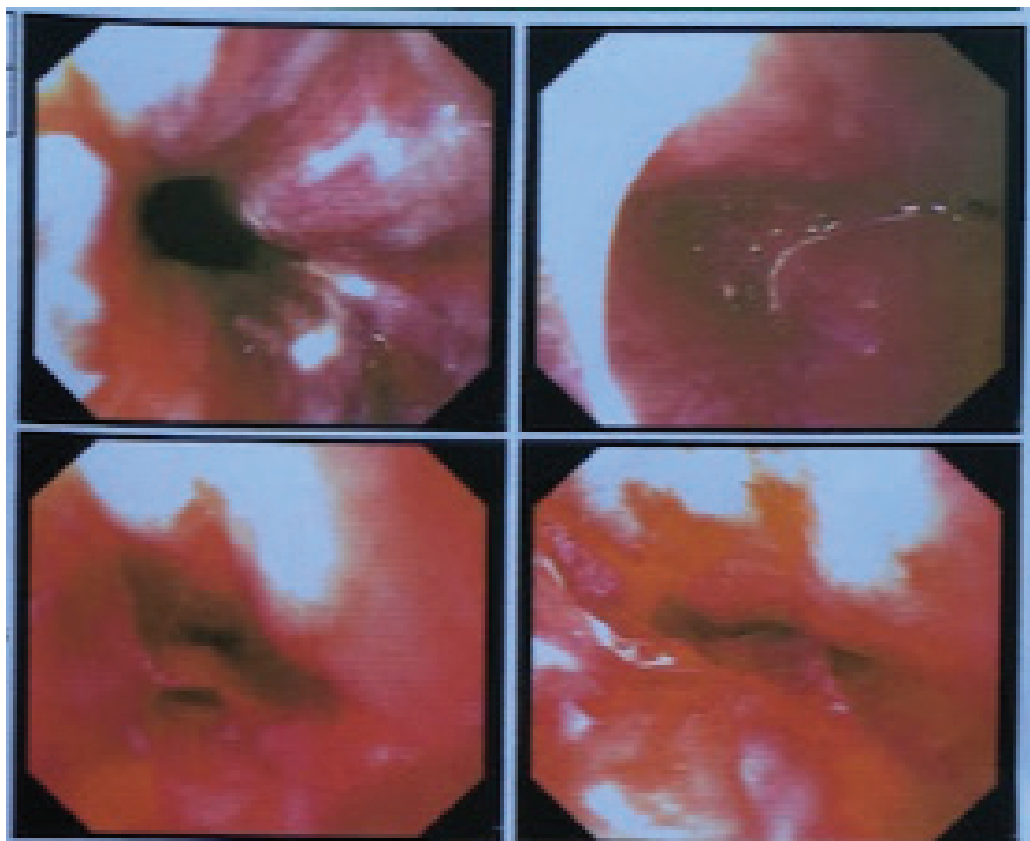


Fig.1 Multiple erythema appeared in the cavum oris, erythema and lacerations in the oropharynx and hypopharynx, Epiglottis looks edematous

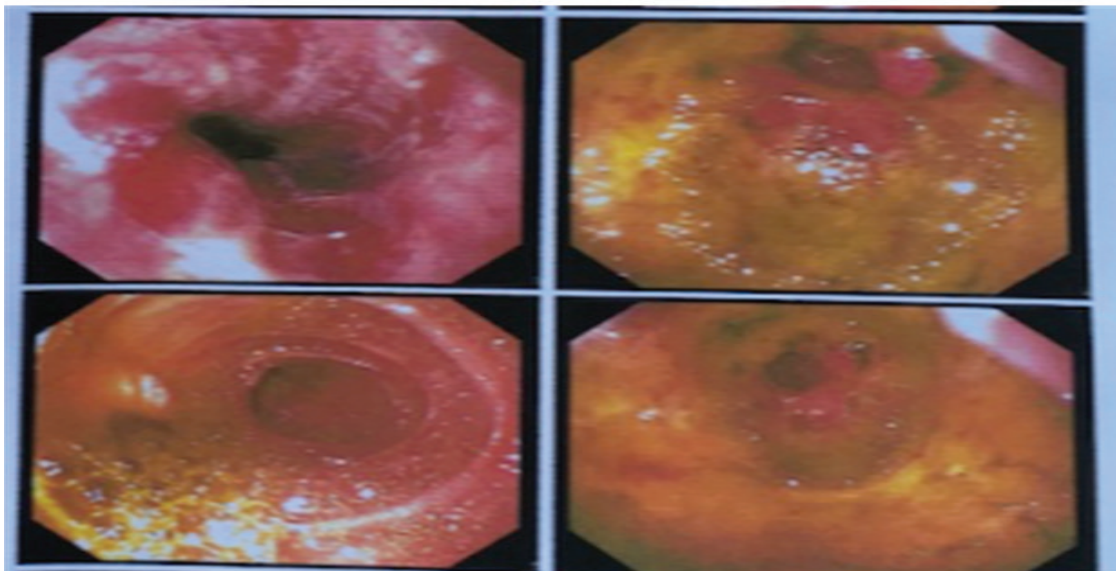


Fig.2 The proximal to distal esophagus appeared hyperemic and lacerations. Gradel2B ulcers.

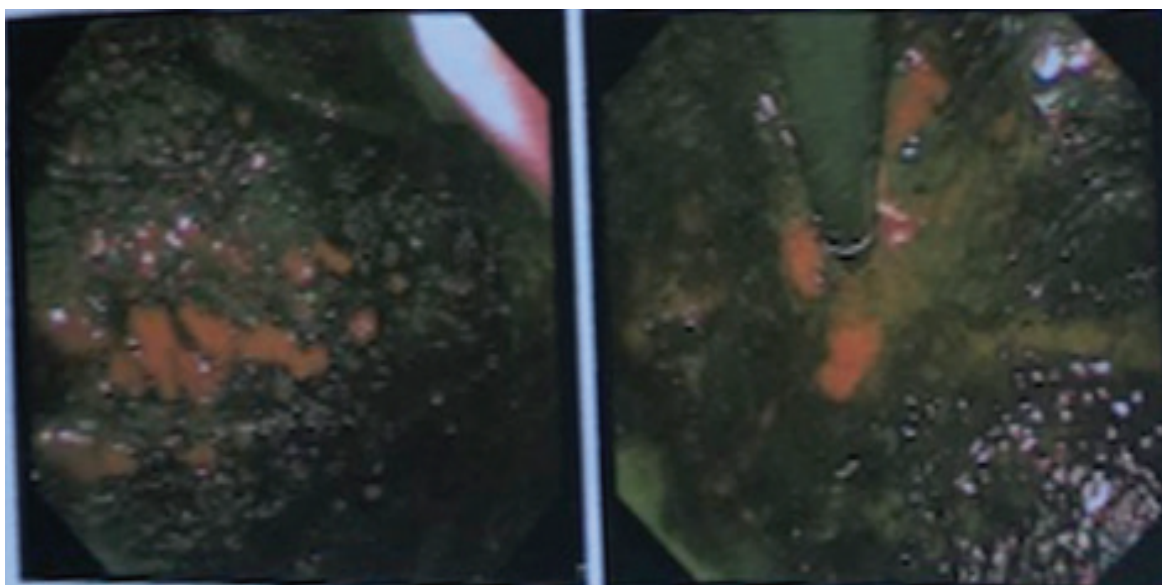


Fig.3 Gaster Mucousa appeared to be covered with blood clots, including multiple erythema, lacerations, and ulcers, with necrosis in the pre-pyloric region

Discussion

Ingestion of acid or alkaline caustic substances may cause serious injuries in the esophagus and stomach. The degree of injury is determined by the nature of the substance, the amount consumed or its concentration and state and the time of contact with the gastrointestinal mucosa.³⁾ Mechanism of action of corrosive agents; Alkali ingestion: Causes liquefaction

necrosis. This process includes protein dissolution, collagen destruction, fat saponification, cell membrane emulsification, submucosal vascular thrombosis and cell death. Acid ingestion: Causes coagulation necrosis. In this process, hydrogen ions (H^+) desiccate epithelial cells producing an eschar. This process leads to edema, erythema, mucosal sloughing, ulceration and necrosis of tissues. Both acids and alkalis cause fibrosis and cicatrization (stricture formation).⁴⁾

Hemorrhage, thrombosis, and inflammation with oedema are the dominant processes during the first 24 hours following ingestion. The clinical presentation of caustic ingestion is diverse and do not always correlate with the degree of injury. Symptoms mainly depend on the location of damage. Hoarseness and stridor are signs that are highly suggestive of an upper respiratory tract involvement, particularly the epiglottis and larynx. Presence of these findings may signal a potentially life-threatening respiratory event. The upper gastrointestinal tract, on the other hand, may present as dysphagia or odynophagia for esophageal injury and hematemesis or epigastric pain for gastric involvement.⁵⁾ The chief complaints of this patient is blackish vomiting about 4 times after drinking liquid to clean the bathroom floor.

Esophagogastroduodenoscopy is a sophisticated method for diagnostic evaluation of acute corrosive poisonings and injuries of the upper gastrointestinal tract. According to the latest controlled studies the most optimal timing for esophagogastroduodenoscopy is the first 12–24 hours following corrosive ingestion while according to other authors it may be safely performed within the first 96 hours following corrosive ingestion.⁶⁾ Endoscopy, as part of the instrumental techniques usable in the acute phase, is the mainstay of diagnostic evaluation and staging, as it allows you to check: I(a) The presence of lesions; II(b) The severity of lesions; II(c) The extent of the lesions by considered area (for example the esophagus); I(d) The topographical distribution in the upper digestive tract (from the pharynx to the duodenum); III(e) The presence of objective evidences correlated to the risk of perforation. Endoscopy should be always performed in all patients in whom the ingestion of caustic in large amount or strong concentration is sure or at least suspected, such as intentional or pseudovoluntary ones. About 20% of them could have visceral lesions without any oral pathological finding.⁷⁾

The findings on upper GI endoscopy are based on Zargar's modified endoscopic-classification of burns due to corrosive ingestion into six grades: 0 (normal mucosa), 1 (erythema/hyperemia), 2a (superficial ulcer/erosion/friability/hemorrhage/exudates), 2b (findings in 2a deep discrete/circumferential ulcers), 3a (scattered necrosis, black/grey discoloration), 3b (extensive/circumferential necrosis of mucosa).⁴⁾

The results of this study confirm Zargar's endoscopic-classification of mucosal injuries post caustic ingestion in relation to clinical outcome. The tensile strength of healing tissues in the first 3 weeks is low due to an absence of collagen. New collagen formation does not begin until the second-week after injury. Thus, it is advocated that endoscopy should be avoided from 5 to 15 days after caustic ingestion. Currently, EGD evaluation within 12 hours and no later than 24 hours after caustic ingestion is considered safe. EGD is not recommended from 2 to 3 days up to 2 weeks after caustic ingestion as a result of wound softening.⁸⁾ On 2nd day of treatment, cito endoscopy was performed on patients and grade-2b esophageal injury, erosion of pancreatitis, and gastric ulcer were obtained.

Short-term complications include perforation and death. Perforation of the esophagus or stomach can occur at any time during the first 2 to 3 weeks of ingestion. A sudden worsening of symptoms or an acute deterioration of a previously stable condition should warrant a thorough investigation to rule out the possibility of a perforated viscus.²⁾ Chronic complications of caustic ingestion include stricture formation, gastric outlet obstruction and malignant transformation. Patients with esophageal strictures usually complain of dysphagia and substernal pressure, and may become symptomatic 3 weeks or later after ingestion.²⁾

Management of caustic injury includes immediate resuscitation and evaluation of extent of damage. The cornerstone of all caustic ingestions is airway and hemodynamic stabilization. Since direct exposure of the upper respiratory-tract by the corrosive substance may occur, patients should be evaluated for the need to do immediate intubation or tracheostomy.⁵⁾ Patient therapy with rehydration with normal saline, total parenteral nutrition, pump omeprazole 8 mg/hour, injection of methylprednisolone 62.5 mg/8 hours intravenously, injection of ceftriaxone 1 gram/12 hours intravenously, orally sucralfate 10 ml/8 hours.

• **Neutralizing agents.**

It has now been emphasized that these substances should not be administered due to the additional thermal injury and chemical destruction of tissues these reactions produce.⁹⁾

- **Nasogastric tube.**

Routine nasogastric intubation for the purpose of evacuating any remaining caustic material is no longer warranted prior to endoscopic assessment of mucosal injury. This is due to the possibility of inducing retching or vomiting leading to further esophageal exposure by reflux of the remaining intragastric caustic material.¹⁰⁾

- **Gastric acid suppression and mucosal protection**

Upon admission, the patient should be kept fasting. Gastric acid suppression with H₂-blockers or intravenous proton pump inhibitors are often initiated to allow faster mucosal healing and to prevent stress ulcers.⁵⁾

- **Antibiotics**

A study in 1992 analyzed the utility of antibiotic together with systemic steroid administration in caustic ingestion. It was concluded that antibiotics with steroids may be useful in preventing strictures in patients with extensive burns.¹⁰⁾

- **Steroids**

Methylprednisolone at a dose of 1 g/1.73-m² per day for 3-days showed benefit in reducing stricture development. However, another study showed that prednisolone at a dose of 2g/kg intravenous did not provide any benefit in preventing stricture development.^{11,12)}

- **Triamcinolone**

Intralesional steroid such as triamcinolone (40-100mg/session) has long been known to augment the dilatation of caustic-induced esophageal strictures although results from most studies are still conflicting.⁵⁾

Conclusion

A 36-year-old woman with findings of grade-2 esophageal injury, pancreatitis and gastric ulcer on endoscopy have high the risk of perforation and complications due to caustic ingestion injury. Endoscopy done within 12 hours and no later than 24 hours following caustic ingestion to classify mucosal injury subsequent to caustic ingestion is useful to determine the severity of injury, particularly in suicidal cases, and thus

helpful in predicting outcomes.

Conflict of Interest: The authors report no conflict of interest.

Funding: None.

Ethical Clearance: Not required for a case report.

Acknowledgment: The authors would like to thank to Faculty of Medicine Airlangga University, Surabaya, Indonesia.

References

1. Kluger Y, Ishay Ob, Sartelli M, Katz A, Ansaloni L, Gomez Ca, Et Al. Caustic Ingestion Management: World Society Of Emergency Surgery Preliminary Survey Of Expert Opinion. *World Journal Of Emergency Surgery*. 2015;10(1):1-8.
2. Contini S, Scarpignato C. Caustic Injury Of The Upper Gastrointestinal Tract: A Comprehensive Review. *World Journal Of Gastroenterology*:Wjg. 2013;19(25):3918.
3. Park Ks. Evaluation And Management Of Caustic Injuries From Ingestion Of Acid Or Alkaline Substances. *Clinical Endoscopy*. 2014;47(4):301.
4. Naik R, Vadivelan M. Corrosive Poisoning. *Indian Journal Of Clinical Practice*. 2012; 23(3):131-6.
5. De Lusong Maa, Timbol Abg, Tuazon Djs. Management Of Esophageal Caustic Injury. *World Journal Of Gastrointestinal Pharmacology And Therapeutics*. 2017;8(2):90.
6. Chibishev A, Pereska Z, Simonovska N, Babulovska A, Chibisheva V. The Role Of Urgent Esophagogastroduodenoscopy In Prognosis Of Acute Caustic Poisonings. *Acta Informatica Medica*. 2011.
7. Rossi A. Acute Caustic Ingestion: State Of Art And New Trends. *Journal Of Gastroenterology And Hepatology Research*. 2015;4(3):1501-6.
8. Cheng H-T, Cheng C-L, Lin C-H, Tang J-H, Chu Y-Y, Liu N-J, Et Al. Caustic Ingestion In Adults: The Role Of Endoscopic Classification In Predicting Outcome. *Bmc Gastroenterology*. 2008;8(1):1-7.
9. Parsak Ck, Sakman G. The Efficiency Of Sucralfate In Corrosive Esophagitis: A Randomized, Prospective Study. *Turk-J-Gastroenterol*. 2010;21(1):7-11.
10. Arunachalam R, Rammohan A. Corrosive

- Injury Of The Upper Gastrointestinal Tract: A Review. Archives Of Clinical Gastroenterology. 2016;2(1):056-62.
11. Anderson Kd, Rouse Tm, Randolph Jg. A Controlled Trial Of Corticosteroids In Children With Corrosive Injury Of The Esophagus. New England Journal Of Medicine. 1990;323(10):637-40.
 12. Fulton Ja, Hoffman Rs. Steroids In Second Degree Caustic Burns Of The Esophagus: A Systematic Pooled Analysis Of Fifty Years Of Human Data: 1956–2006. Clinical Toxicology. 2007;45(4):402-8.