

Characteristics of Apparent Diffusion Coefficient and Time Intensity Curve in Advanced Magnetic Resonance Imaging of Malignant Soft Tissue Tumors

Agus Jati Waluyo¹, Sri Andreani Utomo², Rosy Setiawati²

¹Resident, ²Consultant, Department of Radiology, Faculty of Medicine, Universitas Airlangga, Surabaya, Indonesia

Abstract

Malignant soft tissue tumors are usually identified and characterized by conventional magnetic resonance imaging (MRI) due to its high resolution on soft tissues. However, combination of advanced MRI and conventional MRI increases the accuracy. This study was conducted to assess the characteristics of apparent diffusion coefficient (ADC) and time intensity curve (TIC) in dynamic contrast-enhanced MRI (DCE-MRI) in malignant soft tissue tumors. A cross-sectional study was conducted in Dr. Soetomo Hospital, Surabaya, Indonesia. Demographic and clinical data, the classification of malignant soft tissue tumor, histopathological examination results, ADC value, and TIC of DCE-MRI were collected. Between 1st January 2018 and 30th August 2020, 30 malignant soft tissue tumors were included of which the most common malignant soft tissue tumor occurred in those who were older than 50 year (30.0%) and located in the femur (33.3%). The most common tumor was synovial sarcoma (23.3%) and undifferentiated pleiomorphic sarcoma (20.0%). Type 4 and 3 of TIC were found in 92.0% and 8.0%, respectively. The overall mean of ADC and steepest slope were $0.84 \times 10^{-3} \pm 0.14 \times 10^{-3} \text{ mm}^2/\text{s}$ and $15.8\% \pm 19.9\%$, respectively. The highest and the lowest mean ADC was observed in squamous cell carcinoma and squamous cell carcinoma, and malignant peripheral nerve sheath tumor (MPNST), respectively. In contrast, the highest and the lowest steepest slope was found in MPNST and squamous cell carcinoma with 75.43% and 2.45%, respectively. In conclusion, information of TIC parameters such as ADC value and steepest slope might potentially be used in determining the histopathologic types of malignant soft tissue tumors.

Keywords: *apparent diffusion coefficient; time intensity curve; advanced MRI; soft tissue tumor; maximal peak enhancement.*

Introduction

Soft tissue tumor is a tumor occur in muscles, tendons, ligaments, fascia, peripheral nerves, fibrous tissue, fat, and blood vessels.^{1,2} It may appear as benign or malignant types with two clinical appearances, either neoplasm or non-neoplasm. The benign cases

are found in 300/100,000 population per year, while the malignant cases are found in 5/10,000 population per year (approximately 1% of all malignant tumor patients) with varying prognosis depending on the early diagnosis, treatment effectivity, and follow-up of the case recurrence.²

Magnetic resonance imaging (MRI) is one the imaging modalities in identifying and characterizing soft tissue abnormalities due to its high resolution on soft tissue. MRI has become the main radio-diagnostic tool in determining the tumor staging prior to biopsy, the therapeutics approaches, as well as the treatment follow-up.⁴ Despite of its high sensitivity (90%), conventional

Corresponding author:

Rosy Setiawati

Department of Radiology, Faculty of Medicine,
Universitas Airlangga, Jl. Mayjen Prof. Dr. Moestopo
No.47, Surabaya, Indonesia
Email: rosy-s@fk.unair.ac.id

MRI has a low specificity (37%) in differentiating benign and malignant soft tissue tumors due to its non-specific appearances and characteristics.⁵ Therefore, advanced MRI on soft tissue tumor have been developed and combined with conventional MRI to achieve higher accuracy. Advanced MRI itself consists of perfusion dynamic contrast-enhanced magnetic resonance (DCE-MRI) with color mapping image, proton magnetic resonance spectroscopy, diffusion weighted imaging (DWI), and inphase and opposed phase of MRI.⁴

DWI can be quantitatively evaluated using apparent diffusion coefficient (ADC) which reflects water molecules movement (i.e., diffusion) in various tissues. Therefore, tumor matrix and its cells' composition may affect DWI and ADC. Quantitative assessment of imaging using ADC has also been proven to be beneficial in differentiating benign and malignant tumors and reflecting the histological characteristics.⁶ A study also showed that tumor cellularity degree was negatively correlated to the ADC.⁷ Apart from DWI and ADC, dynamic contrast-enhanced of the vascularization in tumor and tumor-like lesions could also be quantitatively assessed using time intensity curve (TIC) and qualitatively assessed based on its slope which expressed in % per minutes. This method has several important advantages, including the ability: (a) to characterize the soft tissues; (b) to determine the local staging of a tumor; (c) to identify the active site of a tumor through MRI-guided biopsy; (d) to monitor the preoperative chemotherapy; (e) to detect the residual or recurrent lesions; and (f) to differentiate tumor and fibrosis.⁸

Assessing the ADC and TIC in advanced MRI, may provide information regarding the physiological characteristics of soft tissue tumors which later may help radiologists to characterize the vascularization of the soft tissue tumors, along with the angiogenesis patterns. Advanced MRI may also be used in evaluating the effect of anti-angiogenic treatment in soft tissue tumors which are unable to be observed in histopathological examination. This study sought to assess the characteristics of TIC and ADC of advanced MRI in malignant soft tissue tumors. The results might provide important information that help to improve the diagnostic accuracy and treatment evaluation in malignant soft tissue tumors.

Materials and Methods

A cross-sectional study was conducted in Department of Radiology, Dr. Soetomo Hospital, Surabaya, Indonesia. Demographic and clinical data, the classification of malignant soft tissue tumors, histopathological results were retrospectively retrieved from all patients' medical records from 1st January 2018 to 30th August 2020. The inclusion criteria of patients were as follows: (1) all patients who undergone DCE-MRI examination followed by the ADC evaluation and (2) the diagnosis of soft tissue tumor was confirmed based on histopathological examination. All patients that had imaging with clearly defined artefact in DWI, no TIC graph shown in the region of interest (ROI), and those with history of neoadjuvant therapy, either chemotherapy or radiotherapy were excluded. The malignant soft tissue tumors were reclassified based on the World Health Organization (WHO) 2013 classification.²

A Siemens Magnetom Skyra 3T MRI was used as the radio-diagnostic examination. An initial plain MRI, including coronal, sagittal, and axial T1W, T2W, and short tau inversion recovery (STIR) sequence were performed following the DCE-MRI and DWI sequence. Post-contrast images of the conventional FS T1W in three planes were also assessed after DCE-MRI.

A single-dose contrast agent, gadoteric acid 0.2 mmol/kgBW, was injected intravenously in a rate of 3-3.5 mL/s through the antecubital vein. Next, 20 mL of normal saline was injected following the contrast agent to empty the dry vessels and to ensure that the contrast entered the systemic circulation as a coherent bolus. Then, DCE-MRI was performed using T1 TSE 3D sequence of 30-40 slice per slab, TR/TE 5.48/1.97 ms, Fov read 200, and Fov phase 100. ADC and TIC were interpreted blindly by two musculoskeletal radiologists with more than 5 years of experience. The ROI placement was limited to three circular intra-lesion areas with 10-55 mm².

ADC and the parameters of TIC were collected. ADC was defined as a logarithmic down slope of the signal intensity among two or more *b* values as expressed in mm²/s.⁹ TIC was classified into five types according to the classification proposed by Drapé.¹⁰ The estimation of the steepest slope of TIC was performed to measure the initial uptake of the contrast agent,¹¹

while the TIC enhancement parameter was measured using the steepest slope and the maximal enhancement relative (MER).¹¹Steepest slope and MER were calculated based on formula as follows:

$$\text{Steepest slope } (\%/s) = \frac{\text{SI max} - \text{SI base}}{\text{SI base} (T \text{ max} - T \text{ min})} \times 100\%$$

$$\text{Maximal Enhancement Relative (MER)} = \frac{\text{SI max} - 100 \text{ SI base}}{\text{SI base}} \times 100\%$$

Results

Patients' characteristics

A total of 30 malignant soft tissue tumors were included in the study of which 15 patients (50%) were male with the mean age was 51.7±16.5 years. More than half of the patients (n=16, 53.3%) aged more than 50 years and no cases were reported in those younger than 20 years (**Figure 1A**). The most common location of the malignant soft tissue tumor was reported in femur (n=10, 33.3%). Elbow, supraclavicular, and wrist were the least common locations of malignant soft tissue tumor with 1 case was reported for each location (**Figure 1B**).

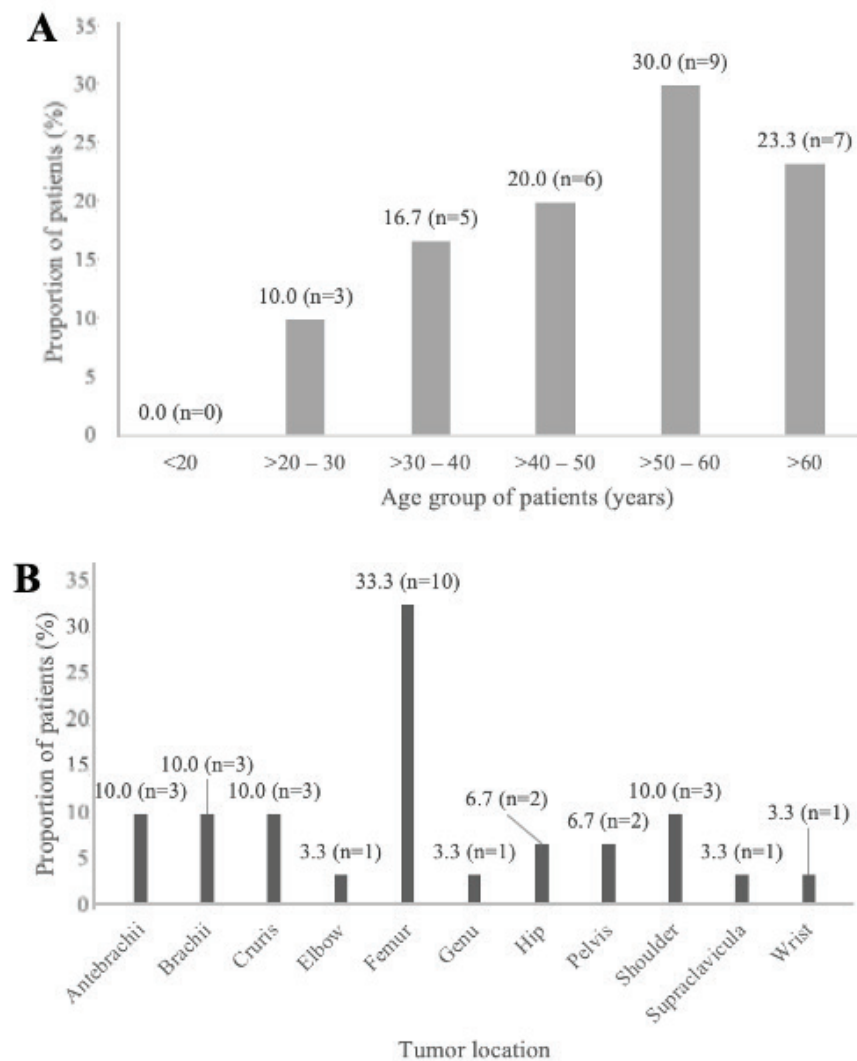


Figure 1. The characteristics of the patients with malignant soft tissue tumor based on: (A) age group and (B) tumor location.

Since the ROI placement was repeated times, the total TIC of patients was 90. Based on type of TIC, 7 (8%) malignant soft tissue tumors belonged to type 3 and 83 (92%) was type 4. No other types (type 1, 2, and 5) were observed in this study. The most common histopathological types were synovial sarcoma (23.3%)

and undifferentiated pleiomorphic sarcoma (20.0%). A radiodiagnostic result of a 55-year-old woman with left femur tumor that was diagnosed as undifferentiated pleiomorphic sarcoma is presented as a case illustration (Figure 2).

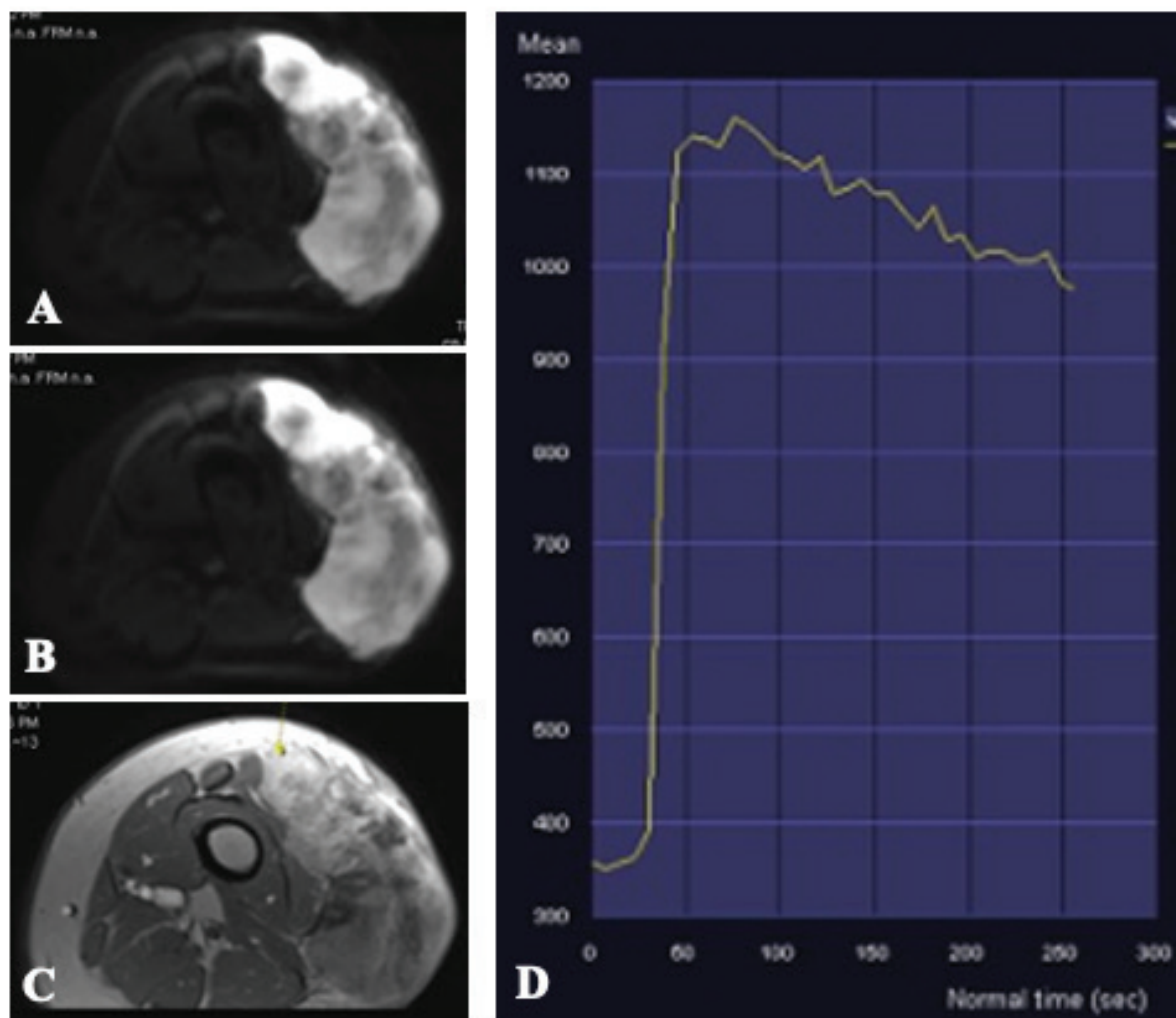


Figure 2. A case illustration of the radiodiagnostic result of a 55-year-old woman with left femur tumor which diagnosed as undifferentiated pleiomorphic sarcoma. (A) Diffusion weighted imaging (DWI) sequence appears to be restricted diffusion in areas with malignancy. (B) Apparent diffusion coefficient (ADC) sequence appears unrestricted diffusion in areas with malignancy. (C) Axial cross-section image after injection of contrast dynamic contrast enhancement. (D) Time intensity curve (TIC) graph generated after placement of ROI shows type 4 TIC.

TIC signal intensity enhancement parameters

The overall mean values of ADC was $0.84 \pm 0.14 \times 10^{-3} \text{ mm}^2/\text{s}$, steepest slope was $15.88\% \pm 19.93\%$ and MER was $129.39 \pm 76.06\%$ (Table 1). Our study showed that squamous cell carcinoma and rhabdomyosarcoma had the highest mean ADC, both $0.999 \times 10^{-3} \text{ mm}^2/\text{s}$ and malignant peripheral nerve sheath tumor (MPNST) and malignant round cell tumor had the lowest mean ADC,

$0.611 \times 10^{-3} \text{ mm}^2/\text{s}$ and $0.749 \times 10^{-3} \text{ mm}^2/\text{s}$, respectively (Table 1). Squamous cell carcinoma had the lowest steepest slope while MPNST had the highest steepest slope with 2.45% and 75.43%, respectively. The mean MER in myxofibrosarcoma (267.87%) and primitive neuroectodermal tumor (PNET) (251.01%) were the highest among other malignant soft tissue tumors. The lowest MER was found in leiomyosarcoma (26.55%) (Table 1).

Table 1. Mean ADC, steepest slope, and MER based on the histopathological types of malignant soft tissue tumors (n=30)

Histopathological types	Mean value		
	ADC($10^{-3} \text{ mm}^2/\text{s}$)	Steepest slope (%)	MER (%)
Adenocarcinoma	0.935	8.08	135.51
Leiomyosarcoma	0.913	23.98	26.55
Malignant round cell tumor	0.749	29.63	88.45
Malignant mesenchymal tumor	0.840	4.45	153.17
MPNST	0.611	75.43	150.71
Myxofibrosarcoma	0.988	7.11	267.87
Myxoid liposarcoma	0.829	13.01	67.38
PNET	0.933	12.66	251.01
Rhabdomyosarcoma	0.999	3.79	143.13
Squamous cell carcinoma	0.999	2.45	183.07
Synovial sarcoma	0.828	16.01	134.61
UPS	0.798	14.15	109.56
All types	0.84 ± 0.14	15.88 ± 19.93	129.39 ± 76.06

ADC, apparent diffusion curve; MER, maximal enhancement relative; MPNST, malignant peripheral nerve sheath tumor; PNET, primitive neuroectodermal tumors; SD, standard deviation; UPS, undifferentiated pleomorphic sarcoma.

Discussion

In the present study, malignant soft tissue tumors were prevalent among those older than 50 years and occurred equally in both genders. Similar findings were observed in a previous study.¹³ Furthermore, our study also showed that type 4 and type 3 TIC were the most common TIC types. A previous study found that 50% of the patients with malignant soft tissue tumor had type 4 TIC, 33% had type 3 TIC, 17% had type 2 TIC patients, and no patient had type 1 and type 5 TIC.¹⁴ High perfusion and permeability of endothelial could be reflected with high enhancement intensity and contrast uptake in advanced MRI. The TIC type reflects dynamic changes in blood flow and intra-tumor perfusion. The pattern on TIC could suggest the physiology of tumor tissues, where this pattern can be used to determine the angiogenesis patterns the tumors.¹⁴

ADC is potentially to be used to differentiate benign and malignant soft tissue tumors. A study found that the mean of ADC of soft tissue tumors was $0.90 \pm 0.70 \times 10^{-3}$ mm²/s and has been proven to be beneficial in differentiating benign and malignant tumors.¹⁵ Another study also found similar mean ADC, $0.84 \pm 0.14 \times 10^{-3}$ mm²/s and suggested negative correlation between ADC and tumor cellularity degree.⁷ Moreover, a study stated that the mean ADC $> 2.5 \times 10^{-3}$ mm²/s yielded a high sensitivity (80%) and a high specificity (100%) in diagnosing cysts and benign cystic lesions.¹⁶ ADC is relatively low in several types of non-myxoid malignant tumors, including MPNST, lymphoma, undifferentiated high-grade pleomorphic sarcoma, and Ewing sarcoma.⁽⁴⁾ This supports our current findings which showed lower ADC in MPNST and undifferentiated pleomorphic sarcoma compared to myxoid liposarcoma and myxoid fibrosarcoma.

The steepest slope graph might help to differentiate benign and malignant soft tissue tumors.¹⁴ A study found that the steepest slope increase for $> 30\%$ per minute was observed in 84% of malignant soft tissue tumors.¹² Malignant tumor has a high vascularization and a relatively limited interstitial space which results in a high rate of achieving the contrast-enhanced state. In contrast, benign tumor has a low perfusion rate and a relatively wide interstitial space resulting to a late contrast-enhanced state. Our findings are in line with the

study by Tubbileket *et al.*¹² High microvascular density and infiltrated muscle tissue will lead to the early contrast-enhancement in DCE-MRI and tend to have higher steepest slope.¹⁷ Nevertheless, although the malignant tumors usually have higher contrast-enhancement, several benign tumors such as hemangioma, myositis ossificans, and aggressive fibromatosis, may show high contrast-enhancement.¹²

Our study suggested that the mean MER tended to be higher in type 4 TIC than type 3 TIC and early contrast-enhancement indicated malignancy in the histopathologic examination. These findings are in line with a previous study that stated the benefits of TIC in differentiating benign and malignant lesions.¹⁴ Another study also found that rapidly growing and rapidly washing out of TIC consistently reflect tumor malignancy.¹⁸

This study has some limitations. Although we retrieved the data for two-year period, the number of patients that were eligible was relatively small. In addition, limited ROI placements in our study which was only three and different sampling locations might potentially cause variability.

Conclusion

Understanding of ADC and TIC parameters of advanced MRI of the malignant soft tissue tumors is important to determine or distinguish the histopathologic type. In the present study, type 4 and 3 are two of the most common TIC among malignant soft tissue tumors. Our initial data suggest that ADC, steepest slope, and MER might potentially correlated with the type of malignant soft tissue tumors. However, further studies are warrant to provide more robust data.

Acknowledgement: We would like to thank Dr. Soetomo Hospital Surabaya, Indonesia in providing the data for analysing.

Ethical Clearance: The protocol of this study was approved by Institutional Ethics Committee of Dr. Soetomo Hospital, Surabaya, Indonesia, 0162/LOE/301.4.2/X/2020.

Source of Funding: Self

Conflict of Interest: Nil

References

1. Sjamsuhidajat Rand Jong WD. Soft Tissue Tumor. In: Sjamsuhidajat R and Jong WD, editor. *Buku Ajar Ilmu Bedah*. 2nd ed. Jakarta: EGC; 2005.
2. Mahyudin F. Diagnosis dan Terapi Tumor Musculoskeletal (Multidisiplin Approach). Jakarta: SagungSeto. 2018.
3. Bruno F *et al*. Advanced magnetic resonance imaging (MRI) of soft tissue tumors: techniques and applications. *Radiologia Medica*. Springer Milan. 2019;124(4):243–252. doi: 10.1007/s11547-019-01035-7.
4. Costa FM, Ferreira EC, Vianna EM. Diffusion-weighted magnetic resonance imaging for the evaluation of musculoskeletal tumors. *Magnetic Resonance Imaging Clinics of North America*. 2011;:159–180. doi: 10.1016/j.mric.2010.10.007
5. Subhawong TK, Wilky BA. Value added: Functional MR imaging in management of bone and soft tissue sarcomas. *Current Opinion in Oncology*. 2015;27(4):323–331; doi: 10.1097/CCO.000000000000199.
6. Koh DM, Collins DJ. Diffusion-weighted MRI in the body: Applications and challenges in oncology. *American Journal of Roentgenology*. 2007;188(6):1622–1635; doi: 10.2214/AJR.06.1403.
7. Maeda M. *et al*. (2007) ‘Soft-tissue tumors evaluated by line-scan diffusion-weighted imaging: Influence of myxoid matrix on the apparent diffusion coefficient’, *Journal of Magnetic Resonance Imaging*, 25(6), pp. 1199–1204; doi: 10.1002/jmri.20931.
8. Costa FM, Canella C, Gasparetto E. Advanced magnetic resonance imaging techniques in the evaluation of musculoskeletal tumors. *Radiologic Clinics of North America*. Elsevier Inc. 2011;49(6):1325–1358; doi: 10.1016/j.rcl.2011.07.014.
9. Westbrook C, Roth K, Talbot J. MRI in Practices. 4th ed. United Kingdom: Blackwell Publishing Ltd. 2011.
10. Drapé JL. Advances in magnetic resonance imaging of musculoskeletal tumours. *Orthopaedics & traumatology, surgery & research : OTSR*. Elsevier Masson SAS. 2013;99(1 Suppl):S115–S123; doi: 10.1016/j.otsr.2012.12.005.
11. De Coninck T *et al*. Dynamic contrast-enhanced MR imaging for differentiation between enchondroma and chondrosarcoma’ *European Radiology*. 2013;23(11):3140–3152; doi: 10.1007/s00330-013-2913-z.
12. Tucbilek N *et al*. Dynamic contrast enhanced MRI in the differential diagnosis of soft tissue tumors. *European Journal of Radiology*. 2005;53; doi: 10.1016/j.ejrad.2004.04.012
13. Lee JH *et al*. Development and Validation of Nomograms for Malignancy Prediction in Soft Tissue Tumors Using Magnetic Resonance Imaging Measurements. *Scientific Reports*. Nature Publishing Group. 2019;9(1); doi: 10.1038/s41598-019-41230-0.
14. Park MY *et al*. Preliminary experience using dynamic MRI at 3.0 tesla for evaluation of soft tissue tumors. *Korean Journal of Radiology*. 2013;14(1):102–109; doi: 10.3348/kjr.2013.14.1.102.
15. Pekcevik Y *et al*. Characterization of Soft Tissue Tumors by Diffusion-Weighted Imaging. *Iran J Radiol*. 2015;12(3):e15478; doi: 10.5812/iranjradiol.15478v2.
16. Subhawong TK, Jacobs MA, Fayad LM. Insights into quantitative diffusion-weighted MRI for musculoskeletal tumor imaging. *American Journal of Roentgenology*. 2014;203(3):560–572; doi: 10.2214/AJR.13.12165.
17. Lang N, Su MY, Xing X, Yu HJ, Yuan H. Morphological and Dynamic Contrast Enhanced MR Imaging Features For The Differentiation Of Chordoma And Giant Cell Tumors In The Axial Skeleton. *J Magn Reson Imaging*. 2017;45(4):1068–1075; doi: 10.1002/jmri.25414.
18. Sundareswaran N dan Elanchezhian E, ‘ Role of Time Intensity Curve in Dynamic Contrast MRI Evaluation of Soft Tissue Tumor’, 2020; 5(2):B60-B65; doi: 10.21276/ijcmr.2020.5.2.14.