

Perfusion -Weighted Magnetic Resonance Imaging Techniques and Protocols in the Evaluation of Cerebral Blood Flow, Blood Volume, and Vascular Permeability of Brain Neoplasms

Safa Musadaq Abd-ALRahman¹, Haider Qasim Hamood²

¹M.Sc., Student, ²Prof. Dr., Department of Radiological Techniques- College of Health and Medical Technology- Middle Technical University

Abstract

Objective : To identify the efficiency of perfusion, weighted magnetic resonance imaging techniques and protocols in, evaluation of cerebral blood, flow, blood volume, & vascular, permeability of a tumor in the brain in correlation with viability of brain neoplastic tissues.

Material and Methods : One hundred and fifteen patients with histologically proven brain tumors were examined by 1.5 Tesla PHILIPS MR System. For four months, patients who were referred in an MRI assessment were included in this review. Conventional MRIs protocol, (axial T₂WI (TSE), Axial T₁WI (FSE), axial T₂WI FALIR, axial T₁WI post contrast). PW-MRI protocol axial Fast Echo –Echo Planner Image (FE-EPI) Neuro-T₂* Perfusion Dynamic Contrast Enhancement agent (DCE-MRI), (Gadolinium(Gd) contrast Magnevist).

Results and discussion: Magnetic Resonance Imaging in (10) patients (8.70%) revealed feature consistent with brain tumors (control cases), the brain has been evaluated by routine study or conventional (protocol C). (105) patients (91.3%) underwent examination with PW-MRI (FE-EPI) Neuro-T₂* Perfusion (DCE-MRI) (protocol P). (18) patients (15.65%) with the anaplastic astrocytoma WHO grade (III), (17) patients (14.78%) with metastatic brain tumors, (15) patients (13.04%) with non-recurrence of post-operative brain tumors, (11) patients (9.57%) with high grade glioma, (10) patients (8.70%) with craniopharyngioma, (9) patients (7.83%) with glioblastoma multiform WHO grade IV, (9) patients (7.83%) with low grade glioma, (8) patients (6.96 %) with meningioma, the agemistocytic astrocytoma WHO grade(II) was the lowest diagnosed brain tumor (2.61%).

Keywords: *Perfusion MRI, Brain neoplasms, cerebral blood flow, cerebral blood volume, Vascular Permeability*

Introduction

Brain tumors are destructive diseases and the Cancerous brain tumors are uncontrolled. [1]. Cancer is a serious life-threatening disease. [2]. As a tumor grows in the cranium, it must displace or replace the surrounding tissue, the tumor growth-induced deformation of the brain – the so-called “mass effect” – can cause severe disability or death. Perfusion-Weighted Magnetic, Resonance, Imaging (PW-MRI) offers a plethora of additional parameters to resolve the limitations of traditional MRI. PW-MRI can be used to image neovascularization, a

hallmark of tumor progression [4]. Blood vessels are a closed passage system that carries blood across the body. The volume of blood that streams through capillary beds to a tissue is known as tissue perfusion. [5]. The circle of Willis is the most important intracranial pathway for collateral circulation. [3]. The most damaging disease is brain tumors, and cancerous brain tumors are not managed. [1]. The blood-brain barrier (BBB) divides the blood from the parenchyma of the brain and controls the distribution of energy metabolites. [6, 7]. The BBB is essential for maintaining a stable micro - environment

in the central nervous system. [8]. The integrity of the BBB is considered to be affected by tumors, this results in a highly heterogeneous vasculature known as blood-tumor, barrier (BTB). [9]. Cerebral Perfusion is arguably one of the key physiologic parameters in the brain, because it plays a central role to ensure tissue viability and function, cerebral perfusion is responsible for the distribution of oxygen and nutrients and the elimination of waste products so we are not surprised to carry disease process during in one way or distribution cerebral blood supply. [11].

Research Hypotheses: (Index= CBF, Negative Integral = CBV, Mean Transit Time= MTT). [10]. Perfusion parameters have been calculated using this unit:- CBV: cerebral, blood, volume, the volume, of blood per, unit of, brain tissue, (4-5 ml/100g) . CBF: cerebral blood flow, or cerebral perfusion [11]. The amount of blood flow per minute per unit of brain tissue (50-60ml/100g/min) Vascular permeability MTT : mean, transit, time, difference in time between arterial and venous inflow and outflow MTT=CBV/CBF [12].

Material and Methods

A total (115) patients with pre and post-operative of brain tumors from the first of November 2020 to the end of February 2021 were retrospective reviewed. The following are the study’s eligibility requirements (1) All patients in this study were referred to radiology department from the Oncology clinic, and Neurological Sentence clinic the clinical examination with history of brain tumor that demonstrated brain tumors (neoplasms), in Babylon Province. (2) For gadolinium chelate, contrast agent, normal renal function test, normal serum creatinine test. (3) In patients with new diagnosis brain tumor before treatment with radiotherapy & chemotherapy.(4) Preparation, the Patients Before Examination on MRIs. Things that might affect the magnetic imaging: Hearing aids, Jewelry, Hairpins, Watches, Removable dentures, Eyeglasses, Wigs, Underwire bras, Metal-particle-containing cosmetics, Make-up, especially eyelashes, Credit cards. This study include the number patient females (58) cases while the number of patients males (57) cases with all brain tumors distribution in the table 2.1.

Table 1. The Distribution of studied sample according to Age Group, Age, Gender.

		GROUPS						
		Cases(N=105)		Controls(N=10)		Total(N=115)		p. value
		No	%	No	%	No	%	
Age groups	<or =20	11	10.48	0	.00	11	9.57	0.006*
	20-29	31	29.52	0	.00	31	26.96	
	30-39	10	9.52	0	.00	10	8.70	
	40-49	18	17.14	6	60.00	24	20.87	
	50-59	9	8.57	3	30.00	12	10.43	
	60-69	23	21.90	1	10.00	24	20.87	
	≥70	3	2.86	0	.00	3	2.61	
Age		Mean ±SD=39.50±19.42		Mean ±SD=44.5±18.9				
	Total	105	100.00	10	100.00	115	100.00	
Gender	Males	50	47.62	7	70.00	57	49.57	0.176
	Females	55	52.38	3	30.00	58	50.43	

Acquisition Images: The PHILIPS Achieva 1.5Tesla magnetic resonance imager was used to test all of the patients. Brain MRIs are typically done on the exam room sofa, with the patient supine, arms beside the trunk, ear plugs, and the head placed within the Birdcage head coil In the midline of the patient lies the longitudinal

alignment red leaser light, while the horizontal alignment light passes through the nasion. With the patient’s head fixed in the head coil using a vacuum cushion. (10) from patients examined by conventional protocol axial T1WI-SE, axial T2 WI-TSE, axialT2 FLAIR, axial T1 post contrast, (105) from patient examined by PW-MRI(FE-EPI) (DCE). All the protocols in the (Table2.2).

Table 2: Parameters of MRIs 1.5 T Phillips Systems Protocol C & Protocol P

Study	Sequence	Slice orientation	TR ms.	TE ms.	FOV Mm	Slice Thickness	Gap Mm	Matrix
Routine Study (Conventional protocol C)	T2WI-TSE	Axial	5285.7	110.0	230x180	5mm	0	256x161
	T1WI-SE	Axial	650.0	15.0	230x180	5mm	0.5	256x163
	T2 FLIAR	Axial	6000.0	120.0	230x180	5mm	5	240x144
	T1 post (Gd.)	Axial	450.0	15.0	230x180	5mm	0.5	256x163
Additional								
Perfusion weighted MRIs (Protocol P)	FE-EPI	Axial	2485.5	40.0	220x220	5mm	0.5	88x89

PW-MRI T₂*Dynamic contrast enhancement(DCE) scan: Dynamic scanning the method for acquiring a series of MRIs for 40 dynamic scan, every nine milliseconds and eight-tenths he takes an image with one slice for each phase,(Gadolinium(Gd) contrast Magnevist (1mL) contains Dimeglumine gadopentetate 469mg, each vial or package contains 20 mL Bayer Pharma AG Germany, Gd using a standard dose 0.1mmol/kg - 0.2mmol/kg body weight, viewing the wash-in and wash-out of contrast MRI to improve appearance & detection of brain tumors, appropriate venous access, The injection rate is best performed using an MRI injector with a flow rate of at least 2ml /S with a subsequent flash of 0.9% saline solution.

Post processing the PW-MRI: Raw data were imported into the Philips MR Systems all MRIs were transferred to a Unix workstation Images were displayed and processed with the software package MR Vision the software to post process these data is widely available and relatively straightforward to use, evaluation of the scan can be done with the” Neuro T₂*perfusion” package, one calculation is based on a curve fit algorithm, from FE-EPI neuro- perfusion select image processing workstation using built-in analysis software to automatically.

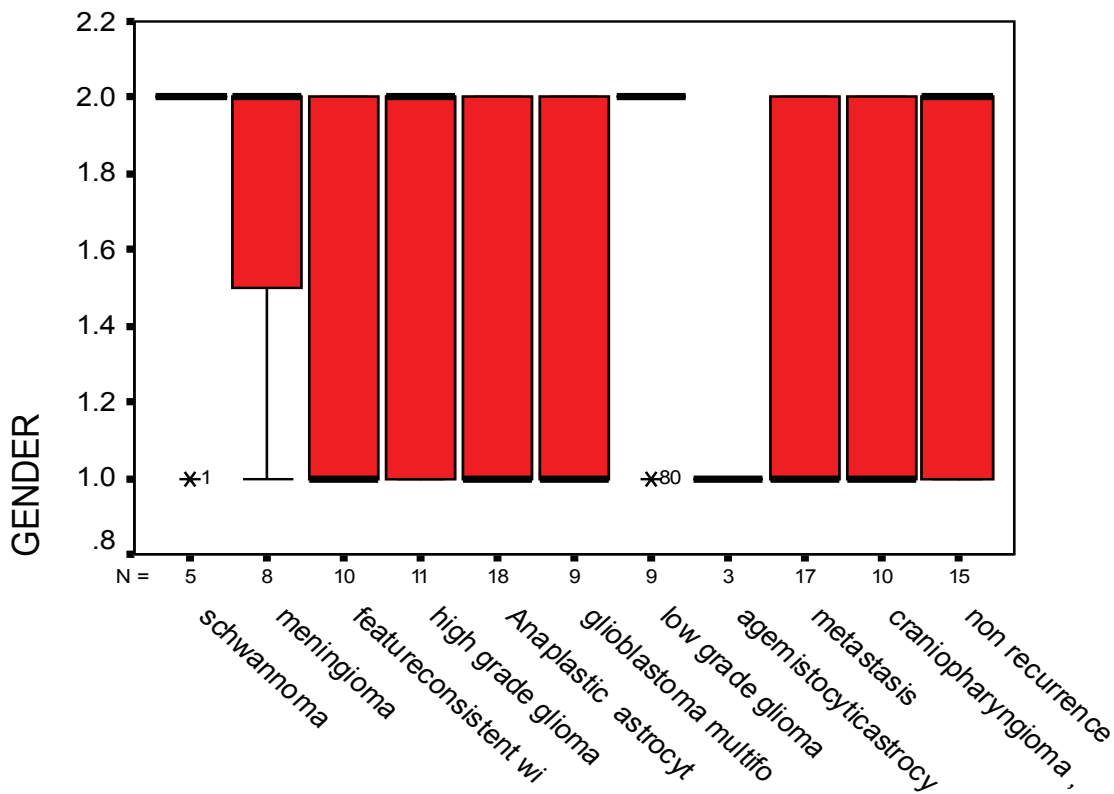
ROI Positioning: The phase involves manually drawing a ROI along the tumor’s margins so that the program can correctly measure perfusion values. When

placing the ROI, careful care should be taken not to include the great vessels, air, or surrounding fatty tissue, and to ensure that the ROI does not spread beyond the tumor’s margins. The ROI must be located at the inner margins of the tumor in all perfusion scan images. For this reason, an accurate assessment of all images must be performed in cine-loop mode. From Gamma Variate Fitting Through maps, to select the map of interest adjust Threshold strong, and select apply spatial smoothing strong and generate parameters (Index= CBF, Navigate Integral (NI)= CBV, Mean Transit Time(MTT)=

vascular permeability).

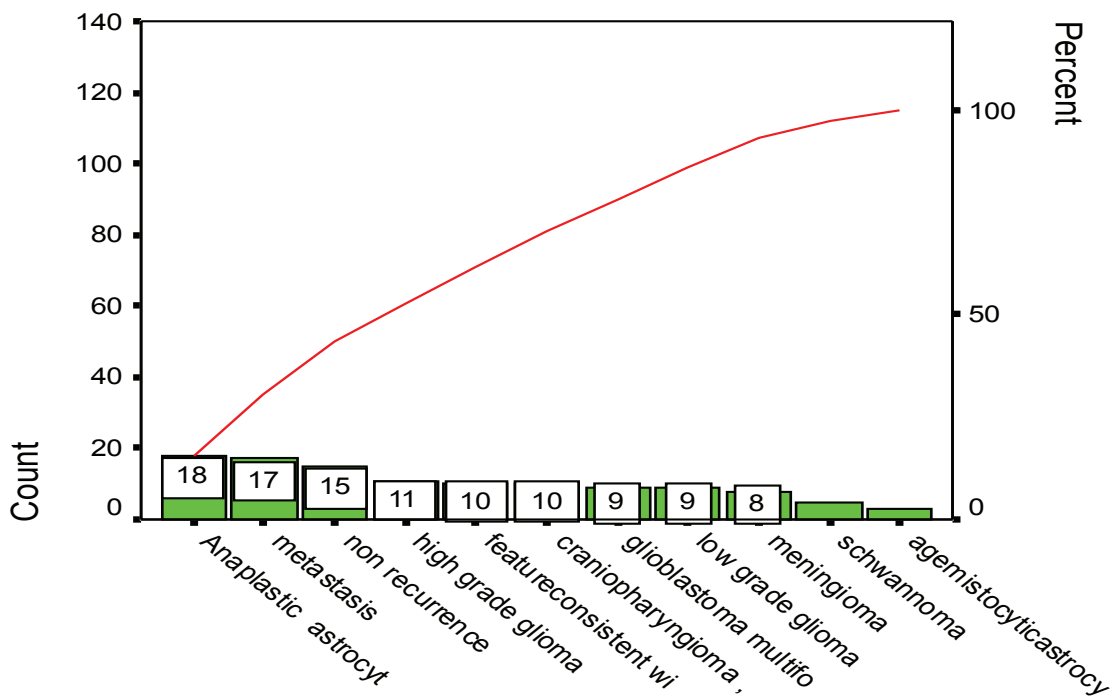
Result and Discussion

In current study, the distribution of the studied sample according to demographic characteristics, the mean age of study sample for cases $M \pm SD = 3.50 \pm 19.42$ while for control groups was $M \pm SD = 44.5 \pm 18.9$. 31 patients aged 20-29 years (26.96%) were the highest affected age group while 23 patients aged 60-69 years old were the lowest affected age group (20.87%).



Diagnosis:-

Figure (1) The figure shows the distribution of types of tumors according to gender



Diagnosis:-

Figure (2) The figure shows that Anaplastic astrocytoma WHO grade (III) is the higher brain tumor type, occurrence in (18) patients, while the lowest brain tumor is agemistocytic astrocytoma WHO grade (II) (3) patients .

Table 3: The Distribution the patients with classification brain tumors and normal patients according to parameters of perfusion weighted MRIs cerebral blood flow, blood volume, and vascular permeability

		N	Mean	Std. Deviation	F test	P. value
Index mL/100g /min	Primary	24	1.6400	.47274	11.663	.0001*
	secondary	66	3.1011	2.54800		
	Normal	15	.5453	.26115		
	Total	105	2.4020	2.24891		
NI mL/100g	Primary	24	24.3529	19.20694	6.011	.0031*
	Secondary	66	38.3992	39.60856		
	Normal	15	7.4000	1.51678		
	Total	105	30.7602	34.46203		
Vascular Permeability ,MTT =CBV/CBF sec	Primary	24	15.4504	13.51087	.195	.824
	Secondary	66	14.3714	11.04183		
	Normal	15	16.1520	7.38286		
	Total	105	14.8724	11.15265		

The significant differences were found primary, secondary brain tumors and normal patients Index $p < 0.0001^*$, the mean primary $M \pm SD = 1.6400 \pm 0.47274$, while the mean secondary $M \pm SD = 3.1011 \pm 2.54800$. Regarding The significant differences were found primary, secondary brain tumors and normal patients NI $p < 0.0031^*$, the mean primary $M \pm SD = 24.3529 \pm 19.20694$, while the mean secondary $M \pm SD = 38.3992 \pm 39.60856$

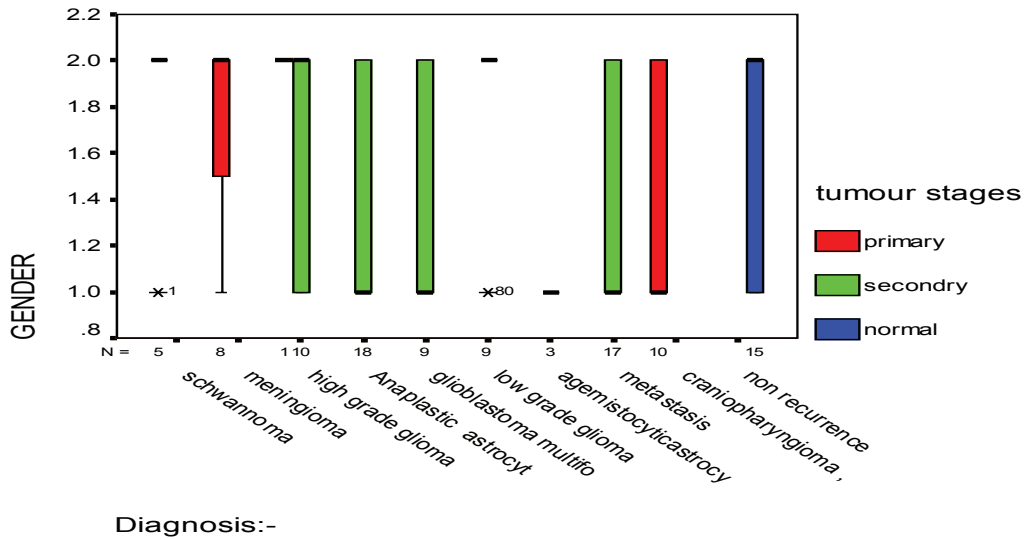


Figure (3.3) The Distribution the patients with classification primary, secondary, and normal brain tumors according to all types of brain tumors

As shown in Figure (3.4) Patients (41) years old male single mass post-operative recurrence tumors results correlation with histopathology, (protocol C) (a)T1 WI, (b)T2 WI,(c) T2 FLAIR,(d) sagittal T2 WI, (e) T1 post (Gd) contrast (p) perfusion weighted parameters (A Index, B NI, C MTT)

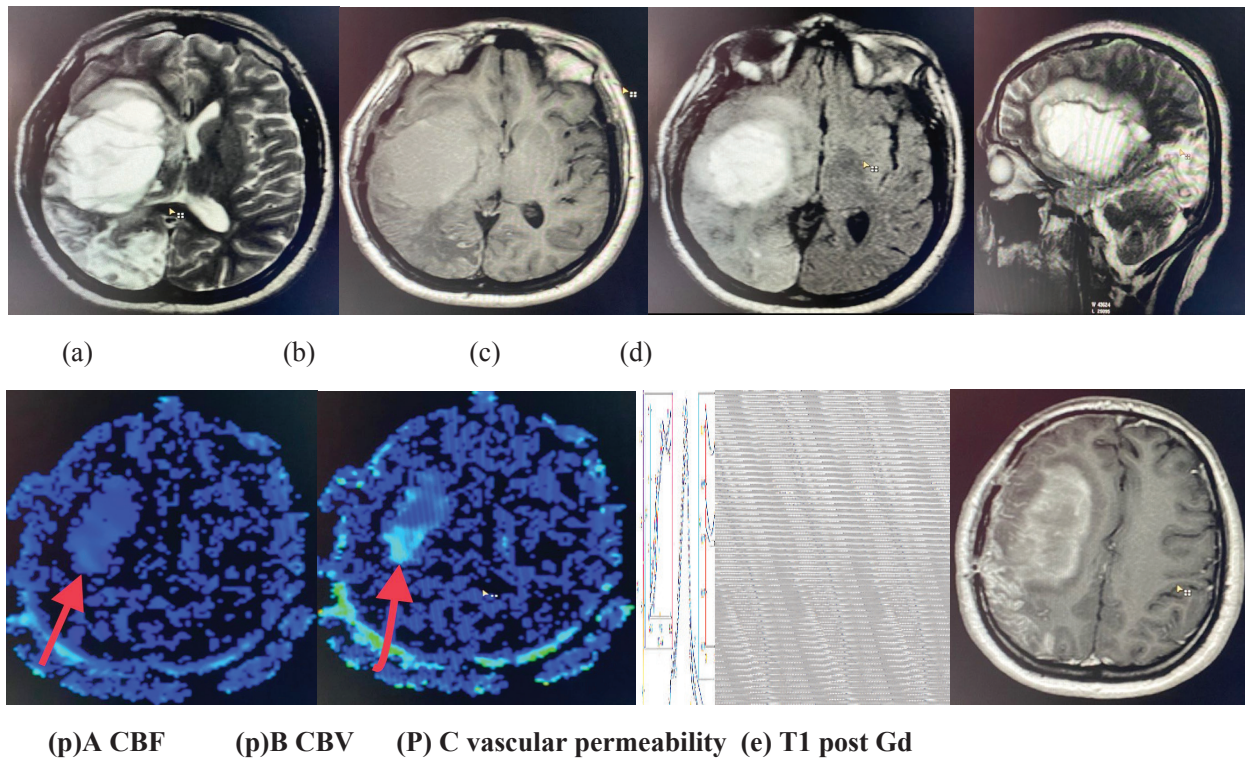


Figure (3.4) shows MRI of the brain tumors (Anaplastic astrocytoma WHO grade (III) in all protocols

In our study, (10) patients evaluated with MRIs of the brain by protocol C (conventional or standard examination) and (105) patients protocol P (perfusion weighted magnetic resonance imaging) showing the sensitivity and specificity to demonstrate the brain tumors. Protocol C shows the anatomical zone mass with limited diagnostic features consistent with brain tumors, while the (protocol P) was better than (protocol C), (protocol P) FE-EPI has sensitivity, specificity and diagnostic accuracy about (100%), the highest hyper-perfusion percentage about (78.26%), total time of these sequences less (1:49min). In this sequence we get (1040) images, in addition to that, the perfusion imaging technique is a homogenous technique with using an intravenous contrast agents, gadolinium, the method called EPI Neuro-perfusion T₂* Dynamic technique. Dynamic contrast enhanced (DCE-MRIs) is the preferred method in-vivo [13]. We used (PW-MRI) sequence the new protocol for demonstrate (CBF), (CBV), and (vascular permeability). Sensitivity, specificity and accuracy were about (100%) in all types and grades of brain tumors. The glioblastoma multiform WHO grade IV type brain tumors mean was (M±SD=3.8344±3.92235), while the mean of Anaplastic astrocytoma WHO grade (III) was (M±SD=3.2344±3.15817). Sensitivity and specificity accuracy index was about (100%) in the patients with classification of brain tumors, the mean of primary brain tumors was (M±SD=1.6400±0.47274), while the mean of secondary brain tumors was (M±SD=3.1011±2.54800) in sixty six cases of (105) cases, also the mean in post-operative, non-recurrence brain tumors was (M±SD=0.5453±0.26115). NI sensitivity and specificity accuracy was (100%) about the site of all brain tumors. The significant differences were found primary, secondary brain tumors and control cases NI p< 0.0031*, the mean of primary brain tumors was (M±SD=24.3529±19.20694), while the mean of secondary was (M±SD=38.3992±39.60856). PW-MRI can reflect tissue perfusion and microvascular permeability, and infiltrating tumors could be characterized by abnormal permeability, the significant differences were found in primary, secondary brain tumors and control cases, MTT p<0.824. MTT sensitivity and specificity accuracy was (100%) in all types and grades

of brain tumors, the mean of Anaplastic astrocytoma WHO grade(III) was (M±SD=11.7617±6.26837).

In current study, the stage is very important determinant of survival [14], the highest diagnosis percentage (15.65%) the anaplastic astrocytoma WHO grade (III) of all type of brain tumors, while the lowest percentage (2.61%) with the gemistocytic astrocytoma WHO grade(II) Since MRIs can be used to determine tumor vascularity quantitatively, (PW-MRI) (DCE-MRIs) can be used to measure the tumor's cerebral blood flow, which represents underlying tumor vascularity. High grade glioma, Anaplastic astrocytoma tend to have higher (CBF) and (CBV) than low grade glioma but lower (CBF) and (CBV) glioblastoma. In this study can be done with a 1.5 T MRI system or a 3T MRI device even provide us with more knowledge and specifics about brain tumors.

Conclusion

Role of Cerebral perfusion weighted magnetic resonance imaging increase in detection of brain neoplasms the recently. FE-EPI Neuro-Perfusion T₂* Dynamic imaging after an intravenous injection of tracer is an attractive or efficiency technique to measure cerebral blood flow, cerebral blood volume, and BTB or vascular Permeability. A broad class of heterogeneous neoplasms, which will provide us with more knowledge and data about the brain tumors Glioblastoma multiform WHO grade (IV) is a tumors more aggressive and poorly differentiated tumor that percentage (7.83%) of all type of tumors occurs in males percentage (10.53%) more than females percentage (5.17%), and it is very malignant. This method is recommended by us.

Financial Disclosure: There is no financial disclosure.

Conflict of Interest: None to declare.

Ethical Clearance: "All experimental protocols were approved under the College of Health and Medical Technology- Middle Technical University were carried out in accordance with approved guidelines".

References

1. Rehman A, Naz S, Razzak I. A Deep Learning-Based Framework for Automatic Brain Tumors Classification Using Transfer Learning. 2019: 1-2.
2. Wen G, Li X, Zhang Y. Effective Phototheranostics of Brain Tumor Assisted by NearInfrared-II Light-Responsive Semiconducting Polymer Nanoparticles, 2020; (12); 33492–33499.
3. Li J, Jue , Wang J, Wei X, Zhao Y. Examination of Structural Variations of the Circle of Willis by 3D Time-of-Flight Magnetic Resonance Angiography, University Shanghai China, 2020 :1.
4. Dijken van J, Laar van J, Smits M. Perfusion MRI in Treatment Evaluation of Glioblastomas: Clinical Relevance of Current and Future Techniques, American Journal of Magnetic Resonance Imaging 2019 ; (49);11-22:12.
5. Amerman C. Exploring Anatomy &Physiology in the laboratory ,third edition, printed in the United States of America. 2017 ; (1);1-776: 510
6. Montagne A, Zhao Z, Zlokovic V. Alzheimer’s disease: A matter of blood–brain barrier dysfunction? 2017; 1.
7. Zhao, Z, Sagare P, Ma Q, Halliday R. Central role for PIC ALM in amyloid- β blood-brain barrier transcytosis and clearance. Nat. Neurosci, 2015; 18(7): 978–987
8. Jafari B, Pourseif M. Peptide-mediated drug delivery across the blood brain barrier for targeting brain tumor. 2019; 1,2.
9. Aravnitis D, Ferraro B, Jain K. The blood–brain barrier and blood–tumor barrier in brain tumors and metastases, 2020 ; (20):26–41.
10. Fei Q, Qian X, Zhang J, Guo J. The Utility of Diffusion and Perfusion Magnetic Resonance Imaging in Target Delineation of High-Grade Gliomas. 2020.
11. Saremi F. perfusion imaging in clinical practice a multimodality approach to tissue perfusion analysis , printed in china. 2015 ; (1);1-592:101.
12. Goyal S, Taylor, Francis. Neuroradiology A case-based guide ,first edition, 2021; (1);1-191:47-49.
13. Verheggen M, Jong D . Increase in blood–brain barrier leakage in healthy, older adults, Official Journal of the American Aging Association (AGE), 2020; (42);1183-1193
14. Lu J, Brady L. Decision Making in Radiation Oncology. Berlin: Springer. 2011;.(2) ; 533- 1105.