

# Non-Surgical Management of an Anterior Tooth with Internal Inflammatory Resorption: A Case Report

Karthik Shetty<sup>1</sup>, Keerthana Kunaparaju<sup>2</sup>, Ankita Kanotra<sup>3</sup>, Anushka Arora<sup>4</sup>, Ishani Saluja<sup>2</sup>

<sup>1</sup>Professor and Head of the Department, <sup>2</sup>Third Year Post Graduate, <sup>3</sup>Consultant Endodontist, <sup>4</sup>First Year Post Graduate, Department of Conservative Dentistry and Endodontics, Manipal College of Dental Sciences, Mangalore, Affiliated to Manipal Academy of Higher Education, Manipal

## Abstract

**Background:** According to the Glossary of the American Association of Endodontists, resorption is defined as a condition associated with either a physiologic or a pathologic process resulting in the loss of dentin, cementum, or bone. It may present internally (pulpal origin) or externally (periodontal origin). Internal resorption is a rare, insidious, resorptive pathological process, starting from the pulp extending into the surrounding dentin. Treatment is mainly focused on arresting the cellular activity accounting for the resorptive process.

**Methodology:** A patient presented with an upper front tooth that was tender on percussion and a history of trauma in her childhood which resulted in Ellis class II fracture of the tooth. Pulp sensibility testing showed a negative response suggestive of a non-vital tooth. A non-surgical endodontic therapy was carried out under the microscope with calcium hydroxide dressings followed by the three-dimensional obturation technique using thermoplasticized Gutta percha.

**Conclusion:** The current case report discusses the etiology and symptoms of internal inflammatory resorption, the contribution of cone beam computed tomography imaging in its diagnosis, and a step wise protocol for the three dimensional obturation of the resorptive lesion.

**Keywords:** *BioRoot RCS, Cone beam computed tomography, Internal inflammatory resorption, Thermoplasticized obturation, Warm vertical compaction.*

## Introduction

Internal inflammatory resorption is a defect associated with chronic pulpal inflammation or trauma initiated due to the odontoclastic activity. Bacterial contamination, vital pulp therapy, orthodontic and transplantation procedures were known to be the other

causes.<sup>1,2</sup>Internal resorption is more frequently observed in permanent anterior teeth.

Osteoprotegerin, the receptor activator of nuclear factor kappa - B ligand (RANKL), the receptor activator of nuclear factor kappa - B (RANK) and the macrophage colony -stimulating factor (MCSF) are the main components of inflammatory cascade in the pulp that initiate the differentiation of stem cells to odontoclasts which are responsible for resorption.<sup>3</sup>

Diagnosis of internal resorption depends on the localization and severity of the resorption. Majority of the cases are asymptomatic, therefore it is coincidentally noticed during routine radiographic investigations. However, symptoms such as pain, swelling, sinus tract, discoloured tooth, may be present in advanced

---

### Corresponding author:

**Dr. Keerthana Kunaparaju**

Third Year Post Graduate, Department of Conservative Dentistry and Endodontics, Manipal College of Dental Sciences, Mangalore, Affiliated to Manipal Academy of Higher Education, Manipal

Phone number: 9535398089

Email: drkeerthana7495@gmail.com

cases.<sup>1</sup>When it is seen in the coronal aspect, a typical pinkish hue known as a “pink spot” is noticed which is attributed to the vascular connective tissue containing the osteoclast.

The defect may be uniform, round to oval in shape with clear margins but the canal space is usually irregular, as seen on a radiograph.<sup>4</sup>Early identification and appropriate treatment of internal root resorption is essential for a good prognosis of the tooth.<sup>2</sup>Determining the borders of the lesion helps in determining the treatment plan. Therefore, three-dimensional evaluation of the lesion with modalities such as the cone beam computerized tomography provides accurate information that helps in diagnosis and treatment planning of the defect.<sup>5</sup>

Non-surgical endodontic treatment is usually successful for internal defects limited to the root canal system.<sup>6</sup> In such cases, the goal of the treatment is to remove the necrotic pulp tissue, halt the resorptive activity and completely fill the root canal as well as the resorptive defect with the obturating material.<sup>2</sup> The current case report aims to discuss the management

of an internal inflammatory resorptive defect in the apical region of an upper central incisor with the use of thermoplasticized obturation technique for the obturation.

### Case Report

A 26 year old patient reported to the hospital with a complaint of severe tenderness on percussion w.r.t upper left front tooth (#21). She presented a history of dental trauma w.r.t #21 at the age of 9 that resulted in Ellis class 2 fracture of the tooth. Repeated composite restorations were done in relation to the involved tooth since the age of 16. Pulp sensibility tests (Cold and electric pulp testing) w.r.t #21 revealed no response, suggestive of a non-vital tooth.

The radiograph (IOPA) showed a well-defined internal resorptive defect at the junction of the middle and apical third of the root. A CBCT was advised to rule out any external communication of the defect and it subsequently confirmed the presence of an internal resorptive defect in the apical third confined to the internal wall of the canal with no communication with the external root surface or periodontal tissues (Fig1).

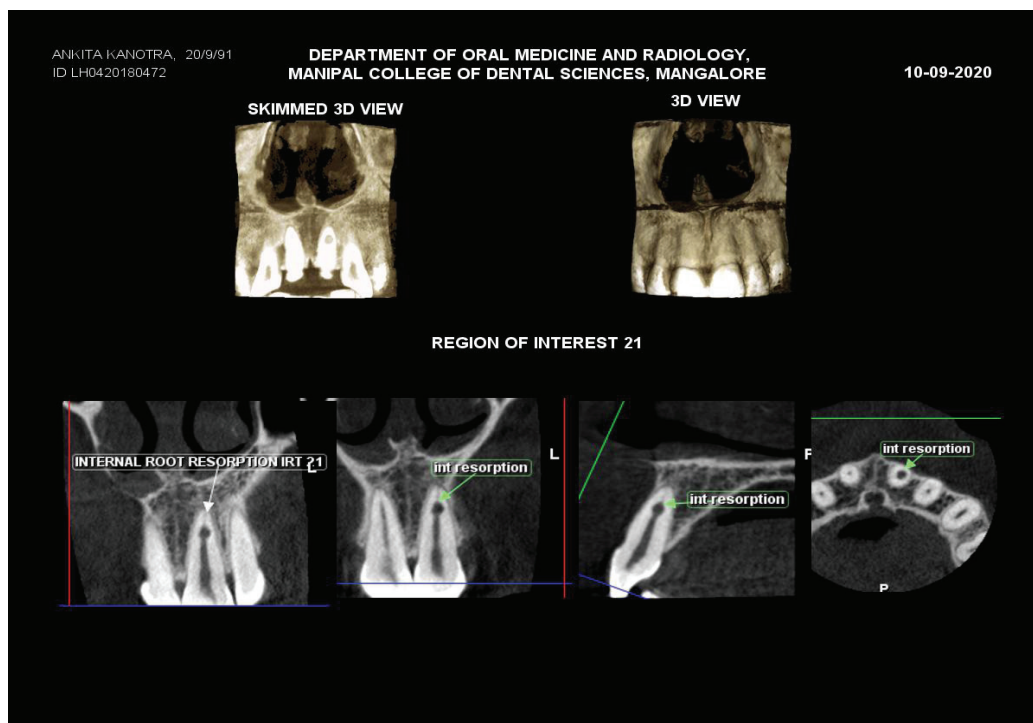


Fig: 1 – Cone beam computed tomography showing the resorptive defect in different planes.

The periapical area w.r.t #21 showed no pathological signs of inflammation. Based on the findings, tooth was diagnosed as symptomatic chronic irreversible pulpitis with internal inflammatory resorptive defect. After discussing all possible treatment options with the patient, the non-surgical endodontic treatment option was finalized to treat the canal with internal resorptive defect.

### Procedure

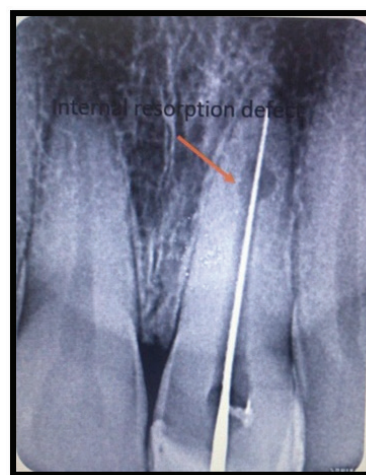Prior to the procedure, patient consented for the treatment. Following administration of local anaesthesia (lidocaine HCl 2%, 1:1,00,000), isolation was achieved using rubber dam (Hygenic Dental Dam, Coltene Whaledent, Germany) and access cavity was performed using Endo-Access bur (Dentsply Maillefer, USA) w.r.t. #21. The cavity was refined using endodontic ultrasonic tips (Startex No.1 Dentsply Switzerland) to achieve a straight line access to the defect. The initial scouting and canal patency up to the full working length was achieved with #6K file (Dentsply Sirona). The working length was confirmed with an apex locator (Root ZX II; Morita, Tokyo, Japan).

The internal resorptive defect was carefully bypassed during subsequent instrumentation with sequentially larger sized files. Biomechanical preparation of the canal was performed in a crown-down fashion with the Protaper Universal system (Dentsply Maillefer, USA) up to file size (#F3), under constant irrigation with 2.5% NaOCl (Septodont, India) and normal saline. Ultrasonic irrigation was performed with Irrisafe tips (Satelec, France) and an intra-canal calcium hydroxide dressing was given. The tooth was temporarily restored with Cavit (3M ESPE, USA). After two weeks the tooth was asymptomatic and the intra-canal dressing was removed using 10% citric acid along with ultrasonic irrigation.

As the internal defect was located at the junction of the middle and apical third of the canal, sectional obturation of the apical third was carried out with a single cone technique with Bio root RCS sealer followed by warm vertical compaction of the GP into the defect. The remainder of the canal was coated with zinc oxide based sealer (Tubli Seal™, Kerr Endodontics) and was

backfilled with thermoplasticized GP, with the help of Elements obturation system (Sybron Endo, Kerr Dental USA). The step wise protocol for the obturation is given as follows:

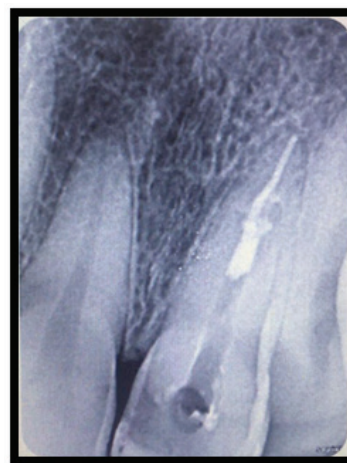Step1: The master cone selected was coated with BioRoot RCS sealer and was fitted up to the full length of the root which was confirmed with a radiograph. (Fig 2)



**Fig 2: Master cone fit**

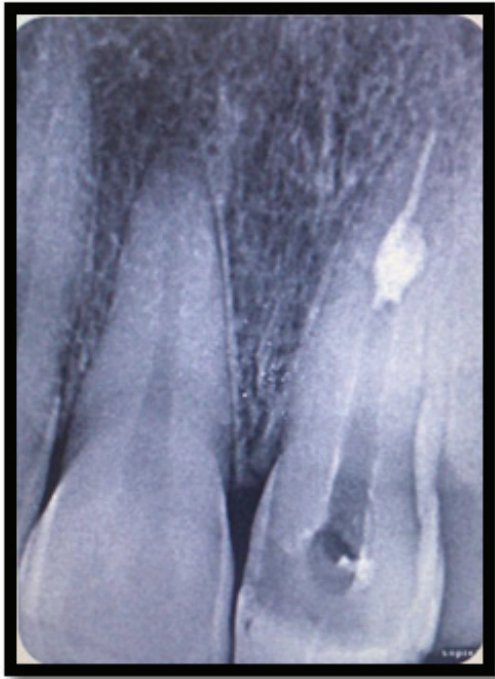Step 2: The heated plugger was used to sever the GP at the level of the orifice of the root canal.

Step 3: The Fine heated plugger was then driven into the canal to remove the GP, 2 mm short of the resorptive defect. (Fig 3)



**Fig 3: Excess GP removed**

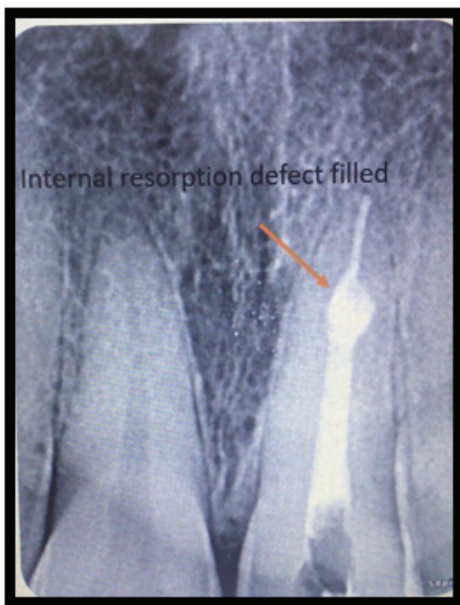Step 4: A Buchanan hand plugger size 2 was then used to compact the GP into the resorptive defect. (Fig 4)



**Fig 4: GP plugged into the resorptive defect**

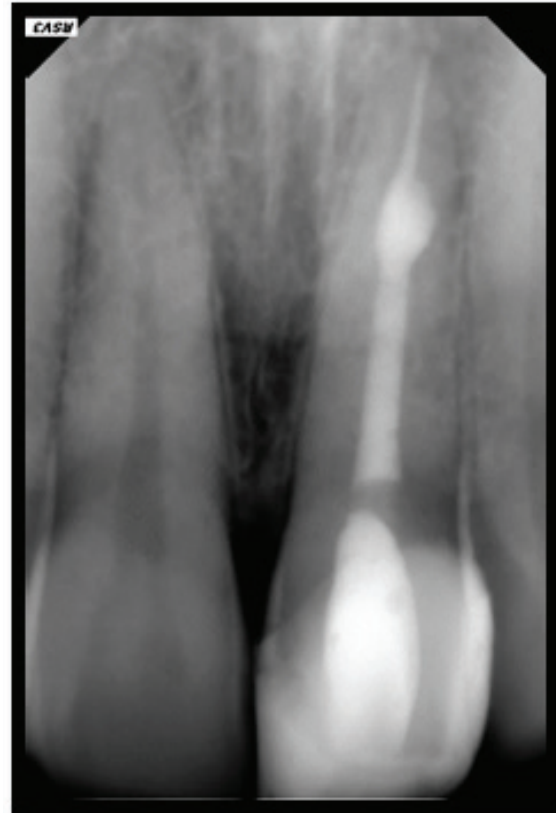
Step 5: The rest of the canal was now coated with Zinc oxide based sealer (Tubli Seal™, Kerr Endodontics)

Step 6: The tip of the elements extruder unit was brought in contact with the coronal extent of the GP in the resorption defect and was then used to backfill the canal in increments with alternate packing using the pre-selected Buchanan hand pluggers. (Fig



**Fig 5: Backfilling of the canal**

After completion of obturation, a temporary restoration (Gc Gold Label 2 Glass Ionomer Restorative Cement) was done and the patient was recalled for the final restoration after a week. Clinical examination showed asymptomatic tooth with successful periapical healing on the radiograph after 2 years.



**Fig 6: A 2-year follow up radiograph showing complete periapical healing with well obturated canal and intact permanent restoration.**

### Discussion

Internal resorption is defined as an idiopathic slow or fast progressive resorptive process occurring in the dentine of the pulp chamber or root canals of the teeth.<sup>6</sup>In the present case, calcium hydroxide intracanal medicament was preferred in order to eliminate the remaining necrotic pulp as well as the osteoclastic process. Intracanal medicaments are used as inter appointment dressings primarily to optimize the impact of the disinfection procedures.<sup>7</sup>The suppression of bacterial contamination in turn abolishes the resorptive stimulus thus favouring the repair of the defect. The role of calcium hydroxide in treating internal resorption

is to maintain hemostasis and necrotize the remaining necrotic pulp tissue thus making it more soluble to NaOCl.

Due to the complex anatomy of root canal and difficulty in accessing the internal defect, complete disinfection of the canal may be critical, therefore a combined chemo-mechanical approach along with intracanal medicament is advocated to render the canal free of bacteria.<sup>8</sup> Sodium hypochlorite and calcium hydroxide have shown to possess a synergistic effect when used in resorption defects.<sup>1</sup> Calcium hydroxide due to its antibacterial property, has shown to successfully eliminate bacteria that remain after chemo-mechanical preparation.<sup>9</sup> In this case the resorptive defect was not perforated, and thus the calcium hydroxide medicament was given for 10 days. This allowed for a thorough elimination of remaining necrotic tissue in the next visit.

The obturation of the canal along with the defect is quite challenging due to the irregularity of the lesion. Conventional obturation methods are inadequate for 3-dimensional adaptation of the obturating material into the resorptive defect. Therefore, a warm vertical compaction along with injectable thermoplasticized GP technique for back fill was chosen that allowed for acceptable filling of canal as well as the defect. A combination of two sealers was employed in this case. The use of Bioroot RCS in the apical segment enabled the single cone obturation technique and the Zinc oxide-based sealer was used for the remainder of the canal as it is more stable to heat application and exhibits no changes in properties.<sup>10</sup>

### Conclusion

Early diagnosis, removal of etiology and effective treatment planning are of utmost importance for a successful outcome of resorptive defects. In the current case, CBCT provided a detailed three dimensional view of the resorptive defect that helped in planning a conservative treatment option. Current endodontic aids such as loupes, microscopes, ultrasonics, and thermoplasticized obturation techniques with suitable endodontic sealers help in achieving three dimensional seal of the defect thus improving the prognosis of

resorptive defects.

**Ethical Clearance:** It has been obtained from the Institutional Ethical Committee, Manipal College of Dental Sciences, Mangalore, affiliated to Manipal Academy of Higher Education.

**Source of Funding:** Self

**Conflict of Interest:** Nil

### References

1. Haapasalo M, Endal U. Internal inflammatory root resorption: the unknown resorption of the tooth. *Endodontic topics*. 2006 Jul;14(1):60-79.
2. Patel S, Ricucci D, Durak C, Tay F. Internal root resorption: a review. *Journal of endodontics*. 2010 Jul 1;36(7):1107-21.
3. Rani CS, MacDougall M. Dental cells express factors that regulate bone resorption. *Molecular Cell Biology Research Communications*. 2000 Mar 1;3(3):145-52.
4. Gulabivala K, Searson LJ. Clinical diagnosis of internal resorption: an exception to the rule. *International endodontic journal*. 1995 Sep;28(5):255-60.
5. Patel S, Dawood A, Whaites E, Pitt Ford T. New dimensions in endodontic imaging: part 1. Conventional and alternative radiographic systems. *International endodontic journal*. 2009 Jun;42(6):447-62.
6. Kumar T, Mittal S, Mittal S, Sharma J. Management of trauma associated internal resorption: A case report. *Baba Farid University Dental Journal*. 2014;5(1):157-9.
7. Spångberg LS, Haapasalo M. Rationale and efficacy of root canal medicaments and root filling materials with emphasis on treatment outcome. *Endodontic Topics*. 2002 Jul;2(1):35-58.
8. Keinan D, Heling I, Stabholtz A, Moshonov J. Rapidly progressive internal root resorption: a case report. *Dental Traumatology*. 2008 Oct;24(5):546-9.
9. Sjögren U, Figdor D, Spångberg L, Sundqvist G. The antimicrobial effect of calcium hydroxide as a short-term intracanal dressing. *International endodontic journal*. 1991 May;24(3):119-25.

10. Donnermeyer D, Urban K, Bürklein S, Schäfer E. Physico-chemical investigation of endodontic sealers exposed to simulated intracanal heat application: epoxy resins and zinc oxide–eugenols. *International Endodontic Journal*. 2020 May;53(5):690-7.