

Enucleation of Scrotal Epidermoid Cyst: Case Report

Halim Perdana Kusuma¹, Nugrohoaji Dharmawan²

¹Recidency Program, ²Professor in Department of Dermatology and Venereology, Faculty of Medicine, Sebelas Maret University/ Dr. Moewardi General Hospital, Surakarta, Indonesia

Abstract

Background: Epidermoid cyst is one of the most common forms of blockage in the pilosebaceous gland. The surgical procedure for excision of the cyst aims to prevent recurrence, however, several reports suggest that enucleation can be performed with certain considerations.

Case: A 22 year old man who lives in Wonogiri, came to Dermatology and Venereology Outpatient clinic of Dr. Moewardi General Hospital Surakarta, with the chief complaint of a lump in the scrotum. The lumps appeared since 3 years ago, the size of a pea seed and accompanied by itching. The results of the examination of the dermatological status of the scrotal region showed several nodules of the skin color, felt dense and rubbery without any signs of inflammation. Histopathology shows a basket wave type parakeratosis at the stratum corneum, while the epidermal layer shows cysts filled with keratin and surrounded by squamous cells. Based on the results of the history, physical examination and histopathology, the diagnosis of the patient was a scrotal epidermoid cyst, then we performed two enucleation measures and found improvement.

Conclusion: Epidermoid cyst is a form of benign epithelial cyst that can occur in the scrotal area. The main treatment to prevent recurrences is surgery, where the enucleation technique can be performed with several considerations such as small size of the cyst without signs of inflammation, preventing dystrophic calcification and capsule routine.

Key words: enucleation, epidermoid cyst, scrotal, pilosebaceous gland, histopathology

Introduction

Epidermoid cyst or also known as epithelial cyst is one of the most common forms of blockage in the pilosebaceous gland. The clinical picture of epidermoid cysts is generally in the form of nodules

in the dermis or subepidermis layer containing keratin material with a punctum in the middle.¹ Epidermoid cysts are generally found in the head, face and back of the body, but in some cases can occur in the testes and scrotal skin.² The prevalence of scrotal epidermoid cysts worldwide is still very rare, but Kawai, et al in Japan reported that to date there have been 12 cases of scrotal epidermoid cysts.³

The pathogenesis of epidermoid cysts is still not clearly understood. Tanaka, et al stated that there are three hypotheses that underlie the mechanism of epidermoid cysts, 1) lesions arise from ectopic skin

Corresponding Author:

Dr. Halim Perdana Kusuma

Medical Faculty of SebelasMaret University, Surakarta, Indonesia/ Jl. Tentara Pelajar Komplek Cakrawala Raket 1 no.1 Malangjiwan, Colomadu, Kartosuro, Karanganyar – Central Java (Postal Code: 57177)
Email: halimkusuma120@gmail.com

tissue due to tissue dislocation to the surrounding area, 2) teratoma consisting of a single layer of germ cells and 3) due to trauma to the epidermal tissue in the dermis and subcutis layer.⁴ The diagnosis of epidermoid cyst can be made based on the results of clinical examination, histopathology and ultrasonography to rule out cutaneous calcinosis, steatocystoma or testicular malignancy.⁵

The surgical procedure in the form of excision of the cyst aims to prevent recurrence, but Heidenreich, et al stated that enucleation can be performed in cases of benign multiple scrotal epidermoid cysts based on the results of histopathological and ultrasonographic examinations.⁶ Kawai, et al also stated that scrotal epidermoid cysts that did not expand to the testes and were small in size could be enucleated by removing the cyst capsule.³ Based on this description, we report a case of scrotal epidermoid cyst that received enucleation therapy so that it can increase the insight and skills of a dermatologist in the management of scrotal epidermoid cysts.

Case

A 22-year-old man who lives in Wonogiri, came for treatment at the Dermatology and Venereology Polyclinic of the Regional General Hospital (RSUD) Dr. Moewardi Surakarta with the chief complaint of a lump in the scrotum. The results of the autoanamnesis of the history of the present disease, since 3 years ago the patient complained of a lump in the scrotum the size of a pea, the color of the skin accompanied by itching. The patient then went to a general practitioner and received topical medication (the patient forgot the name of the medicine) but the complaints were slightly reduced. Two weeks later, similar skin complaints appeared which were increasing in number and felt very itchy, so the patient decided to seek treatment at the Dermatology and Venereology Polyclinic, RSUD Dr. Moewardi Surakarta for further treatment. The results of the autoanamnesis of previous medical

history, the patient had never experienced similar skin complaints before, while based on the patient's family history of disease stated no family members had similar skin complaints.

The results of physical examination of vital signs were within normal limits, while on examination of the dermatological status of the scrotal region, several skin-colored nodules were seen measuring 0.3 cm to 0.8 cm, palpable firm and supple without any signs of inflammation in the skin of the scrotal area (**Figure 1**). Based on the results of autoanamnesis and physical examination, the differential diagnosis of this case is epidermoid cyst and scrotal calcinosis cutis.

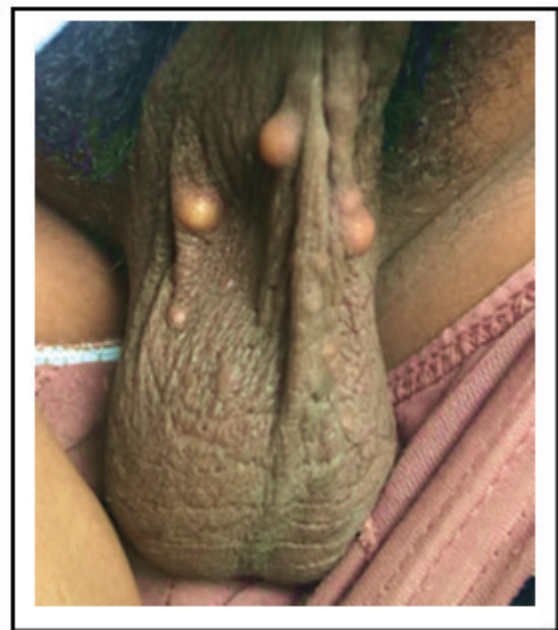


Figure 1. In the scrotal region, multiple skin-colored nodules are seen, which feel firm and firm without any signs of inflammation.

We performed histopathological examination to establish and rule out the differential diagnosis in this case. Cyst tissue from the scrotum was removed using the enucleation technique and then stained with Hematoxylin and Eosin (HE). The results of histopathological examination showed a basket wave-type parakeratosis on the stratum corneum, while in the epidermis layer there were cysts filled with keratin material

and surrounded by squamous cells (**Figure 2**). Based on the results of autoanamnesis, physical examination and histopathology, the patient's diagnosis was epidermoid kitsascrotalis.

We perform stepwise enucleation which is done once a week and twice. The steps of the enucleation procedure that we carried out were as follows (**Figure 3**):

1. Antiseptic action on the area to be enucleated using 10% povidone iodine solution by turning it outwards until it is outside the action area.
2. Perform local anesthesia by intradermal infiltration using Pehacain® solution (lidocaine 20 mg and epinephrine 0.0125 mg/ml) in 1 cc

syringe.

3. Make a 3-4 mm long incision in the skin over the cyst.
4. Insert the tip of the hemostat into the incision hole, then a blunt dissection is performed and free the cyst capsule from the surrounding tissue.
5. After being free from the surrounding tissue, the cyst capsule was enucleated with an incision using a sharp curette tip.
6. After the cyst capsule is removed, an antibiotic ointment is applied and a pressure dressing is applied using sterile gauze to prevent the formation of a hematoma.

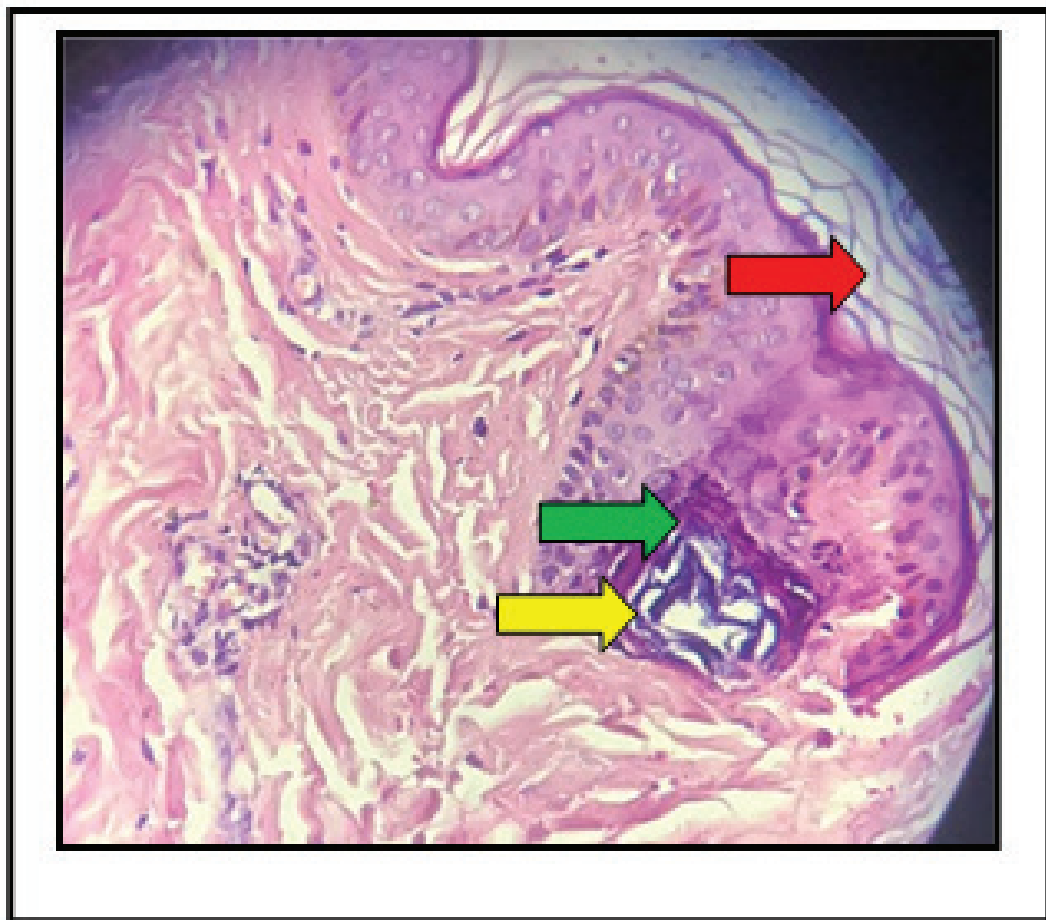


Figure 2. In the stratum corneum, basket wave-type parakeratosis appears (red arrows), while in the epidermis layer, cysts containing keratin material (yellow arrows) appear with surrounding squamous epithelium (green arrows). (HE 10x).

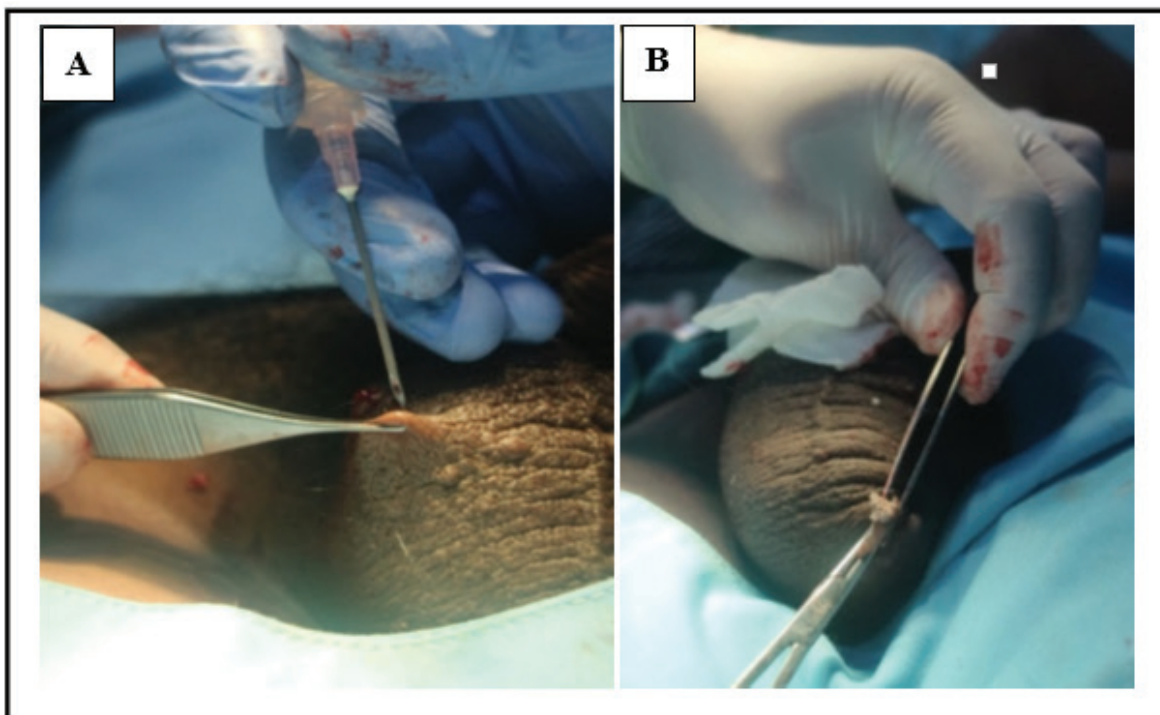


Figure 3. Enucleation procedure. (A) Local anesthetic technique (B) Enucleation of the cyst capsule.

Discussion

Epidermoid cyst is one of the most common forms of benign epithelial cysts. Most cases of lesions often occur in the head and body area, but in certain cases can be found in the scrotal area.⁷ The prevalence of scrotal epidermoid cysts is still unknown, but Trinh et al stated that the incidence is more common after puberty and is more common after puberty. found in men.⁸ Clinical manifestations of scrotal epidermoid cysts are characterized by solitary or multiple, skin-colored nodules of varying size without signs of inflammation in the skin of the scrotal area. Most cases are generally asymptomatic, but in some case reports it can be accompanied by itching.^{9,10}

In this case, the patient was a 22 year old male who complained of several lumps in the scrotum. Based on the history of the disease, the lump was initially the size of a pea, but within two weeks the lump had increased in size and was accompanied by

itching. The results of physical examination showed skin-colored nodules that were palpable and firm, and there were no signs of inflammation in the scrotal skin, so based on the results of the history and physical examination, the diagnosis of scrotal epidermoid cyst was supported.

Epidermoid cysts are the most common type of benign epithelial cysts found without the risk of developing into malignancy, so histopathological examination is needed to be sure. Histopathological features of epidermoid cysts are characterized by cysts lined by stratified epithelial cell walls resembling squamous epithelium, while the lumen contains keratin and a layer of stratum granulosum. In cysts that occur infection will show a picture of inflammatory cell infiltration around the cyst wall.^{11,12} The results of histopathological examination in this case showed a basket wave-type parakeratosis on the stratum corneum, while in the epidermis layer

there were cysts filled with keratin material and surrounded by squamous cells. The conclusion of the histopathological examination of this case supports the diagnosis of an epidermoid cyst.

The differential diagnosis of the case is scrotal calcinosis cutis, which is a benign skin disorder characterized by solitary or multiple nodules or papules which are generally asymptomatic. Nodules contain mostly calcium and phosphorus which can enlarge and expand progressively.¹³ The prevalence of the disease is still unknown, but it is often found in adolescents to adults.¹⁴ Clinical manifestations of scrotal calcinosis cutis in the form of nodules measuring 0.5-1.5 cm that are palpable solid, yellowish white and in some cases the skin of the scrotal area looks erythematous. Histopathological picture shows basophilic globules with calcium deposition in the epidermis or upper dermis layer.^{15,16} The main treatment for scrotal calcinosis cutis is elliptical surgical excision and complete excision which gives good cosmetic results.¹⁷

The results of the physical examination of the dermatological status in the scrotal area showed multiple skin-colored nodules without any signs of inflammation of the scrotal skin. The results of histopathological examination didn't reveal basophilic globules containing calcium deposition in the dermis and upper dermis, so that the differential diagnosis of scrotal calcinosis in this case could be ruled out.

Treatment of scrotal epidermoid cysts is generally complete surgical excision, but some reports suggest enucleation techniques in certain cases. Tela and Ibrahim stated that the technique of enucleation of scrotal epidermoid cysts can be performed on small lesions, whereas large lesions that spread throughout the scrotum are preferable to complete surgical excision up to scrotal reconstruction.¹⁸ Feinstein, et al stated that traumatized epidermoid cysts minor can cause dystrophic calcification or rupture, so

to prevent this, enucleation can be considered in cases of epidermoid cysts.¹⁹ Chhabra, et al stated that a modified enucleation technique in cases of epidermoid cysts can be performed for small lesions. The modified enucleation technique is performed by aspirating the contents of the cyst and then removing the capsule, which has been shown to be effective in preventing recurrence.²⁰

In this case, the epidermoid cyst was small between 0.3 cm and 0.8 cm without any signs of inflammation, so we decided to gradually enucleate it. The initial stage of enucleation is by infiltrating the skin around the treatment area using local anesthetic in the form of a Pehacain[®] solution (lidocaine 20 mg and epinephrine 0.0125 mg/ml) in a 1 cc syringe. The needle is inserted into the cyst cavity through the hair follicle hole, then the follicle orifice is gradually widened using a needle and other instruments. The cyst wall is pressed against the dilated hair follicle with the help of bent tweezers and removed using arterial clamps until the capsule is released. After the cyst capsule came out, an antibiotic ointment was applied and a pressure dressing was applied using sterile gauze.

Conclusion

Epidermoid cyst is a form of benign epithelial cyst that can occur in the scrotal area. The main treatment to prevent recurrence is surgery, where enucleation technique can be done with several considerations such as small cyst size without signs of inflammation, preventing dystrophic calcification and capsule rupture.

Acknowledgements: Nil

Ethical Clearance: This study did not use ethical clearance

Source of Funding: *Self-funding. The authors received no financial support for the research,*

authorship, and publication of this article.

Conflict of Interest Statement: Nil.

References

1. Cuda JD, Rangwala S, Taube JM. Benign epithelial tumors, hamartomas, and hyperplasias. Dalam: Kang S, Amagi M, Bruckner AL, Enk AH, Margolis DJ, McMichael AJ, dkk (editor). Fitzpatrick's dermatology in general medicine. Edisi ke-9. Amerika Serikat: Mc Graw Hill. 2019. h: 1799-819.
2. Yang WT, Whitman GJ, Tse GM. Extratesticular epidermal cyst of the scrotum. *Am J Roentgenol*. 2004; 183(4): 1084.
3. Kawai N, Sakagami H, Awata S, Kojima Y, Tatsura H, Sasaki S. Epidermoid cyst of the scortum; A case report. *Acta Urol Jpn*. 1996; 42(8): 609-11.
4. Tanaka T, Yasumoto R, Kawano M. Epidermoid cyst arising from the spermatic cord area. *Int J Urol*. 2000;7(7):277-9.
5. Yamamoto S, Maekawa T, Kumata N, Nishisaka N, Wada S, Yasumoto R, dkk. Giant epidermoid cyst of the scrotum: A case report. *Acta Urol Jpn*. 1992; 38(11): 1273-76.
6. Heidenreich A, Zumbel J, Vorreuther R, Klotz T, Vietsch H, Engelmann UH. Testicular epidermoid cyst: Orchiectomy or enucleation resection?. *Der Urologe Ausg A*. 1996; 35(1): 1-5.
7. Jham BC, Duraes GV, Jham AC, Santos CR. Epidermoid cyst of the floor of the mouth: A case report. *J Can Dent Assoc*. 2007; 73(6): 525-28.
8. Trinh CT, Nguyen CH, Chansomphou V, Tran TTT. Overview of epidermoid cyst. *Eur J Radiol Open*. 2019; 6: 291-301.
9. Dutta M, Saha J, Biswas G, Chattopadhyay S, Sen I, Sinha R. Epidermoid cysts in head and neck: Our experiences, with review of literature. *Indian J Otolaryngol Head Neck Surg*. 2013; 65(1): 14-21.
10. Wollina U, Langner D, Tchernev G, França K, Lotti T. Epidermoid cysts □ a wide spectrum of clinical presentation and successful treatment by surgery: A retrospective 10-year analysis and literature review. *Open Access Maced J Med Sci*. 2018; 6(1): 28-30.
11. Zabkowski T, Wajszczuk M. Epidermoid cyst of the scrotum: a clinical case. *Urol J*. 2014; 11(3): 1706-9.
12. Dambro TJ, Stewart RR, Carroll BA. The scrotum. Dalam: Rumack CM, Wilson SR, Charboneau JW (editor). *Diagnostic ultrasound*. Edisi ke-2. St Louis, MO: Mosby. 1997. h: 791-821.
13. Kumar D, Singhal P, Kumar A, Rajakumar R. (2020). Idiopathic scrotal calcinosis-a case series. *Int J Surg*. 2020; 4(2): 4-6.
14. Özgenel GY, Kahveci R, Filiz G. Idiopathic scrotal calcinosis. *Ann Plast Surg*. 2002;48:453-4.
15. Panhotra S, Hassan MJ, Sehgal S, Khan S, Jetley S. Idiopathic scrotal calcinosis: A brief case report. *Urol Case Rep*. 2020; 4(4): 352-54.
16. Róbert L, Kiss N, Medvecz M, Kuroli E, Sárdy M, Hidvégi B. Epidemiology and treatment of calcinosis cutis: 13 years of experience. *Indian Dermatol J*. 2020; 65(2): 105.
17. Kilitci A, Kaya Z, Acar EM, Elmas ÖF. Scrotal calcinosis: Analysis of 5 cases. *J Clin Exper Invest*. 2018; 9(4): 150-53.
18. Tela UM, Ibrahim MB. Scrotal calcinosis: A case report and review of pathogenesis and surgical management. *Urol Case Rep*. 2012; 6: 1-3.
19. Feinstein A, Kahana M, Levy A. Idiopathic scrotal calcinosis and vitiligo of the scrotum. *J Am Acad Dermatol*. 1984; 11: 519-20.
20. Chhabra N, Chhabra S, Kumar A. Cyst enucleation revisited: A new technical modification to ensure complete removal of cystic lining. *J Maxillofac Oral Surg*. 2020; 19(2): 173-77.