

## Cross-Sectional Study of Sexual Dimorphism in Lip Prints among Students Doing a Professional Course in Bengaluru

Chethan Krishna<sup>1</sup>, Geetha KB<sup>2</sup>, Ipsita Debata<sup>3</sup>, TEJAS. J<sup>4</sup>

<sup>1</sup>Student, Final Year MBBS, Akash Institute of Medical Sciences & Research Centre, Prasannahalli Road, Devanahalli Near Kempegowda International Airport, Bengaluru - 562110, <sup>2</sup>Associate Professor, Dept. of Forensic Medicine, Dr. Chandramma Dayanand Sagar institute of Medical education and Research, Devarakaggalahalli, Kanakapura Taluq, Harohalli Hobli, Ramanagar district - 562 112, <sup>3</sup>Associate Professor, Dept. of Community Medicine, Akash Institute of Medical Sciences & Research Centre, Prasannahalli Road, Devanahalli Near Kempegowda International Airport, Bengaluru - 562110, <sup>4</sup>Associate Professor, Dept. of Forensic Medicine, Karpaga Vinayaga Institute of Medical Sciences, Gst Road, Chinna, Kolambakkam, Palayanoor (Po), Madhuranthagam(Tk), Chengalpattu (Dt), Tamil Nadu - 603 308

**How to cite this article:** Chethan Krishna, Geetha KB, Ipsita Debata. Cross-Sectional Study of Sexual Dimorphism in Lip Prints among Students Doing a Professional Course in Bengaluru. Indian Journal of Forensic Medicine and Toxicology 2022;16(4).

### Abstract

**Background:** Identification of human beings forms the basis of any criminal investigation. Lip print study, also known as cheiloscropy is the study of patterns formed by the ridges and grooves on the external surface of lips. This study aims to classify lip prints and study its correlation to sex.

**Methodology:** 205 student participants who volunteered were included in this study of which females were 123 and males were 82. A food safe pigment was applied to the lips. Over this pigment, the glued portion of the cellophane tape strip was placed and the subject was asked to make a lip impression in the normal rest position of the lips by dabbing it in the centre first and then pressing it uniformly toward the corners of the lips. The cellophane strip was then stuck to the white chart paper for permanent record purpose, then visualized by magnifying lens and analysed quadrant wise.

**Conclusion** The most common lip print in the upper lip was found to be type 3 and in the lower lip was found to be type 4. Statistically significant difference with respect to sex was observed in first quadrant only ( $p = 0.01$ ) and not in others.

**Keyword:** Cheiloscropy, Lip prints.

### Introduction

Identification of human beings forms the basis of any criminal investigation. Lip print study, also

known as cheiloscropy is the study of patterns formed by the ridges and grooves on the external surface of lips<sup>1</sup>. It has gained importance as a prominent

**Corresponding Author:** TEJAS. J, Associate Professor, Dept. of Forensic Medicine, Karpaga Vinayaga Institute of Medical Sciences, Gst Road, Chinna Kolambakkam, Palayanoor (Po), Madhuranthagam(Tk), Chengalpattu (Dt), Tamil Nadu - 603308.

**E-mail:** tejas05in@gmail.com

**Mobile:** 9731522968

identification tool in the past few decades<sup>2</sup>. It also plays a vital role in criminal investigations involving murder, rape and other sexual offences where in lip print may be the only evidence left behind by the suspect. Lip prints may also be used as a biometric modality which when combined with other techniques may further enhances the accuracy of identification.

### Review of Literature

Fischer in 1902 was the first anthropologist to describe the furrows on the red part of human lips<sup>3</sup>. In 1950, Synder reported in his book "Homicide Investigation" that the characteristics of the lips formed by lip grooves are as individually distinctive as the ridge characteristics of finger prints<sup>4</sup>. Suzuki, in 1967, made detailed investigations of the measurement of the lips, the use and color of rouge, and the method for its extraction to obtain useful data for practical forensic application<sup>5</sup>. Mc Donnell in 1972 conducted a study on lip prints between two identical twins and reported that two identical twins seemed to be indistinguishable by every other means but their lip prints were different<sup>6</sup>. This tool has the ability to differentiate sex in the field which could be of value when the other modalities of identification may not be applicable. Lip prints are found to be more sensitive than palatoscopy or canine odontology<sup>2</sup>. Lip prints have also been used as a potential biomarker for Type 2 diabetes mellitus<sup>7</sup>.

Although this study has been around for decades, it has only been used in isolated cases in the court of law and its uniqueness and interpretation requires further research. The present study is aimed at identifying lip prints of different individuals in different parts of the lip and find out the incidence of any particular pattern in the given sex.

### Aims and Objectives

1. To classify Lip Prints of the study group using classification scheme proposed by Suzuki and Tsuchihashi<sup>8</sup>.
2. Correlation of lip print classification with the sex of the individual.

### Materials and Methods

- **Ethical approval:** Institutional ethical clearance was obtained from the teaching institute before commencing the study.
- **Study area:** The study was conducted among students doing a professional course in a tertiary care center located in Bengaluru.
- **Study sample:**  
205 student participants who volunteered were included in this study of which females were 123 and males were 82.
- **Study materials:**
  1. Pigment which is food safe.
  2. Cellophane tape.
  3. White chart paper.
  4. Magnifying lens.
- **Inclusion criteria:** Students between 19 yrs to 24 yrs of age were included in this study. Only those students with normal lips without any pathology and a normal transition between the mucosa and the skin were included.
- **Consent:** Individual written consent was obtained before the study was conducted on the subject.
- **Technique:**

The lips of the individuals were cleaned and a pigment which is food safe was applied on the lips. Over this pigment, the glued portion of the cellophane tape strip was placed and the subject was asked to make a lip impression in the normal rest position of the lips by dabbing it in the centre first and then pressing it uniformly toward the corners of the lips. The cellophane strip was then stuck to the white chart paper for permanent record purpose and then visualized by magnifying lens. While studying the various types of lip prints, each individual's lip was divided into four compartments, i.e., two compartments on each lip, and was allotted the digits 1-4 in a clock-wise sequence starting from the subject's upper right quadrant thereby dividing both the lips into 4 equal quadrants named as q1, q2,

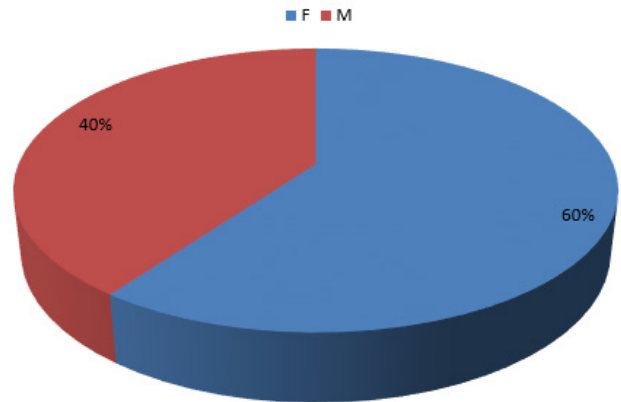
q3 and q4. Lip print in each quadrant was classified using the Suzuki and Tsuchihashi<sup>8</sup>. The classification is as follows:

- **Type I** - Clear-cut grooves running vertically across the lip
- **Type I'** - The grooves are straight vertical but discontinuous, not running entirely across the lip.
- **Type II** - The grooves branch in their course in the shape of Y
- **Type III** - Intersecting grooves
- **Type IV** - Reticular pattern
- **Type V** - The grooves do not fall into any of the types I-IV, and cannot be differentiated morphologically and are irregular.
- **Data analysis:** Data was tabulated, analyzed using SPSS software and interpreted with appropriate statistical parameters.

**Observation and Results**

All the lip prints analysed showed different patterns and also inter-quadrant variation. The most common lip print in q1 was type 3 (31.2%); q2 was

type 3 (33.2%); q3 was type 4 (31.7%); q4 was type 4 (26.4%). Hence, the most common lip print in the upper lip was found to be type 3 and in the lower lip was found to be type 4. On performing Pearson Chi-Square test for gender correlation in each quadrant, statistical significance was observed in q1 (p = 0.010) whereas no statistical significance was found in any of the other quadrants (q2 p= 0.130; q3 p= 0.163 & q4 p= 0.428).



**Fig 1: Study Group**

Distribution of study group according to gender

**Table 1: Frequency (%) of different lip print type in different Quadrants (most common highlighted in bold)**

Lip print type	Quadrant 1 (%)	Quadrant 2 (%)	Quadrant 3 (%)	Quadrant 4 (%)
1'	20.5	6.8	24.9	21
1	13.7	21.5	15.6	18
2	8.3	10.7	10.2	8.8
3	<b>31.2</b>	<b>33.2</b>	12.7	23.4
4	18	14.6	31.7	26.3
5	8.3	13.2	4.9	2.4

**Table 2: Correlation between lip print in Quadrant 1 and gender**

Quadrant 1: Chi-Square Tests			
	Value	df	P value
Pearson Chi-Square	15.034(a)	5	0.01

**Table 3: Correlation between lip print in Quadrant 2 and gender**

Quadrant 2: Chi-Square Tests			
	Value	df	P value
Pearson Chi-Square	8.517(a)	5	0.13

**Table 4: Correlation between lip print in Quadrant 3 and gender**

Quadrant 3: Chi-Square Tests			
	Value	df	P value
Pearson Chi-Square	7.876(a)	5	0.163

**Table 5: Correlation between lip print in Quadrant 4 and gender**

Quadrant 4: Chi-Square Tests			
	Value	df	P value
Pearson Chi-Square	4.900(a)	5	0.428

### Discussion

As substantiated by our results and earlier studies, there exists a significant difference in lip prints from person to person and within the same person, which makes Cheiloscopy an important tool for identification. In our study we have found that the most common type of lip print in the upper lip was type 3 (31.2% and 33.2%) and in the lower lip was type 4 (31.7% and 26.4%) with overall most common type of lip print to be of type 3(64.4%) variety. This same pattern was also observed individually in the male and female sub-groups as found in study by Kiran et. al.<sup>9</sup>. But this is in contrary to the studies by Gondivkar et. al.<sup>10</sup> social and legal reasons. The study of lip-prints (cheiloscopy, & Patel et. al.<sup>11</sup> who found that type 2 pattern was most common among females and Tandon et. al.<sup>12</sup> who found type 1 pattern to be most common in females . P Manjusha et. al.<sup>7</sup> found that Type IV pattern of lip prints was significantly more in the diabetic patients. Basheer et. al.<sup>13</sup> observed that most common lip print pattern in North Kerala population was type 1 and with type 2 being common in males and type 4 in females. Sexual dimorphism was observed with significant difference only in quadrant 1 in our study in which the most common type of lip print was type 3, which is in acceptance with studies by P Manjusha et. al.<sup>7</sup>, Prabhakar et. al.<sup>14</sup> and Gondivkar et. al.<sup>10</sup> social and legal reasons. The study of lip-prints (cheiloscopy. Whereas Kautilya et. al.<sup>15</sup> observed that the outer four portions of the lip showed statistically significant differences in males and females . In contrast, studies by Patel et. al.<sup>11</sup> and Basheer et. al.<sup>13</sup> found no significant difference in lip prints of male and female.

### Conclusion

This study concludes that type 3 lip print is most common among the study population with sexual dimorphism being exhibited only in the first quadrant. But this requires further validation as there is lack of consensus with studies published so far. Also, since lip prints show greater geographic and racial variation future studies in these areas

may throw further light. The value of lip prints as a powerful identification tool is reiterated by this study and its use especially in medico-legal work cannot be over stressed.

### Summary

205 student participants who volunteered were included in this study of which females were 123 and males were 82; all between the age groups of 19 to 24 years. Lip prints were developed using a food safe pigment and a cellophane tape which was then stuck to a paper. The lip prints were divided into 4 quadrants (q1, q2, q3 & q4) in clockwise direction starting from left upper quadrant and analysed for statistical significance. The most common lip print in q1 was type 3 (31.2%); q2 was type 3 (33.2%); q3 was type 4 (31.7%); q4 was type 4 (26.4%). Hence, the most common lip print in the upper lip was found to be type 3 and in the lower lip was found to be type 4. On performing Pearson Chi-Square test for gender correlation in each quadrant, statistical significance was observed in q1 (p = 0.010) whereas no statistical significance was found in any of the other quadrants (q2 p= 0.130; q3 p= 0.163 & q4 p= 0.428). This study concludes that type 3 lip print is most common among the study population with sexual dimorphism being exhibited only in the first quadrant.

**Ethical clearance:** Taken from Institutional Ethics Committee of Akash Institute of Medical Sciences and Research Centre, Bengaluru

**Source of funding:** Indian Council of Medical Research

**Conflict of Interest:** Nil

### References

1. Dineshshankar J, Ganapathi N, Yoithapprahunath TR, Maheswaran T, Kumar MS, Aravindhnan R. Lip prints: Role in forensic odontology. J Pharm Bioallied Sci. 2013 Jun;5(Suppl 1):S95-97.
2. V N, Ugrappa S, M NJ, Ch L, Maloth KN, Kodangal S. Cheiloscopy, Palatoscopy and Odontometrics in Sex Prediction and Dis-crimination - a Comparative Study. Open Dent J. 2015 Jan 6;8(1):269-79.
3. Kasprzak J. Possibilities of cheiloscopy. Forensic Sci Int. 1990 May;46(1-2):145-51.

4. Synder L. Textbook of Homocide investigation. Identification of dead bodies. In 1950. p. 65.
5. Suzuki K, Suzuki H, Tsuchihashi Y. On the female lips and rouge. *Jpn J Leg Med.* 1967;67(471).
6. Mishra G, Ranganathan K, Saraswathi T. Study of lip prints. *J Forensic Dent Sci.* 2009;1(1):28.
7. Manjusha P, Sudha S, Shameena P, Chandni R, Varma S, Pandiar D. Analysis of lip print and fingerprint patterns in patients with type II diabetes mellitus. *J Oral Maxillofac Pathol.* 2017;21(2):309.
8. Suzuki K, Tsuchihashi Y. New attempt of personal identification by means of lip print. *J Indian Dent Assoc.* 1970 Jan;42(1):8-9.
9. Kiran A P, Sharma SM, Sridevi D, Alonza AM, R M. Personal Identification using Cheiloscopy in South India. *J Forensic Res [Internet].* 2016 [cited 2019 Jan 24];7(4). Available from: <https://www.omicsonline.org/open-access/personal-identification-using-cheiloscopy-in-south-india-2157-7145-1000334.php?aid=77937>.
10. Gondivkar SM, Indurkar A, Degwekar S, Bhowate R. Cheiloscopy for sex determination. *J Forensic Dent Sci.* 2009 Jul 1;1(2):56.
11. Patel S, Paul I, Astekar MS, Ramesh G, V SG. A study of lip prints in relation to gender, family and blood group. *Int J Oral Maxillofac Pathol.* 2010 Dec 29;1(1):4-7-7.
12. Tandon A, Srivastava A, Jaiswal R, Patidar M, Khare A. Estimation of gender using cheiloscopy and dermatoglyphics. *Natl J Maxillofac Surg.* 2017;8(2):102.
13. Basheer S, Gopinath D, Shameena PM, Sudha S, Lakshmi JD, Litha. Correlation of lip patterns, gender, and blood group in North Kerala population: A study of over 800 individuals. *J Forensic Dent Sci.* 2017 Aug;9(2):73-7.
14. Jeergal P, Pandit S, Desai D, Surekha R, Jeergal V. Morphological patterns of lip prints in Mangaloreans based on Suzuki and Tsuchihashi classification. *J Oral Maxillofac Pathol.* 2016;20(2):320.
15. Kautilya D. V. Efficacy of Cheiloscopy in Determination of Sex Among South Indians. *J Clin Diagn Res [Internet].* 2013 [cited 2019 Jan 23]; Available from: [http://www.jcdr.net/article\\_fulltext.asp?issn=0973-709x&year=2013&volume=7&issue=10&page=2193&issn=0973-709x&id=3468](http://www.jcdr.net/article_fulltext.asp?issn=0973-709x&year=2013&volume=7&issue=10&page=2193&issn=0973-709x&id=3468).