

## Gastric Perforation Due to Yellow Oleander Poisoning: First Case Report in Humans

Furqan Mohammed Ahmed<sup>1</sup>, Sudharsanan Sundaramurthi<sup>2</sup>,  
Sudharshan Mahalingam<sup>3</sup>, Dandugula Pavan Kumar<sup>4</sup>

<sup>1</sup>Junior Resident, <sup>2</sup>Associate Professor, <sup>3</sup>Senior Resident, <sup>4</sup>Junior Resident, Department of General Surgery, Jawaharlal Institute of Postgraduate Medical Education and Research (JIPMER), Dhanvantari Nagar, Puducherry.

**How to cite this article:** Furqan Mohammed Ahmed, Sudharsanan Sundaramurthi, Sudharshan Mahalingam et. al. Gastric Perforation Due to Yellow Oleander Poisoning: First Case Report in Humans. Indian Journal of Forensic Medicine and Toxicology 2023;17(3).

### Abstract

Yellow oleander (*Thevetia peruviana*) is a commonly found shrub in India which produces multiple alkaloids which are cardiotoxic. Numerous cases of yellow oleander poisoning have been reported in humans. The spectrum of toxicity due to this plant ranges from nausea, vomiting, diarrhoea, electrolyte abnormalities and arrhythmias in humans. No case of bowel necrosis due to yellow oleander has been reported in humans to the best of our knowledge.

We present a case of 45-year-old female with suicidal consumption of crushed yellow oleander seeds. The patient was admitted and observed for arrhythmias. On day 2 of admission, she developed bloody stools, hematemesis and abdominal pain. Abdominal examination showed rigidity and per rectal examination showed blood-stained mucoid stools. A CECT was done which showed findings suggestive of gastric necrosis with perforation. The patient was taken up for surgery and stomach was found to be gangrenous with a perforation at the greater curvature. Total gastrectomy was performed. The post operative biopsy showed extensive transmural coagulative necrosis of the stomach and lymphoplasmacytic infiltration of the submucosa.

Necrosis of bowel has been reported in experimental settings in animals and in cattle poisoning but no reported case of stomach necrosis and perforation due to yellow oleander has been reported in humans. As yellow oleander is a commonly used suicidal poison in Southern Asia, an eye needs to be kept out for gastrointestinal symptoms. We conclude with recommendations on management of yellow oleander poisoning in the light of these new manifestations.

**Keywords:** Gastrectomy, Gastric Necrosis, Perforation Peritonitis, Poisoning, *Thevetia peruviana*, Total gastrectomy, Yellow oleander.

### Introduction

Yellow oleander (*Thevetia peruviana*) is a garden plant which is ubiquitous in its distribution.

It is an ornamental shrub belonging to the family Apocynaceae, also called the dogbane family, alluding to its toxic nature to dogs and other

---

**Corresponding Author:** Furqan Mohammed Ahmed, Junior Resident, Department of General Surgery, Jawaharlal Institute of Postgraduate Medical Education and Research (JIPMER), Dhanvantari Nagar, Puducherry.

**E-mail:** furqan.hyderabad@gmail.com

**Mobile:** +91 8008165975

---

animals.<sup>1</sup> All parts of the plant are poisonous with the kernels containing the highest concentration of toxins.<sup>2</sup> The toxins are cardiac glycosides similar to digoxin. The toxins described are thevetin B, cerberin, nerifolin, thevetin A, ruvoside and peruvoside in the increasing order of toxicity. The mechanism of action of toxicity is by inhibition of sodium-potassium ATPase pump in cardiomyocytes resulting in a variety of arrhythmias, myocardial depression and even myocardial infarction.<sup>1-7</sup>

The other systems affected include the gastrointestinal tract with the most common symptom being nausea and vomiting. Diarrhoea, abdominal pain, numbness of mouth and tongue are other common symptoms. Neurological manifestations include lethargy, dizziness, ataxia and tremors. Jaundice and renal failure have also been reported.<sup>3-5</sup> Its cardiac glycosides were implemented in treatment of heart failure and atrial fibrillation. However, its use and research as a medicinal agent has widely been discontinued due to its high toxicity.<sup>1,6</sup>

Yellow Oleander is a common culprit in accidental and intentional poisoning in humans and in cattle. In cattle it has been documented to cause active inflammation of the mucosa and lymphoplasmacytic infiltration leading to bloody and mucoid diarrhoea and haemorrhagic stools. It is suggested that these effects are due to direct contact of the toxin with the mucosa rather than due to systemic effects.<sup>7</sup> This local corrosive like action of yellow oleander has never been reported in humans to the best of our knowledge. Only one case of corrosive injury to the oral cavity has been reported due to ingestion of common oleander (*Nerium oleander*) leaf in a 36 year old male.<sup>8</sup>

Here we present a case of 45-year-old female with suicidal consumption of yellow oleander seeds presenting with delayed gastric necrosis and perforation. This article brings to light the corrosive effects of yellow oleander on the gastrointestinal tract which can lead to life threatening complications such as hematemesis, bloody diarrhoea, mucosal necrosis and even perforation.

### Case Summary


A 45-year-old lady, gardener by profession,

presented to the emergency department with alleged history of consumption of six crushed seeds of yellow oleander with suicidal intention. (Fig.1) She complained of dizziness, burning sensation in the throat and upper abdomen with nausea and multiple episodes of vomiting. On examination she had a pulse of 110 beats per minute and a blood pressure of 110/60 mm of Hg. She had features of dehydration and fluid resuscitation was started. Systemic examination showed a regular heart beat with tachycardia and respiratory system examination was unremarkable. She had upper abdominal tenderness with no guarding. Urine output was low and high coloured.

Her blood investigations showed deranged renal parameters (Urea-144mg/dl, Creatinine-3.7mg/dl) with hyperkalaemia ( $K^+$ -5.9mmol/L). Her ECG showed sinus tachycardia with no arrhythmias. Gastric lavage was not done as the patient presented 8 hours after consumption of the seeds. She was managed conservatively with adequate fluid resuscitation and continuous cardiac monitoring following which her urine output and renal parameters started to improve. However, she had persistent vomiting with upper abdominal pain despite proton pump inhibitors and antiemetic. On the third day of admission, she had an episode of hematemesis and bloody mucoid diarrhoea following which her vitals were deteriorating with hypotension and worsening tachycardia. On examination she had diffuse guarding of the abdomen and mucoid bloody stools on per rectal examination.

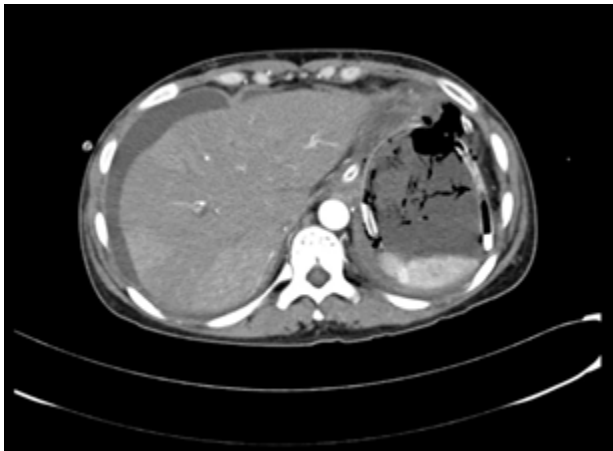


Fig. 1- Kernels of Yellow Oleander

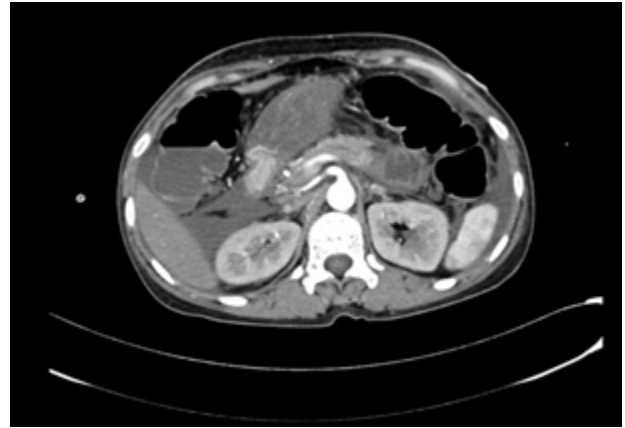


**Fig. 2: Flower of yellow oleander**

A contrast enhanced CT scan of the abdomen was done which showed diffuse submucosal oedematous wall thickening of the stomach with poor mucosal contrast enhancement up to the antro-pyloric region. Non enhancement of mucosa at the fundal region with adjacent collection showing air pockets in the left sub diaphragmatic region, suggestive of gastric mucosal necrosis with perforation at the fundus. Rest of the bowel showed normal mucosal enhancement. (Fig.3-4)

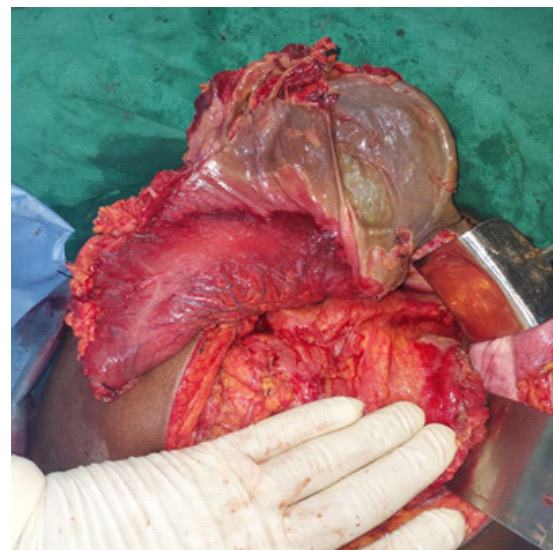


**Fig. 3: Ryle's tube seen in the stomach with poor mucosal contrast enhancement and air foci seen outside the stomach**

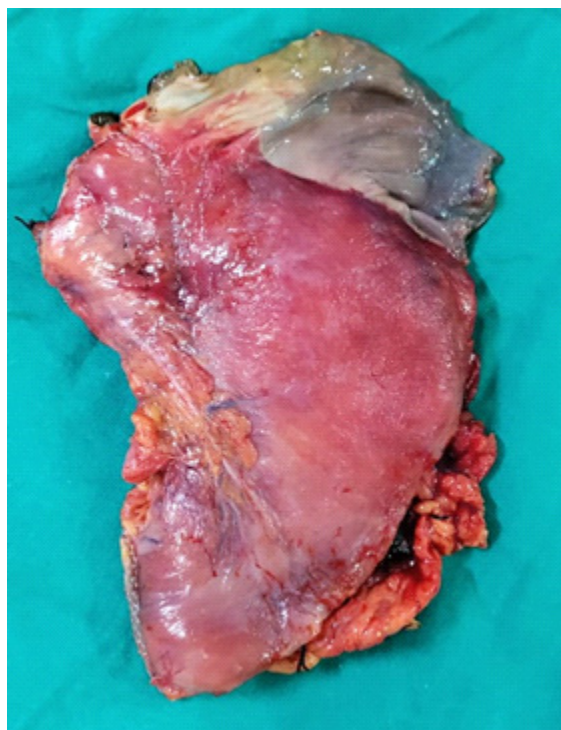


**Fig. 4: Non enhancing stomach with adjacent normal enhancement of the duodenum**

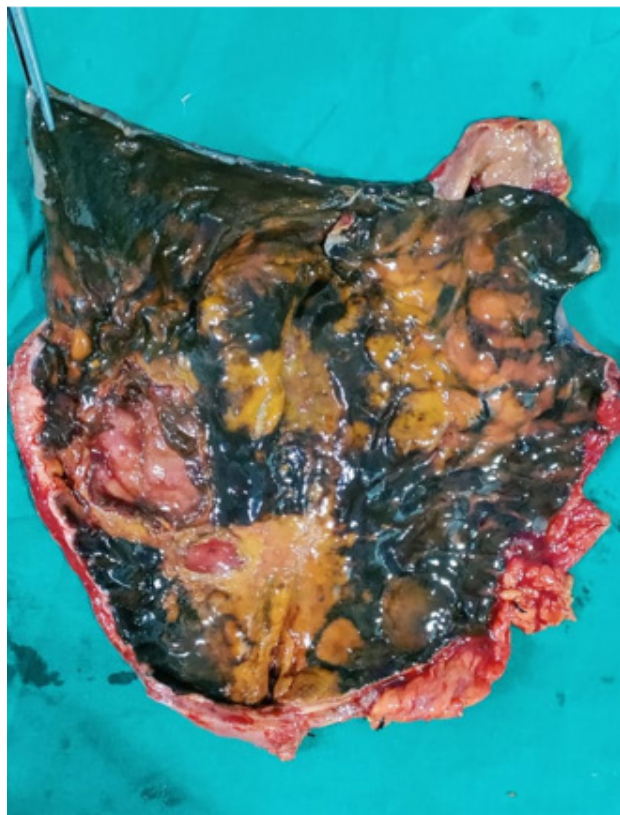
The patient was taken up for emergency exploratory laparotomy with ongoing resuscitation. Intraoperatively one liter of purulent contamination was noted. Fundus, greater curvature and proximal body of stomach was found gangrenous with a rent at the fundus of the stomach. Gastroesophageal junction and proximal cardia were spared. As the stomach was gangrenous total gastrectomy was done. Owing to her hemodynamic instability decision was taken not to proceed with reconstruction at the same sitting. The duodenal stump was closed with distal feeding access achieved by a feeding jejunostomy and a proximal venting cervical oesophagostomy. The patient was shifted to the surgical ICU for post-operative monitoring. (Fig.5-7)



**Fig. 5: Intra-operative picture of posterior wall of stomach showing transmurial necrosis in the fundus and greater curvature**



**Fig. 6: Resected specimen of the stomach showing transverse necrosis of the fundus of the stomach**



**Fig. 7: Resected specimen opened showing the necrosed mucosal of the stomach similar to that seen in corrosive poisoning**

Her immediate postoperative period was uneventful. Her cervical oesophagostomy drained 400-500ml saliva per day. On post-operative day 2 her abdominal drain had bilious output. Her ultrasound abdomen revealed no intra-abdominal collection. Since she was hemodynamically stable and had no other symptoms and signs of peritonitis, she was managed conservatively. The bilious output came down gradually following which the drain was removed once the output was negligible.

The post-operative biopsy showed extensive transmural coagulative necrosis of the stomach and lymphoplasmacytic infiltration of the submucosa. The proximal resected end was viable whereas the distal resected end was showing necrosis which could be the probable cause of the bile leak. She was discharged with the plan of endoscopic evaluation and reconstructive procedure after nutritional and psychiatric rehabilitation.

### Discussion

Yellow oleander poisoning is a common occurrence in the Indian subcontinent. Its toxicity has been known since ancient times; in India the shrub was called Kajamaraka- the Herb that makes the horse die.<sup>7</sup> All parts of the plant are poisonous with the kernels containing the highest concentration of toxins.<sup>2</sup>

The toxins described are thevetin B, cerberin, nerifolin, thevetin A, ruvoside and peruvoside in the increasing order of toxicity. These toxins act by inhibiting the sodium-potassium ATPase pump in cardiomyocytes which increases the intracellular sodium concentration. This in turn leads to the increase in intracellular calcium level resulting in increase in the resting membrane potential, increased excitability and automaticity of the myocardial cells. Also, potassium gets pushed in the extra cellular compartment leading to hyperkalaemia. All these factors are responsible for the predominant cardiac toxicity of yellow oleander which include bradycardia with atrioventricular block, atrial tachycardia, ventricular tachycardia, ventricular fibrillation, cardiogenic shock, myocardial depression and even myocardial infarction.<sup>1,7,9-12</sup>

Management of yellow oleander poisoning is primarily aimed at correcting the electrolyte

abnormalities and preventing cardiac complications.<sup>1</sup> Arrhythmias are the major cause of mortality in oleander poisoning,<sup>3</sup> which belongs to the Apocyanaceae family, is a common shrub seen throughout the tropics. All parts of the plant contain high concentrations of cardiac glycosides which are toxic to cardiac muscle and the autonomic nervous system. Here, we describe the clinical profile of patients with oleander poisoning and their outcomes.

**Methods and Materials:** This retrospective study was conducted over a period of 12 months (March 2016 to February 2017). Most cases are usually admitted for cardiac monitoring and resuscitation. Some cases respond to treatment with digoxin specific Fab antibody fragments and atropine.<sup>1</sup> Though most cases present with nausea and vomiting the gastrointestinal manifestation of oleander are usually overlooked. This case brings to light the potentially fatal gastrointestinal manifestation of oleander poisoning.

Severe gastrointestinal symptoms including bloody diarrhoea, mucosal necrosis and corrosive like effects on oesophagus and stomach have been previously reported in cattle and rats.<sup>7,13</sup> Histologically this has been described as necrosis with lymphoplasmacytic infiltrate similar to that seen in corrosive injury. The predominant effect is seen in oesophagus and stomach. Small intestine is relatively spared due to the sphincter action of pylorus. Similar corrosive like action has also been described on the skin due to local application leading to erythema and blisters. It is believed that the gastrointestinal manifestations are due to local corrosive effect rather than systemic toxicity.<sup>7</sup> A similar case of oral mucosal inflammation and necrosis has been reported due to the corrosive effect of common oleander.<sup>8</sup> Both yellow oleander and common oleander have been reported in cases of poisoning but yellow oleander has been implicated far more frequently. It is still not clear if the two plants cause significantly different types of poisoning and as per current literature are treated as a single entity.<sup>1</sup>

This is the first report of the corrosive action of yellow oleander on the gastrointestinal tract of humans. It highlights the importance of thorough and prompt abdominal examination in cases of yellow oleander poisoning. The need for observation

especially in patients with worrisome symptoms like persistent and severe abdominal pain, hematemesis and bloody diarrhoea. The observation needs to be continued for 3 to 5 days as in both the reported cases necrosis evolved after two days.

In light of this case, we recommend treating cases of oleander poisoning with persistent gastrointestinal symptoms such as persistent abdominal pain, burning sensation in the throat, hematemesis, bloody diarrhoea similar to other corrosive poisonings. Such patients need continuous monitoring for development of abdominal signs. Contrast enhanced CT scan can be used to look for necrosis and perforation when clinically suspected. Close watch for respiratory distress should be kept and prompt intubation or tracheostomy should be done when indicated.<sup>8</sup> In conclusion the corrosive effects of oleander should not be overlooked as it can lead to catastrophic gastrointestinal complications ranging from mucosal necrosis to perforation peritonitis.

#### **Recommendations based on our experience:**

All cases of yellow oleander poisoning should be evaluated by the surgical team at admission and at regular intervals in the presence of gastrointestinal symptoms. We recommend treating yellow oleander poisoning from the surgical side as a corrosive poisoning alongside the usual medical treatment. Emetics should be discouraged as they increase the contact of the toxins with the oesophagus. Gastric lavage should not be done as Ryle's tube placement can lead to perforation. Initial resuscitation with fluids should be done taking into account the cardiac status which is affected due to the cardiac glycosides. The patients should be started on proton pump inhibitors. Abdominal examination should be repeated on frequent intervals to look for development of peritoneal signs. The patient should be kept nil per oral and observed for worrisome features like persistent abdominal pain refractory to medication, persistent vomiting, hematemesis, melena, bloody mucoid stools and abdominal guarding or rigidity. Increased pulse rate, hypotension, fever, increasing abdominal girth, increasing white blood cell counts and increasing lactate can be helpful adjuncts in monitoring the patients. Orals can be started if there are no such signs or symptoms after the initial observation period. It is worthy to note here that the

overt necrosis in this case and the one reported by Taskin O. developed after three to four days. Hence, patients with worrisome symptoms may require an extended period of observation. Swift action should be taken if there is any suspicion of necrosis or perforation. X-ray can pick up overt perforation but contrast enhanced CT should be preferred as will help diagnose mucosal necrosis, concealed perforations and demarcate the level of perforation. Necrosis or perforation if present should be tackled surgically on a case-to-case basis. It is important to remember that the CT findings and the intraoperative visualization of the bowel from the external surface doesn't give us a complete picture of the viability of the internal mucosa. The apparently normal looking bowel after resecting the necrosed or perforated part might still not be healthy enough to perform an anastomosis. Examining the mucosa by opening up the staple line when staplers are used is recommended. Revision of the level of resection can be done if there is a doubt regarding the viability. Post operatively a close watch should be kept for leaks.

As this is the first reported case of gastric necrosis and perforation due to yellow oleander poisoning the above recommendations are based on a single experience. Further case reports and studies need to be done to establish the incidence of such complications and to formulate of a treatment strategy.

**Consent:** The case report and the images have been acquired after due informed consent from the patient and her attenders. There was no breach of ethics and the patient identity will remain confidential.

**Conflict of interest:** There is no conflict of interest for any authors

**Funding:** No external funding has been acquired.

**Ethical clearance:** Ethical clearance has been obtained from Institute Ethical Committee (IEC), JIPMER.

## References

- Bandara V, Weinstein SA, White J, Eddleston M. A review of the natural history, toxinology, diagnosis and clinical management of Nerium oleander (common oleander) and Thevetia peruviana (yellow oleander) poisoning. *Toxicol.* 2010;56:273–81.
- Oji O, Okafor QE. Toxicological studies on stem bark, leaf and seed kernel of yellow oleander (*Thevetia peruviana*). *Phytother Res.* 2000;14:133–5.
- Karthik G, Iyadurai R, Ralph R, Prakash V, Abhilash KPP, Sathyendra S, et al. Acute oleander poisoning: A study of clinical profile from a tertiary care center in South India. *J Fam Med Prim Care.* 2020;9:136–40.
- Saravanapavananthan N, Ganeshamoorthy J. Yellow oleander poisoning – A study of 170 cases. *Forensic Sci Int.* 1988;36:247–50.
- Shaw D, Pearn J. Oleander Poisoning. *Med J Aust.* 1979;2:267–9.
- Zibbu G, Batra A. *Thevetia peruviana* (Pers.) Schum . : A plant with enormous therapeutic potential. *J Pharm Res.* 2011;
- Ceci L, Girolami F, Capucchio MT, Colombino E, Nebbia C, Gosetti F, et al. Outbreak of Oleander (*Nerium oleander*) Poisoning in Dairy Cattle: Clinical and Food Safety Implications. *Toxins.* 2020;12:471.
- Taskin O, Belli F, Acikalin A, Disel NR. Add oleander to your list of corrosives. *Turk J Emerg Med.* 2019;19:115–6.
- Pillay VV, Sasidharan A. Oleander and *Datura* Poisoning: An Update. *Indian J Crit Care Med Peer-Rev Off Publ Indian Soc Crit Care Med.* 2019;23:S250–5.
- Eddleston M, Ariaratnam CA, Meyer WP, Perera G, Kularatne AM, Attapattu S, et al. Epidemic of self-poisoning with seeds of the yellow oleander tree (*Thevetia peruviana*) in northern Sri Lanka. *Trop Med Int Health.* 1999;4:266–73.
- Eddleston M, Ariaratnam CA, Sjöström L, Jayalath S, Rajakanthan K, Rajapakse S, et al. Acute yellow oleander (*Thevetia peruviana*) poisoning: cardiac arrhythmias, electrolyte disturbances, and serum cardiac glycoside concentrations on presentation to hospital. *Heart.* 2000;83:301–6.
- Anandhi D, Prakash Raju K, Basha M, Pandit V. Acute myocardial infarction in yellow oleander poisoning. *J Postgrad Med.* 2018;64:123–6.
- Pahwa R, Chatterjee VC. The toxicity of yellow oleander (*Thevetia neriifolia* juss) seed kernels to rats. *Vet Hum Toxicol.* 1990;32:561–4.