

Autopsy Based Prospective Study of Synthetic Cow Dung Poisoning (Yellow Sani Powder Poisoning)

Ganapathy. S¹, Dhuvarakesh Apparaj²,
Jeyasingh. T³, Manoharan. C⁴

¹Assistant Professor, Dept. of Forensic Medicine, Government Theni Medical College, Theni, ²Assistant Professor, Dept. of Forensic Medicine, Madras Medical College, Chennai, ³Professor and Head, Dept. of Forensic Medicine, Coimbatore Medical College, Coimbatore, ⁴Professor and Head, Dept. of Forensic Medicine, Government Medical College and ESIC Hospital, Coimbatore.

How to cite this article: Ganapathy. S, Dhuvarakesh Apparaj, Jeyasingh. T et. al. Autopsy Based Prospective Study of Synthetic Cow Dung Poisoning (Yellow Sani Powder Poisoning). Indian Journal of Forensic Medicine and Toxicology 2023;17(3).

Abstract

Traditionally it is believed that cow dung has germicidal and insect repellent properties in the Indian Sub Continent. South Indian people have been using the natural cow dung for cleaning, lining and painting the courtyard and house premises. In this modern era, owing to the unavailability of natural cow dung, the people have resorted to using synthetic dye (synthetic cow dung) which is called colloquially as “Manjal Sani Powder” in Tamil. Synthetic cow dung powder (Auramine) - a dye compound, even though legally banned, is till date easily available locally with small shops and vendors. Aim of the present study is to explore the postmortem findings of Synthetic cow dung powder (sani powder) poisoning in Western Tamil Nadu i.e, Coimbatore, the Nilgiris, Tiruppur, Erode and Karur districts, the study being conducted in the Department of Forensic Medicine, Coimbatore Medical College. The following parameters were collected and analyzed: the deceased's sex and age, Post mortem findings, histopathological and chemical analysis reports. A total number of 224 cases were analyzed. Most of the deceased persons are of age between 31 to 40 years in females (38.8%) and between 41 to 50 years in males (36.6%). Most of the deceased persons were males (78.1%). Postmortem findings of yellow cow dung poisoning were yellowish discoloration of skin. Internal findings noted were tongue yellow coated. All the internal organs were stained yellow. Intense Vigil and Strict Enforcement of regulations for manufacturing and selling of synthetic dyes can significantly reduce the incidence of Synthetic Yellow Cow Dung (Saani) powder poisoning.

Key words: Yellow cow dung, Auromine, Synthetic dye, Saani powder.

Introduction

Cow dung and Urine (Gomuthra) have been held with reverence and have been mentioned in many places in Ancient Indian History and South Indian Culture in general and more particularly when chronicling regarding the personal hygiene and

community welfare. People in history have cleaned the living premises by using natural cow dung. But nowadays due to non-availability of natural cow dung people have resorted to using synthetic cow dung (Auramine) which is called colloquially as “Manjal Saani Powder” in Tamil. In the region of

Corresponding Author: Ganapathy. S, Assistant Professor, Dept. of Forensic Medicine, Government Theni Medical College, Theni, Tamil Nadu.

E-mail: maranganapathy2012@gmail.com

Mobile: 9443562602

Western Tamil Nadu theyellow Saani powder is more frequently used for suicidal purpose^{2,4}. Though sale of the synthetic cow dung powder is legally banned, it can be purchased from local small shops for as cheap as just 2 or 5 rupees per pocket. The unfortunate part regarding this poison is that there is no specific antidote against it^{1,3}. The aim of the present study is to explore the postmortem findings of Synthetic cow dung powder (sani powder) poisoning in western Tamil nadui.i.e, Coimbatore, the Nilgiris, Tiruppur, Erode and Karur districts.

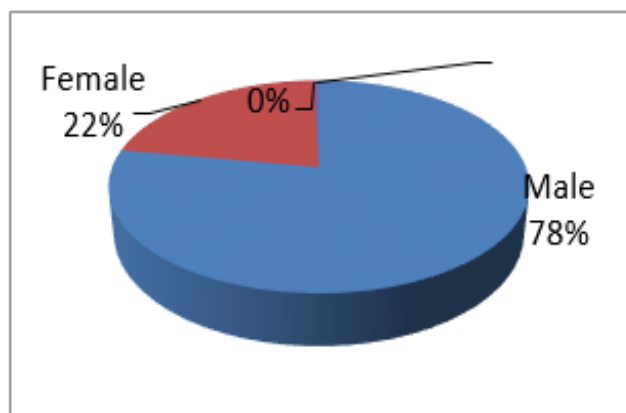
Materials and Method

It is a prospectivestudy conducted in the Department of Forensic medicine, Coimbatore Medical College, Coimbatore from January 2018 to December 2018. The following parameters were collected and analysed: the deceased’s sex and age, Post mortem findings, histopathological and chemical analysis reports.

Result

Among a total number of 4055 autopsies performed, 593 cases were cases of poisoning. In these cases of poisoning, 224 cases were cases of yellow cow dung powder (Manjalsani powder) poisoning. Among these 175 cases(78.1%) were males, 49cases (21.9%) were females.

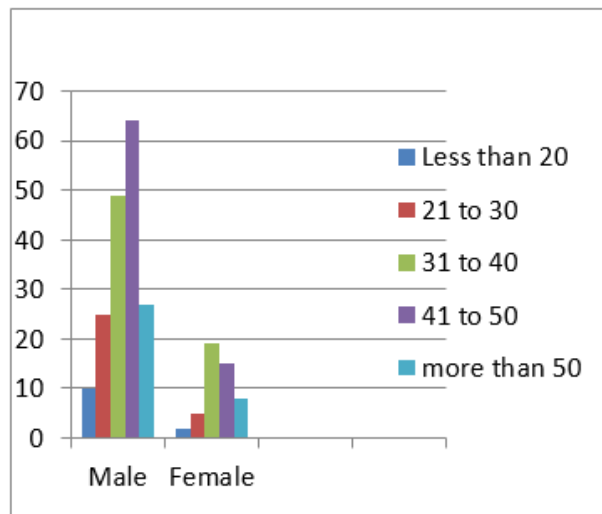
Sex Distribution



Grage 1

Most of the deceased were aged between 31 to 40years in females (38.8%) and between 41 to 50years in males (36.6%).

Age Distribution



Grage 2

Postmortem Findings:

Postmortem findings of yellow cow dung poisoning were yellowish discoloration of skin. Internal findings are tongue yellow coated.

Yellow stains - External appearance



Image 1

Image 2

All the internal organs were yellow stained.

Interior of Stomach

Liver

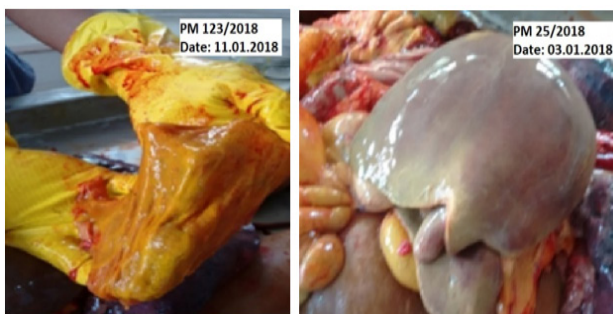

Image 3

Image 4

Intestines

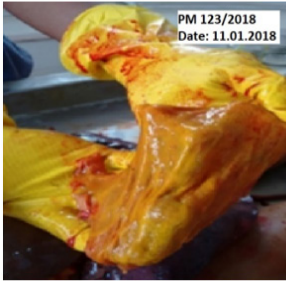

Image 3

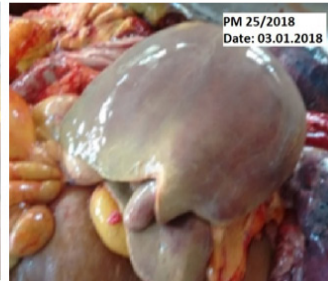


Image 4

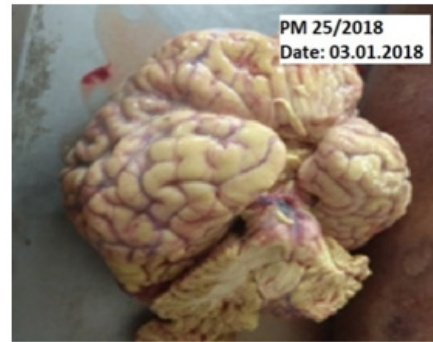


Image 7

Brain

On Histopathological examination Centrilobular necrosis was noted in the liver. Acute glomerular injury was noted in the kidneys.

HISTOPATHOLOGY REPORT FORM					
DEPARTMENT OF PATHOLOGY, COIMBATORE MEIDCAL COLLEGE, COIMBATORE -14.					
Name	Robinsten	Age and Sex	62/M	Lab Ref. No.	MLC 12/2018
Unit	Cr.No.1439/2017 of U/S 174 Cr Pc South PS Tiruppur	Hospital	P.M No.25/2018 Dated 03.01.2018	Date of Report	17.03.2018
Specimen Received : Liver, Kidneys					
HPE REPORT:					
Multiple sections studied from the Liver show Centrilobular Necrosis					
Multiple sections studied from Both kidneys show features of Acute Glomerular Injury					
 PATHOLOGIST (DR.T.PAVITHRA,MD)					

Dr. T. Pavithra
 641 014

HISTOPATHOLOGY REPORT FORM					
DEPARTMENT OF PATHOLOGY, COIMBATORE MEIDCAL COLLEGE, COIMBATORE -14.					
Name	Valliyammal	Age and Sex	55/F	Lab Ref. No.	MLC 12/2018
Unit	Cr.No.28/2018 of U/S 174 Cr Pc Salur PS	Hospital	P.M No.123/2018 Dated 11.01.2018	Date of Report	29.03.2018
Specimen Received : Liver, Kidneys					
HPE REPORT:					
Multiple sections studied from the Liver show Centrilobular Necrosis					
Multiple sections studied from Both kidneys show features of Acute Glomerular Injury					
 PATHOLOGIST (DR.T.PAVITHRA,MD)					

Dr. T. Pavithra
 641 014

Centri-lobular Necrosis of Liver: Showing Viable(1) and Non-Viable Areas(2)

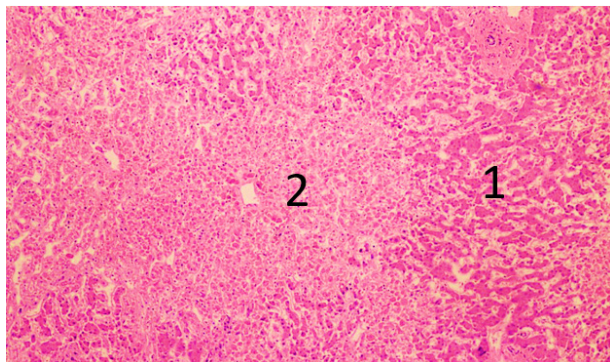


Image 8

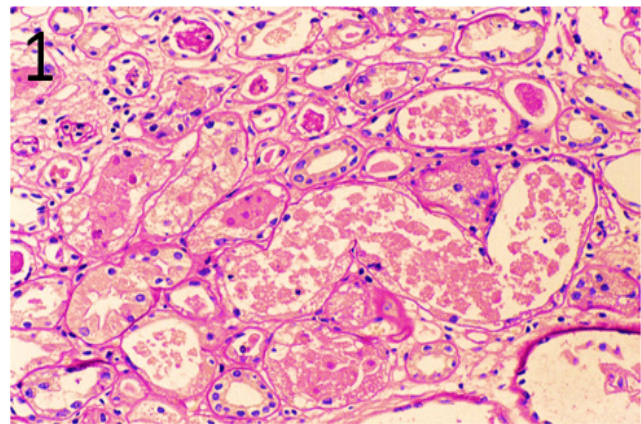


Image 9

Acute Glomerular Injury: Showing Acute Tubular Necrosis(1) and Interstitial Acute Glomerulonephritis(2)

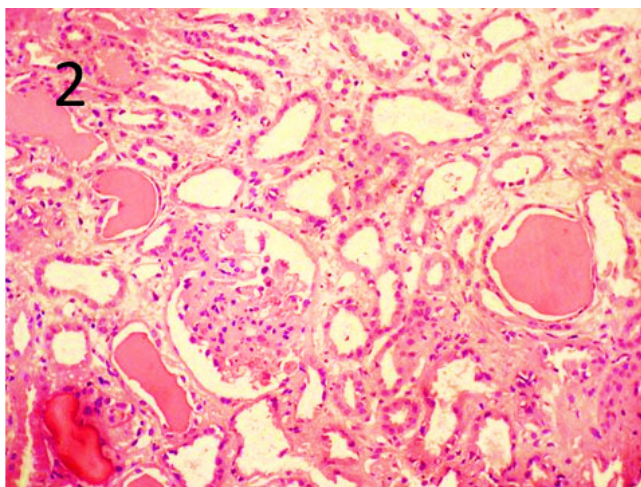


Image 10

Discussion

The present prospective study was conducted between January 2018 and December 2018. Among total 593 poison cases, 224 cases were yellow cow dung (Yellow Saani) powder poisoning. Commonly affected sex was male (78.1%). Most of the deceased are age between 31 to 40 years in females (38.8%) and between 41 to 50 years in males (36.6%). There are two type of synthetic cow dung powder.

1. Auromine - yellow saani powder chemically known as Diaryl methane and molecular formula of $C_{17}H_{21}N_3.HCl$

Acute exposure to Auromine is neurotoxic poison which causes Convulsions, Spasm, Focal deficit and CNS depression^{2,5}. Severe hepatic toxicity due to centrilobular necrosis also occurs. Kidney failure also occur due to acute glomerular injury. It also cause gastro-intestinal tract irritation. In gastro intestinal tract it causes mucosal damage. Yellow stains due to deposition of auramine pigments³. In liver function test SGPT and SGOT were elevated with normal bilirubin level³. Other studies confirm DNA damage induced by auramine in liver, kidneys and bone marrow of rats and mice. Chronic exposure causes bladder cancer, lymphatic cancer and also causes reproductive damage in humans⁶.

2. Melachite green- Greensaani powder chemically known as Diphenyl methane^{2,4} and molecular formula of $C_{25}H_{23}CN_2.HCl$.

Melachite green causes hepatic damage, Hepatic tumor and Lung adenoma¹

Differential diagnosis for Auramine poisoning are

1. **Paraquat poisoning:** Yellow stains noted over scalp and internal organs but not in the around the mouth and palms. The yellow stains due to acute hepatic failure. It causes lung damage by pulmonary edema, pulmonary hemorrhage and fibrosis.

2. **Infectious hepatitis:** There is history of fever, itching and jaundice. In liver function test- elevated level of all markers mainly elevated level of bilirubin.

Conclusion

Illegal sale and most importantly suicidal ingestion of yellow cow dung powder is prevalent not only in rural areas but also in urban areas. Steps have to be taken to telecast and publish promotions in mass media and increase the public awareness. A standard treatment protocol has to be developed and should be implemented to reduce the mortality and morbidity associated with yellow cow dung poison. Intense Vigil and Strict Enforcement of regulations for manufacturing and selling of synthetic dyes can significantly reduce the incidence of Synthetic Yellow Cow Dung (Saani) powder poisoning.

Conflict of Interest: Nil.

Source of Funding: Self.

References

1. Hisham Md, Vijaya Kumar et al: Auromine and Melachite green poisoning- Rare and fatal; Indian Journal of pharmacy practice Dec 2013; Vol.6,72-74.
2. Avinash et al: Sani powder poison -legally banned; International journal of scientific and research publications, 2016; Vol.6,101-109.
3. Khaja Mohideen Sherfudeen: Indian journal of Critical care medicine 2015, 19(11)
4. Muruganathan et al: Yellow cow dung powder- (Auromine poisoning)- study of clinical profile and strategies of management; IOSR journal of dental and medical sciences 2017, Vol.16; 54-59.
5. Subramanian Senthil Kumaran et al: Synthetic cow dung powder poisoning- therapeutic aspects; Indian journal of critical care medicine 2016, Vol.20;74-75.
6. Paroti S, Santi L et al: DNA damage induced by Auramine O in liver, kidney and bone marrow of rats and mice and in human cell line (Alkaline elution assay and SCE induction) Toxicol environ health 1982;9:941-52[PubMed].