

Lymphangioma of Lip: A Case Report

Mohammad Ehtisham¹, Sheeba Nissar², Sonia Gupta³, Shahla Khan⁴, Rehan Khan⁵

¹Senior Lecture, Department of Oral Pathology, Teerthanker Mahaveer Dental College and Research Centre, Moradabad, U.P., ²Senior Lecture, Department of Periodontology, Teerthanker Mahaveer Dental College and Research Centre, Moradabad, U.P., ³Tutor, Department of Oral Pathology, Govt. Dental College & Hospital, Srinagar (J&K), ⁴Senior Lecture, Department of Oral Pathology, Institute of Dental studies & Technologies, Modinagar, U.P., ⁵Senior Lecture, Department of Periodontology, Institute of Dental studies & Technologies, Modinagar, U.P.

Abstract

Lymphangiomas are congenital benign tumors of lymphatic system commonly found in the head and neck region but they are extremely rare entity in the oral cavity. The common site of occurrence for lymphangioma in the oral cavity is the anterior dorsum and lateral border of tongue but has been reported in other parts of oral cavity such as the palate, cheeks, floor of the mouth, gingiva and lips. The most accepted treatment option for lymphangioma is complete surgical excision. There is only a minimal chance of recurrence. In this article we report a rare case of lymphangioma of the lower lip of 55-year old male patient.

Keywords: Lymphangioma, Capillary Lymphangioma, Cavernous Lymphangioma, Cystic Lymphangioma.

Introduction

Lymphangiomas are uncommon, benign, congenital malformations of lymphatic vessels found on the skin and subcutaneous tissue usually diagnosed in infancy and early childhood as lobular masses¹. This hamartomatous lesion was first explained by **Redenbacher (1828)**². Occurrence of a lymphangioma in an adult is uncommon /infrequent³. Literatures reveal that approximately 75% of cases of lymphangiomas occur in the head and neck region but they are extremely rare in the oral cavity⁴. Tongue is the most frequent site of involvement in the oral cavity^{5,6}. Palate, buccal mucosa, gingiva, floor of the mouth and lips are the less frequently involved sites⁷. They are believed to come in existence as a result of lymph sac sequestration, which is not able to establish the communication with larger lymphatic channels.

Enlargement of lymph vessels are due to improper drainage or excessive secretion of lining cells⁸. There are various treatment methods for lymphangioma, which include surgical excision, laser therapy, sclerotherapy or a combination of these⁹. The present case report about a rare case of lymphangioma of the lower lip in an adult managed by surgical excision with a review of the scientific literature.

Case Report

A 55-year old male patient reported to the Department of Oral Medicine & Radiology with the chief complaint of a growth on the lower lip for the past seven months. The patient stated that a rapid enlargement of the growth occurred after dental treatment. He gave a history of a similar growth on the same site about one & half year back, which was treated by the surgery. On clinical examination, a painless growth was seen on the left side of lower lip in relation to 32, 33 region. The lesion appeared as single, reddish pink, transparent, swelling with an irregular surface and borders (Fig. 1). A differential diagnosis of lymphangioma and mucocele were given based on the clinical features. Wide surgical excision of the lesion was carried out and the biopsy specimen sent for histopathological examination (Fig.

Corresponding Author:

Dr. Mohammad Ehtisham

B-3 Flat No. 007

Jamia Apartments Abul Fazal Enclave

Jamia Nagar Okhla New Delhi 110025

Email Id: ehtians@gmail.com

Mobile No.: 9891194154

2 & 3). On gross examination, a soft tissue bit received measuring approximately 1.2×0.6 cm in dimension, creamish brown in colour, firm in consistency (Fig. 4). Histopathologically, H&E stained sections reveal **numerous dilated lymph vessels**, lined by a single layer of flattened endothelial cells along with a few containing **lymph**. The overlying epithelium is parakeratinized stratified squamous type. Post-operative wound healing was satisfactory & no complication was noticed (Fig. 5 & 6).

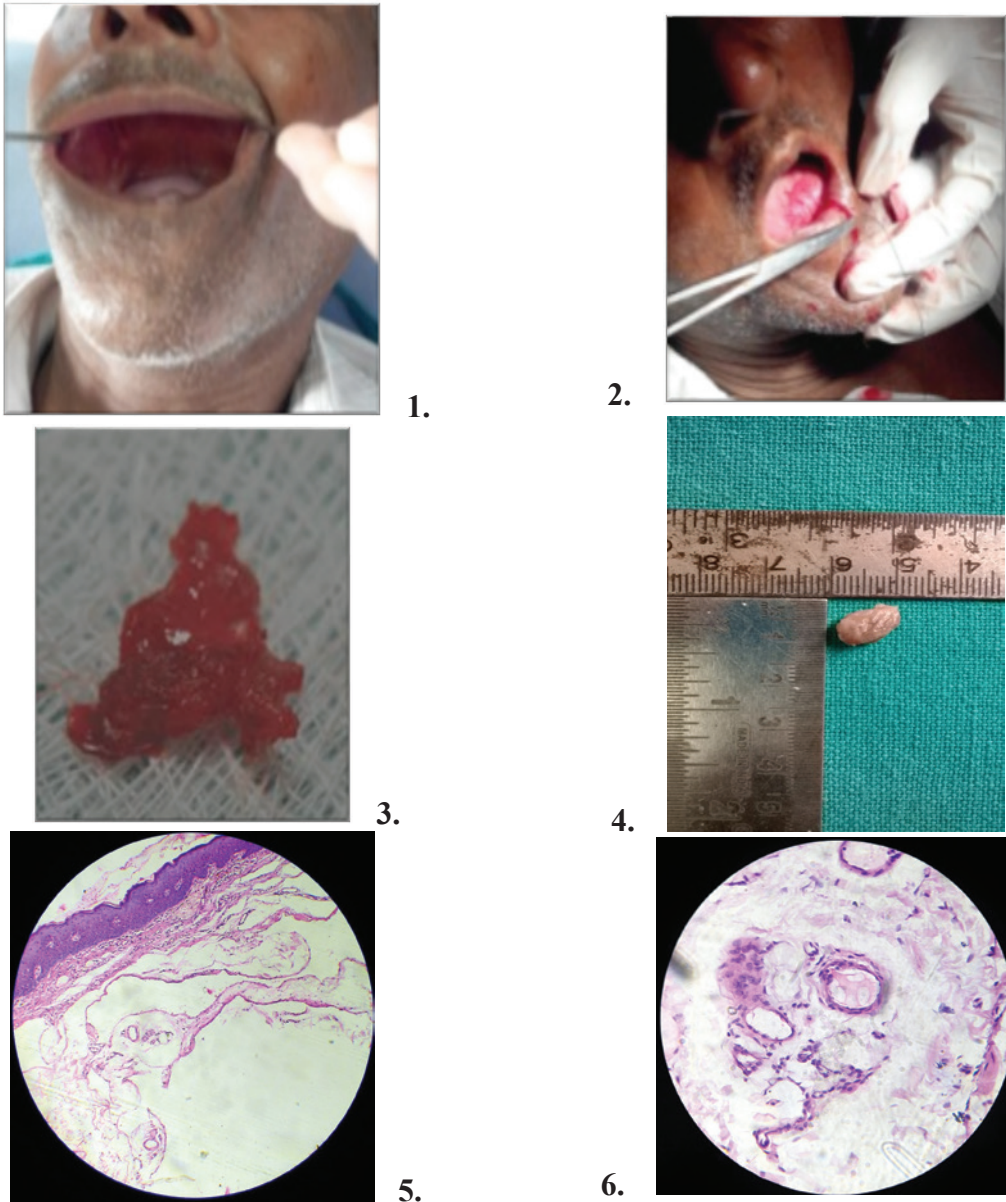


Fig. 1: Lymphangioma of Lip.

Fig. 2 & 3: Surgical excision.

Fig. 4: Gross examination.

Fig. 5: Photomicrograph (10X) showing Enlarged lymphatic vessels containing lymph are seen in the superficial connective tissue.

Fig. 6: Photomicrograph (40X) showing lymphatic vessels containing lymph.

Discussion

Lymphangiomas are benign, hamartomatous tumors of lymphatic system¹⁰. They are developmental malformations, which come in existence due to sequestrations of lymphatic tissue that do not communicate normally with the rest of the lymphatic system⁸. Oral lymphangiomas may occur at various

sites of oral cavity but are more frequently seen in the anterior two-thirds of the tongue, where they often cause macroglossia¹¹. **Brennan et al.** revised 49 cases of oral lymphangioma and found that *most were located in tongue*¹². Irregular nodularity of the surface of the tongue with gray and pink projections and macroglossia is the pathognomonic feature of lymphangioma of the tongue¹¹. Therefore, the case described here shows not so common site of oral lymphangioma involving the lip. Lesion developed in this patient older than the common age.

Features	From the literature	Our Patient
Age	Usually diagnosed in infancy & early childhood.	65 Years
Gender	No definite sex predilection noticed.	Male
Location	Most usual locations are Head & Neck. Lower lip is an uncommon site comprising of approximately 6% of all oral lymphangiomas.	Lower Lip

Usually, the tumor is superficial in location and shows a pebbly surface, mimicking like cluster of translucent vesicles. The surface appears like “frog eggs /tapioca pudding”. Superficial lesions are described as as papillary lesions, which may be of the same color as the surrounding mucosa or of a slightly reddish hue. Deeper lesions arises as soft, ill-defined masses & appear as diffuse nodules or masses without any significant change in surface texture or color¹³.

Histopathologic features consist of lymphatic vessels with marked dilatations. The vessels often diffusely infiltrate the adjacent soft tissues and demonstrate lymphoid aggregates in their walls. The lining endothelium is thin and the spaces contain proteinaceous fluid and lymphocytes. Secondary hemorrhage may be noticed in the lymphatic vessels. The lymphatic spaces contain lymphatic fluid, red blood cells, lymphocytes, macrophages, and neutrophils. Underlying connective tissue stroma consists of loose fibrotic tissue with a number of inflammatory cells^{7,11}. There are three types of lymphangioma.

1. Capillary Lymphangioma consists of small capillary-sized vessels.

2. Cavernous Lymphangioma consists larger dilated lymph channels.

3. Cystic Lymphangioma exhibits large macroscopic cystic spaces¹¹.

Occasionally lymphatic vessels may be filled with RBCs, which is known as **hemangiolymphangioma**¹³. Often all three histological types may be found in the same lesion. Among these the most common type in oral cavity is the cavernous lymphangioma. More often, all sizes of vessels may be found within the same lesion¹⁴. In the intraoral lymphangiomas, lymphatic vessels are located just beneath the epithelium, often replacing connective tissue papillae¹¹. Correlating the histopathological features of the present case with the clinical features it is suggestive of “**lymphangioma**”.

Lymphangiomas of lateral and posterior neck region are frequently associated with chromosomal anomalies like Noonan’s syndrome, Turner’s syndrome and foetal hydrops¹⁵. Primary intra-osseous lymphangioma

is a very rare lesion that occurs as a result of gradual extension of a peripheral soft tissue lymphangioma to the periosteum of adjacent bone and into the marrow spaces¹⁶. Early diagnosis may be established with the help of ultrasonography, MRI, arteriogram and CT angiography¹⁷. In the oral cavity, lesions like haemangioma, thyroglossal duct cyst, lingual thyroid, cheilitis granulomatosa, granular cell tumour, mucocele/ranula and cellulitis may be considered for differential diagnosis¹⁸.

Treatment

Wide surgical excision is the treatment of choice¹⁹. Multiple treatment modalities have been recommended for deep seated and large lesions, which include cryotherapy, electrocauterization, administration of steroids, sclerotherapy (OK- 432), laser therapy and embolization²⁰. According to **Gilberth**, CO2 laser technique was more convenient & successful with less chance for the recurrence than any other treatment²¹. Sclerosing agents are not as much effective in lymphangioma as do in hemangiomas²². Recurrence of lymphangioma is common because complete removal is difficult due to the non-encapsulated and “infiltrating” nature of the lesion^{11,23,24}.

Conclusions

In conclusion, appearance of a lymphangioma in an adult is infrequent entity and rarely seen in oral cavity, so lymphangiomas are an eventuality to take into consideration by the clinician to avoid future complications. Early recognition is of utmost importance to initiation of proper treatment and avoidance of complications.

Conflicts of Interest:

Prior publication	NIL
Support	NIL
Conflicts of interest	NIL
Permissions	NIL

We hereby transfer, assign, or otherwise convey all copyright ownership, including any and all rights incidental thereto, exclusively to the journal, in the event that such work is published by the journal.

Bibliography

1. Stănescu LI, Georgescu EF, Simionescu CR, Georgescu IU. Lymphangioma of the oral cavity. Rom J Morphol Embryol. 2006;47(4):373-7.
2. Pammar C, Kotrashetti VS, Nayak R, Hosmani J. Lymphangioma of the buccal mucosa: A case report with a literature review. Journal of Orofacial Sciences. 2015 Jul 1;7(2):129.
3. Mathew M, Dil SK. Adult lymphangioma—a rare entity: a report of two cases. Turkish Journal of Pathology. 2012 Jan 1;28(1):80-2.
4. Singh JK, Yadav DK. Lymphangioma tongue-A case report. Current Pediatric Research. 2010 Jan 1;14(1).
5. Usha V, Sivasankari T, Jeelani S, Asokan GS, Parthiban J. Lymphangioma of the tongue-a case report and review of literature. Journal of clinical and diagnostic research: JCDR. 2014 Sep;8(9):ZD12.
6. Khurana S, Vij A, Singal A, Pandhi D. Lymphangioma of the tongue: response to intralesional steroids. Journal of dermatological treatment. 2006 Jan 1;17(2):124-6.
7. Bhayya H, Pavani D, Tejasvi MA, Geetha P. Oral lymphangioma: A rare case report. Contemporary clinical dentistry. 2015 Oct;6(4):584.
8. Mirza B, Ijaz L, Saleem M, Sharif M, Sheikh A. Cystic hygroma: an overview. Journal of cutaneous and aesthetic surgery. 2010 Sep 1;3(3):139.
9. Ramashankar CP, Shah NK, Giraddi G. Lymphatic malformations: A dilemma in diagnosis and management. Contemporary clinical dentistry. 2014 Jan;5(1):119.
10. Yoganna SS, Prasad RG, Sekar B. Oral lymphangioma of the buccal mucosa a rare case report. Journal of pharmacy & bioallied sciences. 2014 Jul;6(Suppl 1):S188.
11. Sunil S, Gopakumar D, Sreenivasan BS. Oral lymphangioma-Case reports and review of literature. Contemporary clinical dentistry. 2012 Jan 1;3(1):116.
12. Brennan TD, Miller AS, Chen SY. Lymphangiomas

- of the oral cavity: A clinicopathologic, immunohistochemical, and electron-microscopic study. *J Oral Maxillofac Surg.* 1997;55:932-5.
13. Shetty D, Urs A, Rai H, Ahuja N, Manchanda A. Case series on vascular malformation and their review with regard to terminology and categorization. *Contemporary clinical dentistry.* 2010 Oct 1;1(4):259.
 14. Shelmire B. Benign tumors and cysts of the oral cavity. *International Journal of Orthodontia, Oral Surgery and Radiography.* 1931 Mar 31;17(3):262-78.
 15. Rodeck CH, Whittle MJ. *Fetal medicine: basic science and clinical practice.* Elsevier Health Sciences; 2009.
 16. Park YW, Kim SM, Min BG, Park IW, Lee. Lymphangioma involving the mandible: immunohistochemical expressions for the lymphatic proliferation. *J Oral Pathol Med* 2002; 31: 280-3.
 17. Oshy J, Owibingire S, Shaban S. Vascular lesions seen among patients treated at Muhimbili national hospital in Dar es Salaam, Tanzania. *East and Central African Journal of Surgery* 2011;16:3.
 18. Iamaroon A, Pongsiriwet S, Srisuwan S and Krishnaprakornkit S. Lymphangioma of the tongue. *International Journal of Paediatric Dentistry* 2003;13: 62-63.
 19. Hönig JF, Merten HA. Surgical removal of intra- and extraoral cavernous lymphangiomas using intraoperative-assisted intralesional fibrin glue injections. *Journal of Craniofacial Surgery.* 2000 Jan 1;11(1):42-5.
 20. Vasconcelos MG, Santos BC, Lemos LCP, Ribeiro BF, Iglesias DPP, Vasconcelos RG, Costa de Medeiros AM. Oral lymphangioma: Case report: *RSBO* 2011;8:352-6.
 21. Acirole GT, Acirole JM, Soares LG, Santos NR, Santos JN, Pinheiro AL. Surgical treatment of oral lymphangiomas with CO2 laser: report of two uncommon cases. *Brazilian Dental Journal.* 2010;21(4):365-9.
 22. Gunderson LL, Tepper JE. *Clinical radiation oncology.* Elsevier Health Sciences; 2015 Aug 12.
 23. Rajendran R. *Shafer's textbook of oral pathology.* Elsevier India; 2009.
 24. Nagpal, T., Shah, D., Manjunatha, B., & Mahajan, A. (2015). Macroglossia Associated with Lymphangioma: Surgical Management of An Interesting Case. *Journal of Clinical and Diagnostic Research : JCDR,* 9(11), ZD04-ZD06.