

Retrospective Study: Evaluating the Positioning Errors in Digital Panoramic Radiographs

Sanjeet Singh¹, Inderpreet Singh², Farooq Ahmed³, Arshid Baba⁴

¹Assistant Professor, I/c Head of Department, Department of dentistry , GMC, Anantnag, ²Senior Registrar, Government Dental College, Srinagar, ³Senior Resident, Department of Dentistry, Governement Medical College, Anantnag, ⁴BDS, Maxillofacial Imaging Centre, Srinagar.

How to cite this article: Sanjeet Singh, Inderpreet Singh, Farooq Ahmed et. al. Retrospective Study: Evaluating the Positioning Errors in Digital Panoramic Radiographs. Indian Journal of Contemporary Dentistry 2022;10(2): 5-8.

Abstract

To produce a panoramic radiograph with a constant image quality common errors must be kept to a minimum. This study is conducted with an objective to analyse the most prevalent positioning and technical errors in panoramic radiographs.

300 Orthopantomograms(OPGs) were taken from January 2020 to December 2021 in the Maxillofacial Imaging centre and they were assessed by three maxillofacial radiologists for analysing positional errors.

Using the OHP sheet, all radiographs were viewed on a computer monitor to demarcate the "6" Zones. Results showed that around 52 radiographs were error free (17.3%) and 248 radiographs had errors (82.6%). The radiographs having single positional error were 205(82.66%). The radiographs having two positional errors were 35(14.1%). The radiographs having three positional errors were 8(3.2%).

The outcome of analysis reveals that percentage of positioning errors in panoramic radiographs is fairly high which reduces its diagnostic value. The Technicians are made aware of the errors and are instructed to double check the patient's position before taking radiographs.

Keywords: Focal Trough; Digital Panoramic Radiograph; Errors.

Introduction

Panoramic radiograph is a technique for producing a single topographic image of the facial structures that includes both the maxillary and mandibular dental arches and their supporting structures.¹

A panoramic radiograph provides us an overview of dental arches and also a close view of a large number of anatomical structures such as the maxillary sinuses, hyoid bone and Temporomandibular joints.^{1,2}

Simple technique, with easy and quick processing

Corresponding Author: Inderpreet Singh, Senior Registrar, Government Dental College, Srinagar.

E-Mail: Aosp1011@gmail.com

Mobile: 8057421180

with a small amount of radiation to patient and operator are the reasons for its developing popularity.²

Faults in the technique i.e the errors which are related to preparing the patient for film exposure; errors in film exposure and processing and errors in handling the film are some of the common errors.^{2,3} Out of all errors, the critical study was done on errors related to patient positioning.

The aim of this study is to analyze the most prevalent positioning error in panoramic radiograph and discussing the ways to improve the quality of radiographs.

Materials and Methods

Total 300 digital panoramic radiographs were selected in a random manner from the stored patient data files of the Maxillofacial Imaging centre. Each radiograph was taken by the same technician with an experience of 10 years during the period of January 2020 to December 2021 using planmeca digital panoramic machine operating at 68 kVp, 11 mA with an exposure time of 18 seconds. The exclusion criteria of this study includes; radiographs of children less than 15 years of age, radiographs with more than three error, edentulous patient and patients with history of maxillofacial trauma.

The selected radiographs were imported to a laptop (Dell laptop with a 14.1 inch screen, 1280 x 800 screen resolutions, and 32 bit colour mode) and they were displayed and viewed under optimal brightness and contrast. Overhead projection sheet on which lines were drawn vertically to simulate the six zones as described by Langland and Langlais was attached to the laptop monitor.

Each radiograph was evaluated by three experienced oral and maxillofacial radiologists for positioning errors. The data was analyzed using a statistical package for social sciences 15.0 software.

Results

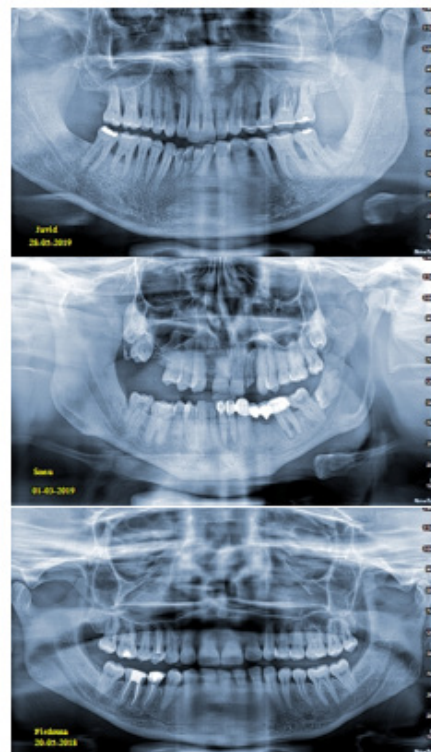
The 300 patient's panoramic radiographs were evaluated for positioning errors. Out of these, 52 radiographs (17.3%) were error free and 248 were having errors (82.6%).

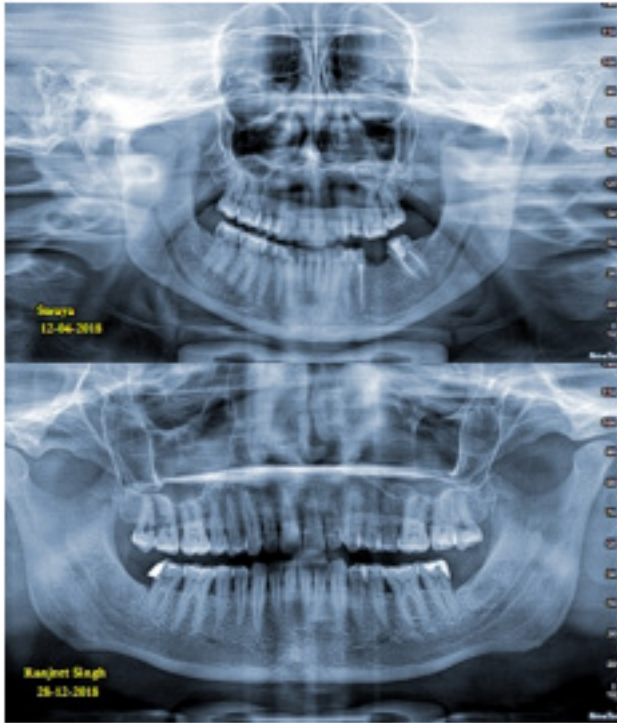
The radiographs having single positional error were 205(82.66%). The radiographs having two positional errors were 35(14.1%). The radiographs having three positional errors having 8(3.2%). The most typical error was the patient's chin is tipped too high i.e 55 patients (22.1%) followed by the head is twisted/rotated i.e. 36 patients (14.5%) the least common error was positioning the patient too forward in relation to the focal trough 10.08%.

Percentage Distribution of Positioning Errors in Panoramic Radiographs

	Positioning Errors	N (%)
Error 1	Chin is Tipped Too High	22.1%
Error 2	Head is Twisted/ Rotated	14.5%
Error 3	Patient is Positioned Too Backward	12.9%
Error 4	Tongue is not on the Palate	10.08%
Error 5	Chin is Tipped Too Low	9.6%
Error 6	Patient is Positioned Too Forward	9.2%
Error 7	Patient is Slumped	9.2%

Fig: Radiographs showing positional error





Discussion

Dental panoramic radiograph is very popular radiographic technique in dentistry. The main reason for this includes.

1. The technique is reasonably simple
2. All the teeth and their supporting structures are shown in one film.
3. Radiation dose is comparatively low, particularly with modern DC units with rare earth intensifying screens.^{2,3}

It is commonly performed by dentists and oral surgeons in everyday practice and it is used to investigate and plan treatment for dentures, implants and braces extractions.

In this study, the OHP sheet which were used on the monitors ensured that none of the errors were missed out and it further helped in standardizing the technique.

The positioning of patient's head in this type of the equipment is critical.³ The image layer is a 3 dimensional curved zone which is also called focal trough in which structures lying within the layer are reasonably well defined on final panoramic image. The structures seen in a panoramic image are primary

those located within the image layer, objects outside this zone of sharp focus are blurred, magnified or reduced in size and are sometimes distorted to the extent of not being recognizable. The final quality of the image is related to image of the patient during the exposure and the accuracy of the jaw position within the image layer.^{2,3}

From the evaluated 300 panoramic radiographs, the most typical error observed was "chin is tipped too high" 55 patients (22.1%). This result is similar to the other studies.⁴ To rectify this error the vertical plane of occlusion should be positioned parallel to the floor.

The second most common error in this study was "Patient's head rotated/twisted" 36 patients i.e 14.5%. this result was identical to other studies.^{5,6} Rotation of the head hinders the diagnostic interpretation. Proper attention must be given to the position of the light beam marker for the mid-Sagittal plane before the exposure is accomplished.

In most of the previous studies, third most common error is chin tipped too low^{7,8} but in our study the third most common error was "patient is positioned backwards" 32 patients i.e 12.9%.

The fourth most common error is "tongue not resting on the palate" 10.08% which is in accordance with the study by Akarslan et al.⁹ If the tongue will not rest on the palate then it will result in a dark shadow which will obscure the apices of the maxillary teeth. It is one of the commonly noticed errors on the panoramic radiograph.^{9,10}

This fifth most common error was "chin tipped too low" which involved 24 patients i.e 9.6%. Many studies have rated this error in their top 3's. The reason for this error is contracted arches, closer appearance of the condyles and cut off from top of the film will give an overall appearance of a "Cheshire cat grin" due to the accentuated curve of speed.¹⁰ The error can be rectified by positioning the mid sagittal plane perpendicular or right angle to the floor and centred right to left.¹¹

The sixth and seventh most common errors i.e "patient positioned too forward and patient slumped" had a same percentage respectively which involved 23 patients each with percentage of 9.2.

While imaging, when patient holds the handles of the machine there are chances of patient slumping. This will lead to a ghost shadow on the midline created by the superimposition of an increased mass of cervical spine. The operator should ensure the patient's spine are erect and neck extended.⁶ the results were coinciding with other studies.¹¹

These were the single most common errors noticed on the radiographs. Two positional errors were seen on only 35 radiographs i.e 14.1%. Three positional errors were seen on only 8 radiographs. These multiple errors occurred in one image, this can be due to an inadequate time was spent for patient preparation and positioning by the operator.¹²

Going through the different studies and evaluating the research, such errors can be decreased and there is a scope of improvement every time. By rechecking the position and by repeated instructions to the patient can markedly decrease the percentage of errors. Still few unavoidable circumstances will always be there like short and heavy neck, facial asymmetry and patient's inability to follow the instructions.

Conclusion

The errors on the radiographs are multifactorial. The most common error is the positioning of the patient. The operators/technicians should be explained to make sure they instruct and position the patient in a most appropriate position to get the best results. Random auditing of the radiographs should be repeated in intervals for improving the quality of the radiographs.

Declaration of Ethical clearance: Taken from ethical committee of institute

Source of funding: Self

Conflict of Interest: Nil

References

1. Peretz B, Gotler M, Kaffe I. Common errors in digital panoramic radiographs of patients with mixed dentition and patients with permanent dentition. *International Journal of Dentistry*. 2012 Feb 8; 2012.
2. Whaites E. *The quality of Radiographic images and quality Assurance: principals of radiographic interpretation*. 3rd edition. Longman group UK Limited: Elsevier; 2002. P. 179-93.
3. Whiteand SC, Pharaoh MJ, *Panoramic Imaging: Oral Radiology Principles and Interpretation*. 5th ed. Westline Industrial Drive, St. Louis. Missouri: Mosby Elsevier; 2008. p. 191-209.
4. Randon RH, Pereira YC, do Nascimento GC. Common positioning errors in panoramic radiography. *A Review. Imaging Science in Dentistry*. 2014 Mar 1; 44(1)- 6.
5. Schiff T, D'Ambrosio J, Glass BJ, Langlais RP, McDavid WD. Common positioning and technical errors in panoramic radiography. *J Am Dent Assoc* 1986; 113: 422-6.
6. Bissoon AK, Whaite E, Moze K, Naidu R. Evaluation of common operator errors in panoramic radiography in Trinidad and Tobago: a comparison of formally vs informally trained operators. *West Indian Medical Journal*. 2012 Oct; 61(7): 733- 8.
7. V Asha et al.; positioning errors in digital panoramic radiographs- A retrospective analysis. *IJARIIIT* 2018. Vol 4(6): pg 517- 21.
8. Subbulakshmi AC, Mohan N, Thiruneervannan R, Naveen S, Gokulraj S. Positioning errors in digital panoramic radiographs. *J Orofac Sci* 2016; 8: 22-26.
9. Akarslan ZZ, Erten H, Güngör K, Celik I. Common errors on panoramic radiographs taken in a dental school. *J Contemp Dent Pract* 2003;15;24-34
10. Rushton VE, Horner K. The use of panoramic radiology in dental practice. *J Dent* 1996; 24:185-201.
11. Granlund CM, Lith A, Molander B, Gröndahl K, Hansen K, Ekstubb A. Frequency of errors and pathology in panoramic images of young orthodontic patients. *Eur J Orthod* 2012; 34: 452-7.
12. AL-Faleh W. Dr Common Positioning Errors in Panoramic Radiography. Available from: http://faculty.ksu.edu.sa/pan_positioning_errors.