

Gonial Angle as a Determinant of Gender, a Panoramic Study in a Sample of Saudi Population

Ahmed Ali Alfawzan

*Department of Preventive Dentistry, Alrass Dental College, Qassim University,
Saudi Arabia, Qassim, Saudi Arabia*

Abstract

Introduction: Sex determination is a valuable factor in forensic dentistry. The present study aims to assess the possibility of using gonial angle as a determinant of gender through a retrospective panoramic study, in a sample of Saudi population.

Materials and Method: A 342 digital panoramic radiographs (179 males and 163 females) of adult dentulous Saudi patient attending university dental hospital, Qassim university, KSA were assessed in this study were assessed in this study. Gonial angle measurements were calculated bilaterally.

Results: The mean values were calculated and compared between male and female subjects using SPSS (V. 22). Level of significance was set at 0.005. The mean values of the external gonial angle measured using the panoramic radiographs were $125.50 \pm 5.95^\circ$ and $127.45 \pm 6.77^\circ$, respectively.

Conclusion: In the present study, statistically significant difference was observed between the gonial angles measured in between males and females using panoramic radiographs. Gonial angle can be considered reliable for gender determination.

Keywords: *Gonial angle, Gender, Retrospective, Sex determination, Panoramic.*

Introduction

In dental practices diagnosis and treatment planning can be formulated by utilizing the gathered data from the case history and diagnostic aids such as clinical examinations, study models, and the relevant radiographs. Dentofacial radiography has become a critical procedure in the dental, medical, and hospital clinics. Similarly, lateral cephalogram and panoramic radiograph are essential for diagnosis and treatment planning in orthodontics.¹

The gonial angle in cephalometric x-rays is an important parameter for determining the growth pattern of an individual, assessing the rotation of the mandible¹ and the extraction pattern in class II patients,² making decisions regarding whether to perform surgery in class III skeletal base patients,³ and estimating age in forensic medicine.^{4,5}

Panoramic radiography, which is considered the

gold standard of care for dental screening, diagnosis and treatment planning, is used by dentists from other specialties and orthodontists alike. It provides a significant amount of information about the dentation and the supporting bone, and also is used for screening of pathological and developmental problems such as cysts, tumors, cancer, supernumerary teeth, the congenital absence or premature loss of teeth, fused teeth to the bone, abnormally retained teeth, tooth eruption path especially of third molars, bone pathology, and mandibular asymmetry.^{6,7} Panoramic radiography are useful for measuring the gonial angle with accurate performance than lateral cephalography, as the superimposed gonial angles in cephalography can affect their tracing.^{8,9}

A panoramic radiograph provides adequate information about both left and right sides; hence, it would be reasonable to assess them equally.^{10,11} Determination of gender is an important part of forensic science and anthropology and in medico-legal issues.

Among various other measures, gonial angle can be used to differentiate between male and female strongly to express univariate sexual dimorphism. When skeletal sex determination is considered, angular and metric analyses on the radiographs are often found to be of greater importance because of their, reliability, reproducibility, accuracy and objectivity.^{12,13}

Determination of sex becomes more appropriate after attainment of puberty as the differences are well marked well in skull and bony pelvis.¹⁴ After both these bony areas, mandible remains the next best in the human beings which will help us in the identification of age, sex, and race.¹⁴ Therefore, mandibular condyle and ramus, in particular, are generally the most sexually dimorphic.^{12,13} There by among various radiographic technique the orthopantomography (OPG) is still best used as a measure in determination of sex wherein, the morphology of mandibular ramus is researched. Changes in gonial angle (mandibular angle) are of important value in age and sex determination. Very few studies have been carried out to study the changes in the mandibular angle with age, sex and dental status. One of the choices for gonial angle measurement is panoramic radiograph. Hence, this study was taken to understand gonial angle as adeterminant of gender in a panoramic study in a sample of Saudi population.

Materials and Method

Ethics approval (#DRC/002FA/19) for the study was obtained from the Dental Ethics Committee, Alrass Dental College, Qassim university, KSA. Digital panoramic radiographs (OPG) of 324 patients (163 females and 179 males; mean age of 29.05 ± 7.93 years) were obtained from the department of radiology, university dental hospital, Qassim university, KSA. The inclusion criteria for the OPG were: patient in permanent dentation stage, the OPG had to be of high image quality and sharpness and all OPGs had to be taken using the same machine. The exclusion criteria were a recorded history of facial trauma, previous facial/mandibular surgery, and congenital syndromes affecting the face or jaw, and asymmetry of face. The gonial angle was drawn with a tangent to the lower border of the mandible and another line tangent to the distal border of the ascending ramus and the condyle on both the sides then the gonial angle was measured at the point of intersection of the plane tangential to the lower border of mandible and to the distal border of the ascending ramus and condyle (Figure 1).

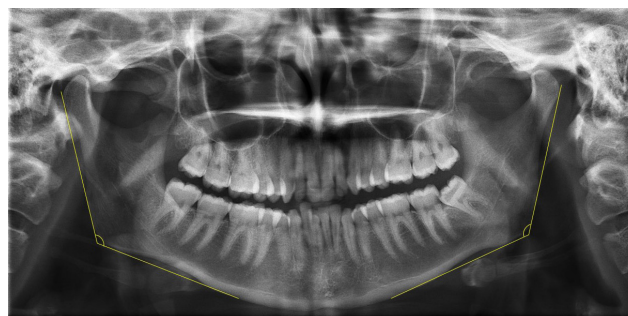


Figure 1: Gonial angle measurement on the digital panoramic radiograph

The gonial angle was measured using Digora software. Paired t-test was used for evaluating the difference between the gonial angle in the panoramic OPG, and Student t-test was used for assessing the difference in the gonial angle with respect to sex. The analyses were performed using SPSS version 22.0; a P-value of $< .05$ was considered to indicate statistical significance.

Results

Statistical Method used was descriptive and inferential statistical analysis has been carried out in the present study. Results on continuous measurements are presented on Mean \pm SD (Min-Max) and results on categorical measurements are presented in Number (%). Significance is assessed at 5 % level of significance. The following assumptions on data are made, Assumptions: 1. Dependent variables should be normally distributed, 2. Samples drawn from the population should be random, and cases of the samples should be independent. Student t test (two tailed, independent) has been used to find the significance of study parameters on continuous scale between two groups (Inter group analysis) on metric parameters. Leven's test for homogeneity of variance has been performed to assess the homogeneity of variance. Chi-square/Fisher Exact test has been used to find the significance of study parameters on categorical scale between two groups, Non-parametric setting for Qualitative data analysis. Fisher exact test used when cell samples are very small.

The study sample consisted of retrospective panoramic radiographs of 324 patients (163 females and 179 males; mean age of 29.05 ± 7.93 years as seen in Figure 2). The mean value of the gonial angle measured using the panoramic radiographs was 126.43 ± 6.42 with a standard deviation of 0.90° , The mean value of the right gonial angle measured using the OPG in females was

127.68±6.69°, and 125.64±5.91 in males; the P-value was .003. Further, the mean value of the left gonial angle was 127.23±6.86° in females, and in 125.35±6.02°

inmales; the P-value was .007. The mean gonial angle was 126.43±6.42° and the P-value was .005, which was also statistically significant (Table 1 and Figure 3).

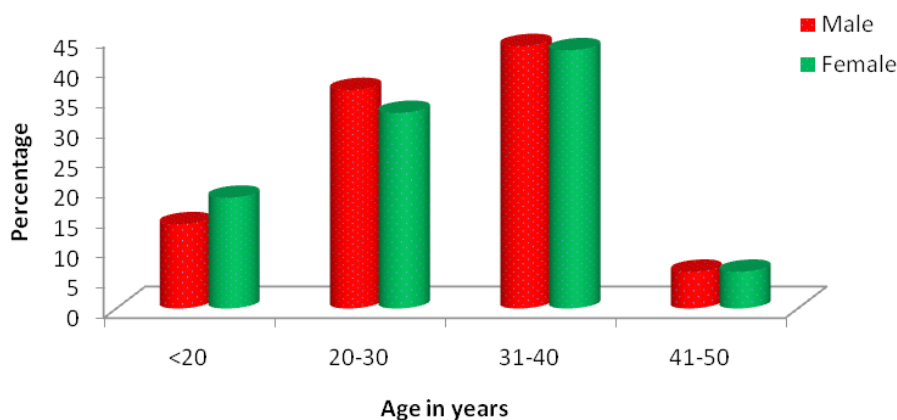


Figure 2: Age distribution of patients studied

Table 1: Comparison of Gonial Angle according to Gender

Variables	Gender		Total	P value
	Male	Female		
Right Gonial Angle	125.64±5.91	127.68±6.69	126.61±6.37	0.003**
Left Gonial Angle	125.35±6.02	127.23±6.86	126.24±6.49	0.007**
Mean Gonial angle	125.50±5.95	127.45±6.77	126.43±6.42	0.005**

Discussion

The gonial angle reflects the morphology of the mandible and has a very important role in growth pattern prediction and estimating age in forensic medicine and forensic dentistry.¹⁵ It is also an important parameter for evaluating the symmetry of the facial skeleton.^{1,2} According to Mattila et al.¹⁰ and Dahan et al,¹¹ the size of the gonial angle depends on the method of measurement used. These measurements can be formed through a line tangent to the lower border of the mandible or be based on a line passing through the gnathion. On a panoramic radiograph, the determination of the gnathion can sometimes be difficult and might result in an inaccurate measurement of the gonial angle.¹⁵ Therefore, in this study, to avoid any inaccuracies in measurement, the horizontal plane of the gonial angle in both the panoramic radiograph and the lateral cephalogram was formed by a line drawn tangentially to the lower border of the mandible.

The mean values of male and female external gonial angle measured using the panoramic radiographs were

125.50±5.95° and 127.45±6.77°, respectively. Further, statistically significant difference was observed in the gonial angle measured using this diagnostic tool. Mattila et al.¹⁰ measured the gonial angle using panoramic radiographs and lateral cephalograms, compared the values with those found using dry skulls, and concluded that the measurements made using the panoramic radiographs were more accurate. Shahabi et al.¹⁶ compared the external gonial angle determined using panoramic radiographs of patients and concluded that panoramic radiography could be used for determining the gonial angle as accurately as a lateral cephalogram. Arakiet al,¹⁷ in 2015, compared the gonial angles measured using 49 panoramic radiographs with the gonial angle estimated using lateral cephalometric radiographs taken from 2 dry mandibles and found that the gonial angle measurements were slightly smaller on the panoramic radiographs than on the lateral cephalometric radiographs. Alhaja et al.¹⁸ evaluated the potential of panoramic radiographs to measure mandibular inclination and steepness; they observed a high correlation between the measurements taken using both types of radiographs. Thus, according

to their study, panoramic radiographs are a useful tool for the measurement of the gonial angle, which is an indicator of mandibular steepness and, subsequently, the mandibular growth direction. In a previous study, the reliability of cephalometric measurements made using panoramic radiographs was compared with that of the actual measurements collected from dry skulls.¹⁷ The results recorded the highest correlation between orthopantomography and cephalometric radiograph with respect to the measurement of the gonial angle, whereas the least correlation was observed for the length of the mandibular body. Further, in the case of different growth patterns, the gonial angle and the ramus height showed the closest correlation between the 2 types of radiographs.¹⁰ Thus, the ability to determine the growth direction from a panoramic radiograph is useful because most dentists request a panoramic radiograph for patients during routine dental examinations.

In lateral cephalometric radiograph, gonial angle measured between atangent line with the inferior border of the mandible and along the posterior border of the mandibular ramus of superimposed mandibular halves. According to Nohadani and Ruf,¹⁹ angular values from panoramic radiographs are more reliable, as the angular values in the posterior and the lateral aspects of the mandible for determining the gonial angle.

Sex estimation is very important from a forensic point of view. Mandibular condyle and ramus in particular are most sexually dimorphic as they are the sites associated with the greatest morphological changes in size and remodeling during growth.²⁰ Therefore, in the present study, mandibular ramus was selected for sex estimation as it is a part of gonial angle.

As regards the gonial angle, males showed statistically significant lower mean gonial angle values than females (125.50 ° and 127.45 ° respectively). This was in agreement with many researchers.^{21,22,23} Conversely, other researchers found that males showed statistically significant higher mean gonial angle values than females,²⁴ whereas others did not find any statistically significant differences between both sexes.^{16,25} It was found that females had a downward and backward rotation pattern in mandible while males had a forward rotation in mandible therefore the gonial angle values found in females are higher than in males.²⁶

To sum up, our results support previous research on other populations that the gonial angle showed a sexual

dimorphism and proved to be beneficial in sex estimation and Hence, the use of gonialangle is recommended as an aid for sex estimation in forensic analysis. However, further studies using larger sample size from diverse Saudi Arabian regions and different imaging modalities are recommended to set our population standards for sex estimation.

Conclusion

In the present study, statistically significant difference was observed between the gonial angles measured in between males and females using panoramic radiographs. Panoramic radiography can be considered reliable for measuring the gonial angle. In the selected Saudi Arabia population sample, the gonial angle showed a high sexual dimorphism and proved to be beneficial in sex estimation.

Conflicts of Interest: The author declare that there is no conflict of interest regarding the publication of this paper.

Source of Funding: Self

Ethical Clearance: Ethical clearance has been taken from Institutional Ethical Committee

References

1. Graber TM. Panoramic radiography in orthodontic diagnosis. *Am J Orthod* 1967; 53: 799-821.
2. Chole RH, Patil RN, Balsaraf Chole S, Gondivkar S, Gadbail AR, et al. Association of mandible anatomy with age, gender, and dental status: a radiographic study. *ISRN Radiol* 2013; 453763.
3. Fischer-Brandies H, Fischer-Brandies E, Dielert E. The mandibular angle in orthopantomogram. *Radiologe* 1984; 24: 547- 9.
4. Upadhyay RB, Upadhyay J, Agrawal P, Rao NN. Analysis of gonial angle in relation to age, gender and dentition status by radiological and anthropometric method. *J Forensic Dent Sci* 2012; 4: 29-33.
5. Larheim TA, Svanaes DB. Reproducibility of rotational panoramic radiography: mandibular linear dimensions and angles. *Am J Orthod Dentofacial Orthop* 1986; 90: 45-51.
6. Mattila M, Könönen M, Mattila K. Vertical asymmetry of the mandibular ramus and condylar heights measured with a new method from dental

- panoramic radiographs in patients with psoriatic arthritis. *J Oral Rehabil* 1995; 22: 741-5.
7. McDavid WD, Tronje G, Welander U, Morris CR. Effects of errors in film speed and beam alignment on the image layer in rotational panoramic radiography. *Oral Surg Oral Med Oral Pathol* 1981; 52: 561-4.
 8. Yeo DK, Freer TJ, Brockhurst PJ. Distortions in panoramic radiographs. *Aust Orthod J* 2002; 18: 92-8.
 9. Slagsvold O, Pedersen K. Gonial angle distortion in lateral head films: a methodologic study. *Am J Orthod* 1977; 71: 554- 64.
 10. Mattila K, Altonen M, Haavikko K. Determination of the gonial angle from the orthopantomogram. *Angle Orthod* 1977; 47: 107-10.
 11. Dahan J, Jesdinsky HJ. Evaluation of the orthopantomogram for cephalometric studies in orthodontics. *Stoma (Heidelb)* 1968; 21: 200-6.
 12. Indira AP, Markande A, David MP. Mandibular ramus: An indicator for sex determination - A digital radiographic study. *J Forensic Dent Sci* 2012; 4: 58-62.
 13. Hu KS, Koh KS, Han SH, Shin KJ, Kim HJ. Sex determination using nonmetric characteristics of the mandible in Koreans. *J Forensic Sci* 51 2006: 1376- 1382.
 14. Samatha K, Byahatti SM, Ammanagi RA, Tantradi P, Sarang CK, Shivpuje P. Sex determination by mandibular ramus: A digital orthopantomographic study. *J Forensic Dent Sci* 2016;8:95-8
 15. Radhakrishnan PD, Sapna Varma NK, Ajith VV. Dilemma of gonial angle measurement: Panoramic radiograph or lateral cephalogram. *Imaging Sci Dent.* 2017;47(2):93–97.
 16. Shahabi M, Ramazanzadeh BA, Mokhber N. Comparison between the external gonial angle in panoramic radiographs and lateral cephalograms of adult patients with Class I malocclusion. *J Oral Sci* 2009; 51: 425-9.
 17. Araki M, Kiyosaki T, Sato M, Kohinata K, Matsumoto K, Honda K. Comparative analysis of the gonial angle on lateral cephalometric radiographs and panoramic radiographs. *J Oral Sci* 2015; 57: 373-8.
 18. Alhaija ES. Panoramic radiographs: determination of mandibular steepness. *J Clin Pediatr Dent* 2005; 29: 165-6.
 19. Nohadani N, Ruf S. Assessment of vertical facial and dentoalveolar changes using panoramic radiography. *Eur J Orthod* 2008; 30: 262-8.
 20. Vodanovic M, Dumancic J, Demo Z, Mihelic D. Determination of sex by discriminant function analysis of mandibles from two Croatian archaeological sites. *Acta Stomatol Croat* 2006; 40: 263-277.
 21. Xie QF, Ainamo A. Correlation of gonial angle size with cortical thickness, height of the mandibular residual body, and duration of edentulism. *J Prosthet Dent* 2004; 91: 477-482.
 22. Taleb NSA, Beshlawy ME. Mandibular Ramus and Gonial Angle Measurements as Predictors of Sex and Age in an Egyptian Population Sample: A Digital Panoramic Study. *J Forensic Res* 2015; 6: 308.
 23. Dutra V, Yang J, Devlin H, Susin C. Mandibular bone remodelling in adults: evaluation of panoramic radiographs. *Dentomaxillofac Radiol* 2004; 33: 323-328.
 24. Kharoshah MA, Almadani O, Ghaleb SS, Zaki MK, Fattah YA. Sexual dimorphism of the mandible in a modern Egyptian population. *J Forensic Leg Med* 2010; 17: 213-215.
 25. Al-Shamout R, Ammouh M, Alrbata R, Al-Hababeh A. Age and gender differences in gonial angle, ramus height and bigonial width in dentate subjects. *Pakistan Oral & Dental Journal* 2012; 32: 81-87.
 26. Fudalej P, Artun J. Mandibular growth rotation effects on postretention stability of mandibular incisor alignment. *Angle Orthod* 2007;77:199-205.