

Post Covid-19 Effect on Avascular Necrosis of Hip Joint

Ashok Kumar Jha¹, Vishal Sidhu²

¹Associate Professor, ²Assistant Professor, Department of Orthopaedics, Venkateshwara Institute of Medical Sciences, Gajraula.

How to cite this article: Ashok Kumar Jha, Vishal Sidhu. Post Covid-19 Effect on Avascular Necrosis of Hip Joint. Indian Journal of Public Health Research and Development/Volume 15 No. 1, January-March 2024.

Abstract

Background and objectives: The exact course of Severe acute respiratory syndrome (SARS) -2(COVID-19) and its complications on multiorgan system are complex and still under studies. Musculoskeletal system has also been affected post covid in various forms. This study was taken up to analyse the effects of covid-19 disease on the hip bone and joint tissue.

Materials and Methods: Retrospective analysis of ten patients was done who had been hospitalised with covid-19 infection and later complained of hip pain . They underwent MR imaging and were found to have degenerative changes characterizing with avascular necrosis (AVN) of head of femur .One of them had history of previous surgery of femur with PFN, doing well but developed AVN after COVID .

Results: Observation of this group showed a clear correlation among the history of COVID-19 disease in the patients, moderately severe symptoms, high levels of IgG antibodies, and the time of occurrence of joint changes. No other risk factors for AVN or autoimmune or degenerative diseases were found in the study group. The group of patients responded well to empirical treatment with anti-inflammatory drugs and supportive therapy, which subsided acute inflammatory symptoms and pain in the joints.

Conclusions: It is concluded that there have been obvious musculoskeletal complications in covid patients including AVN which could be attributed to the high use steroids and microembolism leading to bone necrosis. Hence more studies and long follow-up is suggested.

Keywords: avascular necrosis bone, osteonecrosis, SARS-CoV-2 infections, corticosteroids

Introduction

The coronavirus 2 (SARS-CoV-2) (COVID-19) pandemic has stimulated an unprecedented response by the global scientific community to better understand the disease. However, many questions about SARS-CoV-2 remain unanswered. Various hypotheses have been formulated in regard to its pathogenetic mechanisms and treatment ^[1]. A

plethora of reports on the long-term consequences of the infection, which also include the musculoskeletal system, have been published ^[2].

Systemic inflammation may play a role in the physiology of bone and joint tissue in COVID-19 patients. Cytokines that are induced by COVID-19 include CXCL10, IL-17, and TNF-alpha. They are responsible for reducing the proliferation and differentiation of osteoblasts.

Corresponding Author: Ashok Kumar Jha, Associate Professor, Department of Orthopaedics, Venkateshwara Institute Of Medical Sciences, Gajraula.

Mobile No.: 8057421180

E-mail: Aosp1011@Gmail.Com

Corticosteroids administered to most patients treated for COVID-19 in hospital also have an adverse effect on bone tissue [3,4].

In addition, single nucleotide polymorphisms in various genes encode for proinflammatory proteins, such as IL-1b, IL-6 and IL-8, which may affect biological activity and contribute to hypercoagulability in COVID-19 patients, thereby increasing the risk of bone necrosis [5]. The combination of hypercoagulability, leukocyte aggregation and vasculitis can impair blood flow in the blood vessels of the bone and contribute to the development of bone necrosis [5].

Material and Methods

After clearance from institutional review board of the institution, a retrospective analysis of a case series was taken up to study effects of covid-19 infection on hip bone and tissues. Study group included the patients hospitalised during active covid disease

from 2020-2022 and those who complained of hip disorders, selection was made based on inclusion and exclusion criteria.

Inclusion criteria: PCR indicating positive COVID-19 infection and joint pain during the course of the disease and follow up.

Exclusion criteria: prior injury to the affected joint, prior treatment with steroids, and patients with autoimmunity.

The study included a group of ten patients who developed pain and dysfunction around hip joint, were diagnosed as avascular bone necrosis in COVID-19 on MR images [6].

The criterion for classifying the severity of COVID-19 infection was defined according to a 4-point scale: mild, moderate, severe and critical (Table 1) [7]

Table 1: Characteristics of patients.

Patient No.	Age	Sex	Chronic Diseases	Severity of COVID-19	COVID-19 Therapy/Steroids
1	62	M	DM	severe	no
2	56	M	DM	mild	no
3	57	F	no	severe	yes
4	70	F	no	moderate	no
5	43	F	Hypertension	moderate	yes
6	54	M	Depression	moderate	yes
7	66	F	no	moderate	no
8	39	F	no	severe	yes
9	68	F	no	mild	no
10	24	M	no	moderate	no
mean	58.8				
SD	11.3				

The examined group of patients had not previously received any treatment for diseases of the musculoskeletal system (e.g., steroids), did not suffer from significant injuries or did not suffer from significant joint pain.

All the patients had a mean IgG and IgM COVID-19 antibody titer corresponding to the typical course of COVID-19 infection. Basic immunohistochemical tests were performed in all patients to rule out autoimmune diseases. HLA-B27 was negative in all patients. The examination of the

synovial fluid in all patients revealed changes in the characteristics of aseptic arthritis.

The MRI consisted of (fat suppressed)-T2, pre- and postgadolinium T1-weighted imaging.

The MR images demonstrated bone lesions characteristic of AVN:

- T1 FSE: the initial specific findings are areas of low signal representing edema, which can be bordered by a hyperintense line, which represents blood products;

- T2 FR FSE: This may show a second hyperintense inner line between normal marrow and ischemic marrow. This appearance is highly specific for AVN of the hip and is known as the “double line sign”.

Avascular bone necrosis was described using the Steinberg classification. The described changes also included subchondral infarctions with the involvement of articular cartilage (grade III) [8].

Statistical Analysis

Statistical analyses and data processing were performed using SAS/STAT version 14.3 (SAS Institute, Cary, North Carolina, USA) to determine the association between various comorbidities, ICU stay, mortality, and the orthopedic manifestations of COVID-19 patients. The frequencies of cohort demographics and descriptive statistics were calculated and analyzed using Pearson’s chi squared test, the likelihood ratio, and the NPAR1WAY procedure (ANOVA) as appropriate. The critical value for significance was set at <0.05 for all statistical tests.

Results

The mean age of the patients was 61 years with six women and four men were included. Out of ten, 6 were right and 4 were left sided.

The course of infection was mild in three patients, moderate in five and severe in two patients. Four patients were treated with steroid therapy (6mg/day dexaven).

Clinical signs and symptoms of musculoskeletal occurred 7 to 22 days from onset of infection (mean 14 days) and appeared 5–10 days (mean 6 days) after the resolution of acute respiratory symptoms and elevated body temperature.

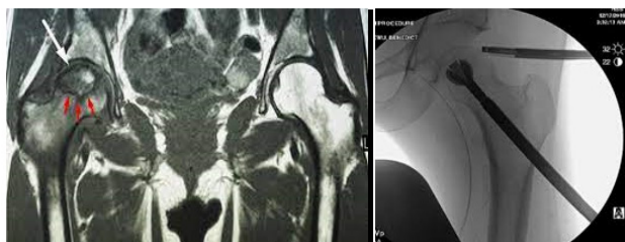Patients were initially treated conservatively: non-steroidal anti-inflammatory drugs (NSAIDs), intra-articular steroid injections and therapeutic aspiration of the synovial fluid were implemented. There was no significant improvement.

Steroid therapy in mild doses was supplemented with an oral dose of dexamethasone 2 × 8 mg daily for a period of 2 weeks.

Finally, 3 out of 10 persons required arthroplasty and showed a good clinical outcome. Four patients underwent core-decompression surgery and improved. One patient had chronic pain in the affected joint and is currently being treated conservatively; destruction of the joint surface was not shown in the control tests. In the remaining six people, there was no deviation in the control test follow up (Table 2).

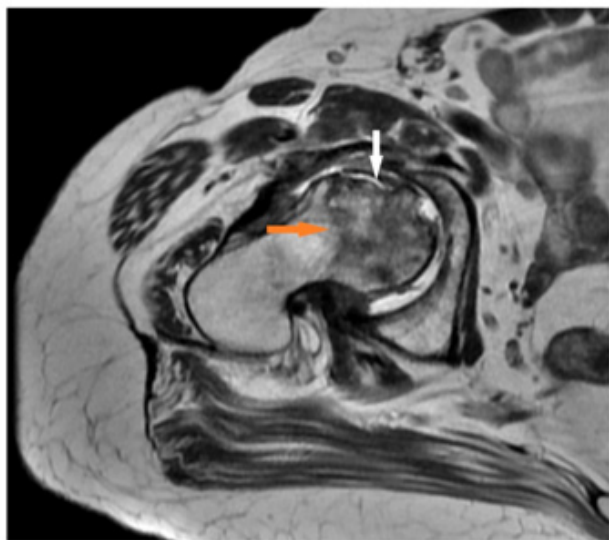
Table 2: Characteristics of joint lesions in patients with COVID-19.

No.	Joint	Time of Onset of Joint Symptoms from the Beginning of Infection	decompression	Steinberg Scale	Follow-Up (Months)	VAS Pain Initially	Pain Follow Up VAS
1	hip	11		4	10	8	2
2	Hip	10	Decompression	2	9	9	0
3	Hip	11	Decompression	2	7	6	0
4	Hip	7	Decompression	4	7	8	0
5	hip	21		2	8	7	1
6	Hip	17		3	10	8	0
7	Hip	14		2	8	8	1
8	Hip	14	Decompression	2	5	8	1
9	Hip	22		2	5	7	0
10	hip	17		4	4	8	0
mean		14		3	7	8	0,5



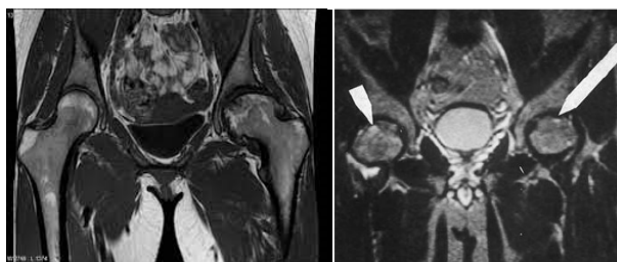
Case 1 (Patient No. 5)

Figure 1: A control magnetic resonance imaging was performed, which did not reveal any significant deviations from the norm



Case 2 (Patient No. 1)

Figure 2: Aseptic necrosis of the femoral head was visualized with the destruction of the articular surface and deformation of the femoral head



Case 3 (Patient No. 7)

Aseptic necrosis of the femoral head was visualized with the destruction of the articular surface and deformation of the femoral head

Figure 3: deformation of the femoral head figure: after HBOT

Discussion

Complications following COVID-19 infection are the focus of numerous clinical trials. Pathological changes following COVID-19 infection have also been described in the locomotor system. In our study, the formation of changes within the hip, with a background of AVN, was observed among the group of patients.

A similar etiology of vascular and embolic changes over the course of COVID-19 infection has also been described in organs outside of the respiratory system, such as multiorgan failure, acute cardiac injury, cerebrovascular diseases, acute kidney injury, liver dysfunction, and venous thrombosis [9]. Undoubtedly, exacerbation of underlying diseases by SARS-CoV-2 infection also tends to worsen bone metabolism [10].

ACE2 deficiency, caused by viral invasion, can lead to bone matrix degradation. Given that coronaviruses cause pneumonia and infection of the upper respiratory tract via ACE2 receptors in ATII cells, ACE2-dependent effects on bone tissue should also be noted. ACE2 is a potential factor that regulates bone biology during COVID-19 infection [11].

Bone complications from infections or treatments are likely to emerge in the next few months, similar to the SARS outbreak in 2002–2003. At that time, reports of joint pain, decreased bone mineral density (BMD), and necrosis of femurs and tibias could only be partially explained by high-dose steroid treatment. Another in vitro study showed that the specific SARS-CoV protein, 3a/X1, directly promotes osteoclastogenesis, thereby accelerating osteoclast differentiation from monocyte/macrophage precursors and increasing the expression of the NF- κ B ligand receptor activator (RANKL) and inflammatory cytokines, such as TNF- α , which indirectly promote osteoclastogenesis [12].

This study observed people with symptoms of AVN after a history of COVID-19 without steroid therapy. The first symptoms appeared on average 14 days (range 7–22 days) after infection. Probably in our patient group, steroid therapy did not directly influence the development of AVN. One study reported that symptoms of AVN appeared 58 days (range 45–67 days) after infection with

COVID-19. However, the risk of AVN after steroid therapy ranges from 6 months to 1 year. There is a lack of consensus about the dose and duration of corticosteroid treatment as a risk factor for developing AVN. One prospective study found that the risk of AVN increases significantly with the dose of >20 mg/day. Our patients used 6 mg/day. COVID-19 disease appears to be an independent risk factor for AVN and possibly accelerates the risk of AVN after a history of COVID-19 treated with steroid therapy.

In the case of COVID-19, corticosteroids were primarily considered as a way to contain this "cytokine storm" and its aftermath: ARDS, disseminated intravascular coagulation, and shock. This usually occurs within the first 8–15 days of infection. Treatment with steroids is attempted, especially at the onset of dyspnea, or even earlier, to prevent the progression of the "cytokine storm". The anti-inflammatory properties of corticosteroids reduce systemic inflammation and exudates in the lung tissues, and prevent further diffuse alveolar damage, thereby improving hypoxia and minimizing the risk of respiratory failure. Most of the studies on the use of corticosteroids to treat COVID-19 have shown variable results, but this is mainly due to a marked heterogeneity in the research methodology.

In the examined group of patients, no risk of bone changes in relation to the general condition of the patient and the severity of the course of COVID-19 disease was observed. For four patients of our observed group, the occurrence of AVN, with the consequent destruction of the articular surface and permanent changes (joint damage), was observed. These patients were treated with core decompression in relation to their hip joints. In the remaining seven patients, complete remission of the changes was observed after the steroid drugs, without permanent sequelae. However, the long-term consequences of bone changes over the course of COVID-19 are not known, as our observation period did not exceed several months.

AVN is a known complication after steroid treatment of severe COVID-19 infections or in long COVID-19 infections. We described 10 cases who suffered from AVN shortly after a COVID-19 infection without prior steroid treatment. Apparently, COVID-19 infection alone may represent a risk factor

for developing AVN. On average, AVN begins 2 weeks after COVID-19 onset in contrast to long COVID-19 late-onset AVN. However it may vary.

Conclusion

SAR-CoV-2 can affect bones presenting with symptoms 2–3 weeks after infection. This may resolve with medical management or result in end stage AVN that may responds well to core decompression or hip arthroplasty. After effects of covid-19 infection over this human body are complex including musculoskeletal system. Further, long term studies are suggested to have a better understanding of the disease.

Informed Consent: written informed consent was taken from patients.

Ethical Approval: ethical committee approval was taken from the Institutional Committee Of Ethics, VIMS (VIMSE/2022/11-93) .

Source of Funding: funding source was self

Conflict of Interest: there was no conflict of interest

References

1. Disser NP, De Micheli AJ, Schonk MM, Konnaris MA, Piacentini AN, Edon DL, Toresdahl BG, Rodeo SA, Casey EK, Mendias CL. Musculoskeletal consequences of COVID-19. *The Journal of bone and joint surgery. American volume*. 2020 Jul 7;102(14):1197.
2. Yang X, Yu Y, Xu J, Shu H, Liu H, Wu Y, Zhang L, Yu Z, Fang M, Yu T, Wang Y. Clinical course and outcomes of critically ill patients with SARS-CoV-2 pneumonia in Wuhan, China: a single-centered, retrospective, observational study. *The lancet respiratory medicine*. 2020 May 1;8(5):475-81.
3. Yang X, Yu Y, Xu J, Shu H, Liu H, Wu Y, Zhang L, Yu Z, Fang M, Yu T, Wang Y. Clinical course and outcomes of critically ill patients with SARS-CoV-2 pneumonia in Wuhan, China: a single-centered, retrospective, observational study. *The lancet respiratory medicine*. 2020 May 1;8(5):475-81.
4. Shen J, Liang BL, Zeng QS, Chen JY, Liu QY, Chen RC, Zhong NS. Report on the investigation of lower extremity osteonecrosis with magnetic resonance imaging in recovered severe acute respiratory syndrome in Guangzhou. *Zhonghua Yi Xue Za Zhi*. 2004 Nov 1;84(21):1814-7.

5. Griffith JF. Musculoskeletal complications of severe acute respiratory syndrome. In *Seminars in musculoskeletal radiology* 2011 Nov (Vol. 15, No. 05, pp. 554-560). © Thieme Medical Publishers.
6. Glickstein MF, Burk Jr DL, Schiebler ML, Cohen EK, Dalinka MK, Steinberg ME, Kressel HY. Avascular necrosis versus other diseases of the hip: sensitivity of MR imaging. *Radiology*. 1988 Oct;169(1):213-5.
7. Verity R, Okell LC, Dorigatti I, Winskill P, Whittaker C, Imai N, Cuomo-Dannenburg G, Thompson H, Walker PG, Fu H, Dighe A. Estimates of the severity of coronavirus disease 2019: a model-based analysis. *The Lancet infectious diseases*. 2020 Jun 1;20(6):669-77.
8. Verity R, Okell LC, Dorigatti I. Estimates of the severity of coronavirus disease 2019: a model-based analysis (vol 20, pg 669, 2020).
9. Li K, Huang B, Wu M, Zhong A, Li L, Cai Y, Wang Z, Wu L, Zhu M, Li J, Wang Z. Dynamic changes in anti-SARS-CoV-2 antibodies during SARS-CoV-2 infection and recovery from COVID-19. *Nature communications*. 2020 Nov 27;11(1):1-1.
10. Ahmad I, FA R. Manifestaciones neurológicas y complicaciones de COVID-19: revisión de la literatura. *J. Clin. Neurosci*. 2020;77:8-12.
11. Zacharias H, Dubey S, Koduri G, D'Cruz D. Rheumatological complications of Covid 19. *Autoimmunity reviews*. 2021 Sep 1;20(9):102883.
12. Aghagoli G, Gallo Marin B, Soliman LB, Sellke FW. Cardiac involvement in COVID-19 patients: Risk factors, predictors, and complications: A review. *Journal of cardiac surgery*. 2020 Jun;35(6):1302-5.