

## Cytohistological Evaluation of Unusual Male Breast lesions: A Case Series from a Tertiary Care Centre

Madhumita Paul<sup>1</sup>, Manisha Mahata<sup>2</sup>, Sajeeb Mondal<sup>3</sup>,  
Rajashree Pradhan<sup>4</sup>, Bidisha Chakraborty<sup>5</sup>

<sup>1</sup>Senior Resident (Demonstrator), <sup>2</sup>Assistant Professor, <sup>4</sup>Associate Professor, <sup>5</sup>Senior Resident, Department of Pathology, College of Medicine & Sagore Dutta Hospital, <sup>3</sup>Associate Professor, Department of Pathology, Rampurhat Government Medical College & Hospital.

**How to cite this article:** Madhumita Paul, Manisha Mahata, Sajeeb Mondal et. al. Cytohistological Evaluation of Unusual Male Breast lesions: A Case Series from a Tertiary Care Centre. Indian Journal of Public Health Research and Development/Volume 15 No. 1, January-March 2024.

### Abstract

**Introduction:** Pathologic lesions of male breast are not as common as its female counterpart.

In this study we have reported six cases of unusual pathological lesions of male breast presenting clinically as breast lump studied by Fine Needle Aspiration Cytology (FNAC) with histologic correlation.

**Method:** 6 male patients were studied who presented to us with breast lump and had FNAC done with subsequent histopathological correlation.

**Result:** Out of 6 cases, 3 were fibromatosis (desmoid-type), 2 cases of invasive carcinoma involving both breasts with axillary lymph node metastasis and 1 case of complex fibroadenoma were reported. In all of the above cases definitive diagnosis was given on FNAC with subsequent histopathological confirmation except for fibromatosis in which the diagnosis was benign breast lesion on FNAC.

**Conclusion:** FNAC being a fast and cheap diagnostic tool proves to be a reliable diagnostic method for evaluation of breast lumps at an earliest with excellent histologic reproducibility.

**Keywords:** Complex fibroadenoma, Fibromatosis, FNAC, Male breast lumps.

### Introduction

Pathologic lesions of male breast are not as common as its female counterpart. Majority of the lesions are gynecomastia and carcinomas. Other rare lesions include fibroepithelial tumors, papilloma, duct ectasia and others.<sup>5</sup> Prevalence of gynecomastia varies from 32% to 65% in respective age groups.<sup>2</sup> Carcinomas rarely occur in male breasts,

approximately 1% of all malignancies in men. Since, clinically it resembles gynecomastia & other benign lesions, urgent identification & discrimination of these two contrasting pathological entities is warranted.<sup>1</sup> Although, open surgical biopsy is the gold standard diagnostic procedure for palpable lesions, in recent times FNAC & CNB, both have become established diagnostic tool for evaluation of palpable breast lesions.<sup>12</sup> FNAC is a cheap, fast and

---

**Corresponding Author:** Rajashree Pradhan, Associate Professor, Department of Pathology, College of Medicine & Sagore Dutta Hospital.

**Mobile:** 7980217205

**E-mail:** pradhanrajashree99@gmail.com

---

reliable diagnostic tool that provides prompt and precise diagnosis economically & conveniently.<sup>13,9</sup>

Thus, with this study we aim to cytologically evaluate various pathological lesions affecting male breasts and then to validate its diagnostic accuracy with their respective histopathological diagnosis.

### Materials and Methods

1. Place of Study: Department of Pathology, CMSDH, Kolkata
2. Inclusion Criteria: Male patients presented with palpable breast lump are included in the study
3. In this case series, FNAC of the breast lump followed by core needle biopsy and histopathological study were done.

FNAC smears were stained with Leishman and Pap stain

Histopathology sections were stained with H&E and were examined under light microscope.

### Findings

#### Case 1

62 years male patient presented with a firm lump in the left breast measuring 4cm x 3cm, gradually increasing in size for last 2 years with restricted mobility.

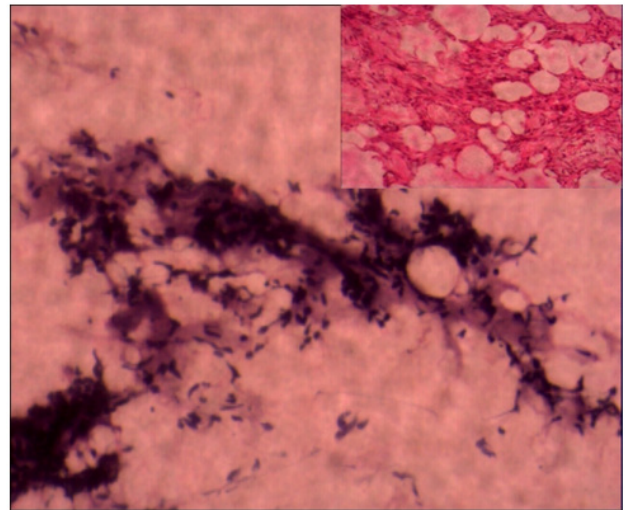
#### Case 2

Our second case was a 25 year old boy presenting with an ill-defined, firm, diffuse sub-areolar lump measuring 2.5cm x 2cm in the left breast for 3 months.

#### Case 3

Third case was a 67-year-old male presenting with a firm, button-like swelling in the left breast measuring 2cm x 2cm for 1 month.

FNAC of the above three cases showed small clusters of ductal epithelial cells showing mild to moderate atypia along with bland spindle-shaped cells with hyperchromatic nuclei in an abundant fibrofatty stroma. Scattered inflammatory cells are seen in the background. Diagnosis was given as benign breast lesion possibly Gynecomastia. (Figure 1)



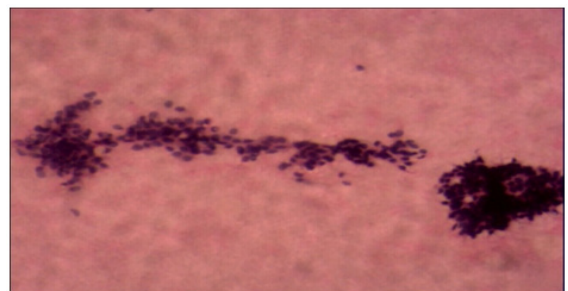
**Fig 1 showing cytology & histopathology (inset) of Desmoid (Fibromatosis) (H&E, Low power)**

However, considering the cellular atypia and abundant fibrofatty stroma in the background, urgent biopsy and histopathology study was suggested.

Lumpectomy was received which on histopathological examination showed long, sweeping and intersecting fascicles of bland spindle cells. Focal areas showed mild nuclear atypia. Highly collagenous areas were also seen. The peripheral margin was infiltrative with presence of adipose tissue trapping and collagen trapping. Few lymphoid aggregates forming follicles were seen at the periphery. To one side of the tumor, there was presence of compressed TDLU. No evidence of any malignancy was noted. Diagnosis was given as **Fibromatosis (desmoid-type)** of male breast. (Figure 1, inset)

#### Case 4

Our fourth case was a 49-year-old male patient presenting with a firm lump measuring 6cm x 5cm in the retro-areolar region of the right breast.



**Figure 2a: FNAC smear of Proliferative Breast Disease (Low power, H&E)**

FNAC report was given as Proliferative breast disease (Figure 2a) with cystic apocrine change and focal atypia.

However, urgent biopsy and histopathology study was suggested for confirmation and categorization.

Core-needle biopsy showed apocrine papillary cystic lesion with underlying stromal Osseo fibrous metaplasia.

Lumpectomy specimen was received and histopathological examination (Figure 2b) was done which showed features of fibroadenoma admixed with features of papillary apocrine hyperplasia and cysts >3mm in size. Final diagnosis was given as **Complex Fibroadenoma**.

### Case 5 & 6

Our fifth case was a 55 years male presenting with a hard lump measuring 5cm x 4cm in the left breast and fixed to the overlying skin & hard swelling involving the right breast measuring of 3cm x 2 cm in size.

Our sixth case was a 65 years old male presenting with a hard lump measuring 3.5cm x 4cm in the left breast and multiple hard swellings with skin ulceration and fixed to the underlying structures.

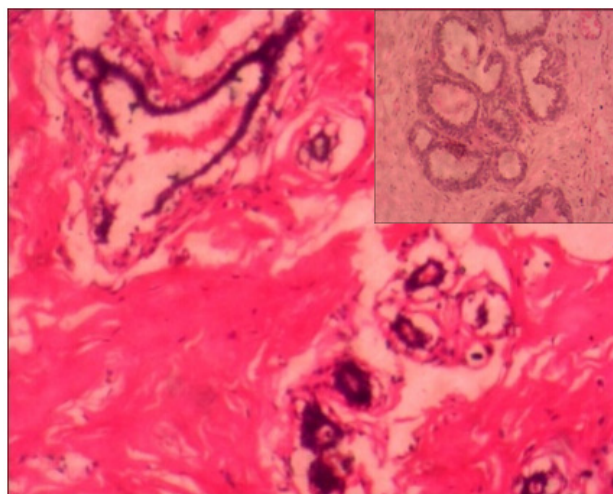
In both the cases there is axillary lymph nodes enlargement.

FNAC smears from both the cases showed moderate cellularity with clusters of atypical cells. Cells had high N:C ratio, moderate amount of cytoplasm and irregular nuclear margin. Smears from axillary lymph nodes show metastatic deposits. Cytology report was given as invasive breast carcinoma with axillary lymph node metastasis. (Figure 3, inset) Advice for urgent biopsy & histopathological examination for confirmation and categorization were given.

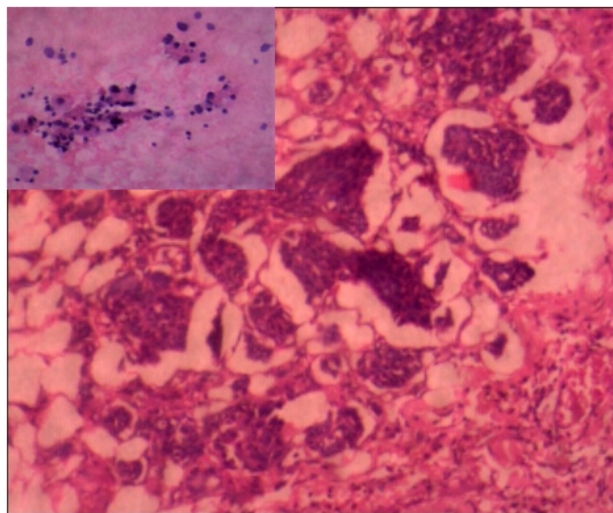
We had received modified radical mastectomy (MRM) specimens of both the cases for histopathological examination.

Sections from the growth in both the cases showed highly pleomorphic ductal epithelial cells arranged predominantly in solid and nested pattern

with variable mitoses. Areas of come do-necrosis seen. The surrounding stroma showed marked fibrosis and elastic tissue deposition. Lympho-vascular invasion was present. Diagnosis was given as **Invasive carcinoma of breast-No Special type**. (IC NST), Histological grade -2 in both the cases, & pathological stage **P<sup>TNM</sup> (P<sup>T2</sup>N<sup>1</sup>M<sup>X</sup>)**. (Figure 3)



**Figure 2b: Histological sections showing fibrocystic change, apocrine metaplasia (lower inset) & gynaecomastia (upper inset) (Low power, H&E)**



**Figure 3: Cytology (inset) & histopathology of carcinoma breast (H&E, Low power)**

### Discussion

FNAC of breast is a common diagnostic tool which is used as a part of the diagnostic triad that includes clinical breast examination and radiological evaluation (ultrasonography & mammography) in addition to FNAC. The diagnostic accuracy is close

to 100% when all three modalities favor a benign or malignant disease.<sup>14</sup>

In this case series, we have described spectrum of male breast lesions diagnosed by FNAC. We have reported 6 cases of male breast pathology.

Our first 3 cases were **Fibromatosis (desmoid-type)** of male breast. It is a locally infiltrative lesion without metastatic potential.<sup>11</sup> Mammary fibromatosis is rare with an incidence of 0.2% that of mammary carcinoma.<sup>3</sup> It occurs at a wide range of ages and is much more common in females. Women are diagnosed twice as often compared to men which gives a clue to a role of hormonal influence.<sup>8</sup> In contrast, case of male breast fibromatosis diagnosed in FNAC is relatively uncommon in the literature. There are only 8 reported cases of male breast fibromatosis in literature.<sup>7</sup> Since the condition is very rare, so its diagnosis and treatment are especially very challenging in affected male patients. Once the suspicion of fibromatosis is raised in FNAC, treatment typically includes surgical excision with wide margins since fibromatosis is locally aggressive and recurrences have been associated with positive surgical margins.

Immunohistochemically,  $\beta$ -catenin has been identified as a specific marker for breast desmoid-type fibromatosis which shows nuclear expression in sporadic and familial cases in 80% patients. Combination of positive  $\beta$ -catenin and negative CD34 markers support the diagnosis of fibromatosis.<sup>8,6</sup>

Our fourth case was diagnosed as complex fibroadenoma. Complex fibroadenomas are a sub-type of fibroadenoma which are bigger in size and tends to occur in older patients (median age-47 years). They have slightly increased risk of breast cancer in comparison to simple fibroadenomas.

They usually present with one or more of the following features:

- a) Papillary apocrine metaplasia
- b) Sclerosing adenosis
- c) Cysts measuring >3mm
- d) Epithelial calcifications

The fifth and sixth case were that of bilateral breast carcinoma with axillary lymph node metastasis.

Out of this one case was presented with multifocal nodules in the breast.

Breast malignancies of male breast comprises of 0.5%-1% of all breast malignancies in both sexes and is responsible for <0.1% of men dying from any malignancy.<sup>15</sup> Earlier studies on male breast pathologies revealed 2.5%-28.4% cases to be of malignant nature.<sup>10,4</sup> Invasive carcinoma-No Special Type is the most common male breast malignancy representing 85% of the cases followed by papillary carcinoma.

Male breast cancers are more aggressive with frequent bilateral breast involvement and multiple ipsilateral and contralateral axillary lymph node deposit. Prompt and early diagnosis is very much helpful for better patient management and clinical outcome.

## Conclusion

To conclude, in this case series we have emphasized the utility of fine needle aspiration cytology (FNAC) for evaluation of male breast lesions pre-therapeutically for differentiation between the benign and malignant lesions at the earliest for better patient management with the advantage of few manageable complications of the FNAC procedure and which can be done on outpatient basis.

**Conflict of Interest-** Nil

**Source of Funding** - No financial support received

**Ethical Clearance:** Our study was approved by institutional ethics committee. Written informed consent was taken from all the male patients participating after providing proper explanation of the procedure.

## References

1. Chikaraddi SB, Krishnappa R, Deshmane V. Male breast cancer in Indian patients: is it the same? *Indian J Cancer*. 2012 Jul-Sep;49(3):272-6. doi: 10.4103/0019-509X.104484. PMID: 23238143.
2. Cuhaci N, Polat SB, Evranos B, Ersoy R, Cakir B. Gynecomastia: Clinical evaluation and management. *Indian J Endocrinol Metab*. 2014 Mar;18(2):150-8. doi: 10.4103/2230-8210.129104. PMID: 24741509; PMCID: PMC3987263.

3. Dunne B, Lee AH, Pinder SE, Bell JA, Ellis IO. An immunohistochemical study of metaplastic spindle cell carcinoma, phyllodes tumor and fibromatosis of the breast. *Hum Pathol.* 2003 Oct;34(10):1009-15. doi: 10.1053/s0046-8177(03)00414-3. PMID: 14608534.
4. Hoda RS, Arpin Iii RN, Gottumukkala RV, Hughes KS, Ly A, Brachtel EF. Diagnostic Value of Fine-Needle Aspiration in Male Breast Lesions. *Acta Cytol.* 2019;63(4):319-327. doi: 10.1159/000494486. Epub 2019 Mar 22. PMID: 30904908.
5. Kalhan S, Dubey S, Sharma S, Dudani S, Preeti, Dixit M. Significance of nuclear morphometry in cytological aspirates of breast masses. *J Cytol.* 2010 Jan;27(1):16-21. doi: 10.4103/0970-9371.66694. PMID: 21042529; PMCID: PMC2964849.
6. Kuba MG, Lester SC, Giess CS, Bertagnolli MM, Wieczorek TJ, Brock JE. Fibromatosis of the Breast: Diagnostic Accuracy of Core Needle Biopsy. *Am J Clin Pathol.* 2017 Sep 1;148(3):243-250. doi: 10.1093/ajcp/aqx065. PMID: 28821190.
7. Kulshreshtha A, Wan BA, Drost L, et al. Presentation and Diagnosis of Desmoid Tumours (Fibromatosis) in the Male Breast: A Case Report. *Ann Breast Cancer Ther.* 2017 Nov; 1(1):18-20. doi: 10.36959/739/518
8. Lorenzen J, Cramer M, Buck N, Friedrichs K, Graubner K, Lühr CS, Lindner C, Niendorf A. Desmoid Type Fibromatosis of the Breast: Ten-Year Institutional Results of Imaging, Histopathology, and Surgery. *Breast Care (Basel).* 2021 Feb;16(1):77-84. doi: 10.1159/000507842. Epub 2020 May 28. PMID: 33708054; PMCID: PMC7923936.
9. Rosa M, Masood S. Cytomorphology of male breast lesions: diagnostic pitfalls and clinical implications. *Diagn Cytopathol.* 2012 Feb;40(2):179-84. doi: 10.1002/dc.21601. Epub 2011 Jan 6. PMID: 22246937
10. Singh R, Anshu, Sharma SM, Gangane N. Spectrum of male breast lesions diagnosed by fine needle aspiration cytology: a 5-year experience at a tertiary care rural hospital in central India. *Diagn Cytopathol.* 2012 Feb;40(2): 113-7. doi: 10.1002/dc.21507. Epub 2010 Nov 12. PMID: 22246926.
11. Tan PH, Ellis I, Allison K, Brogi E, Fox SB, Lakhani S, Lazar AJ, Morris EA, Sahin A, Salgado R, Sapino A, Sasano H, Schnitt S, Sotiriou C, van Diest P, White VA, Lokuhetty D, Cree IA; WHO Classification of Tumours Editorial Board. The 2019 World Health Organization classification of tumours of the breast. *Histopathology.* 2020 Aug;77(2):181-185. doi: 10.1111/his.14091. Epub 2020 Jul 29. PMID: 32056259.
12. Ukah CO, Oluwasola OA. The clinical effectiveness of fine needle aspiration biopsy in patients with palpable breast lesions seen at the University College Hospital, Ibadan, Nigeria: A 10-year retrospective study. *J Cytol.* 2011 Jul;28(3):111-3. doi: 10.4103/0970-9371.83467. PMID: 21897544; PMCID: PMC3159286.
13. Wauters CA, Kooistra BW, de Kievit-van der Heijden IM, Strobbe LJ. Is cytology useful in the diagnostic workup of male breast lesions? A retrospective study over a 16-year period and review of the recent literature. *Acta Cytol.* 2010 May-Jun;54(3):259-64. doi: 10.1159/000325032. PMID: 20518408.
14. Wells CA, Ellis IO, Zakhour HD, Wilson AR. Editorial Working Party, Cytology Subgroup of the National Coordinating Committee for Breast Cancer Screening Pathology. Guidelines for cytology procedures and reporting on fine needle aspirates of the breast. *Cytopathol.* 1994; 5(5): 316-334.
15. Yitta S, Singer CI, Toth HB, Mercado CL. Image presentation. Sonographic appearances of benign and malignant male breast disease with mammographic and pathologic correlation. *J Ultrasound Med.* 2010 Jun;29(6):931-47. doi: 10.7863/jum.2010.29.6.931. PMID: 20498468.