

Unusual Clinicopathological Presentations of Mature Cystic Teratoma: A case series

Rajashree Pradhan¹, Madhumita Paul², Arindam Bandopadhyay³, Sajeeb Mondal⁴

¹Associate Professor, Department of Pathology, College of Medicine & Sagore Dutta Hospital, ²Senior Resident (Demonstrator), Department of Pathology, College of Medicine & Sagore Dutta Hospital, ³Associate Professor, Department of Pediatrics, College of Medicine & Sagore Dutta Hospital, ⁴Associate Professor, Department of Pathology, Rampurhat Government Medical College & Hospital

How to cite this article: Rajashree Pradhan, Madhumita Paul, Arindam Bandopadhyay et. al. Unusual Clinicopathological Presentations of Mature Cystic Teratoma: A case series. Indian Journal of Public Health Research and Development/Volume 15 No. 1, January-March 2024.

Abstract

Mature cystic teratomas also known as dermoid cyst are one of the most common benign tumors of the ovary. It is usually seen in young women in the reproductive age group. It comprises of mature elements derived from all the three germ layers. In this case series we reported a series of 4 cases of mature cystic teratoma of the ovary with uncommon clinicopathological presentations. First case was a rare entity of melanocytic nevus arising from a mature cystic teratoma. Second case was adipocyte rich teratoma, an uncommon lipomatous lesion of the ovary. Third case was rupture of dermoid cyst presenting as acute abdomen. Fourth case was mature cystic teratoma in a post-menopausal woman. To conclude, though dermoid cysts after surgical removal have an uneventful clinical course, extensive sampling of the specimen for histopathological study should be done to identify rare pathologies which bears a clinical significance.

Keywords: Mature cystic teratoma, Melanocytic nevus, ovary, post-menopausal woman.

Introduction

Teratomas are tumors comprising of derivatives of all three germ layers. Mature teratomas are benign tumors and contains mature (well-differentiated tissues) such as sebaceous glands, hair, teeth, bone, cartilage etc. Mature cystic teratomas also known as as Dermoid Cyst is the most common type of ovarian germ cell tumor.⁴ 20-30% of all ovarian tumors are mature cystic teratomas.³ These are most commonly seen in younger women (<40yrs)¹⁰ and children.⁸ These are bilateral in 10-15% of cases with low incidence

of malignancy development (1-2%).¹² Here we are reporting a series of 5 cases of mature cystic teratomas of ovary with uncommon clinicopathological presentations.

Materials and Methods

The case series was reported from the department of Pathology of College of Medicine and Sagore Dutta Hospital over a period of 2 years. Clinical presentation, radiological findings and histopathological findings of the ovarian tumors were studied in all the 4 cases.

Corresponding Author: Sajeeb Mondal, Associate Professor, Department of Pathology, Rampurhat Government Medical College & Hospital.

Mobile: 8777561521

E-mail: sjbmondal@gmail.com

Case Discussion (Findings)

Case 1:

A 31-year-old female P₂ L₂ presented with lower abdominal pain and heaviness for past 6 months. On ultrasonography, it was found large multilocular cystic mass involving right adnexa. She underwent surgical removal of the adnexal mass and tissue sent for histopathological evaluation. On gross examination, it showed a large 7x 6.5x5 cm³ solid cystic mass of right ovary with adherent enlarged right fallopian tube. (Fig 1) Histopathological examination of the right ovarian mass revealed presence of mature elements derived from all the three germ layers (Fig 2&3) along with presence of dense aggregates of spindle to polygonal neval cells containing heavy deposits of melanin pigments at various places particularly in the skin. (Fig 4) The final diagnosis was given as melanocytic nevus arising from a mature cystic teratoma.

Case 2:

A 26-year-old nulliparous women presented with chronic pelvic pain. Ultrasonography revealed left ovarian mass with fat and calcification. She underwent oophorectomy (left side) and specimen sent for histopathological analysis. Gross finding was ovarian mass measuring 4cm in maximum diameter. Cut-section showed presence of thin-walled cyst, hair structure and fatty tissue. Histopathology showed presence of epidermis, hair shaft, endodermal glands, bone & cartilage (Fig 2&3) and extensive wide areas of adipocytes in clusters. (Fig 5) The final diagnosis was given as adipocyte rich mature cystic teratoma.

Case 3:

A 11-year-old school going girl presented with sudden onset of severe pain in the abdomen and admitted to the emergency OPD. Radiological investigation showed presence of a multiloculated ruptured cystic structure involving the left ovary. She underwent cyst removal and specimen sent for histopathological analysis. Microsection showed presence of well differentiated elements derived from all the three germ layers (Fig 2&3) and presence of multiple foreign body granuloma against the keratin and hair shaft of the ruptured dermoid cyst contents.

(Fig 6) The final diagnosis was given as ruptured mature cystic teratoma of ovary.

Case 4:

A 68-year-old postmenopausal female presented with slow onset lower abdominal pain noticed for past few months. No other clinical signs and symptoms were there. No past medical history and no relevant family history was there. On general examination, vitals were stable. On abdominal examination no palpable mass felt. Hematological investigations were normal. Ultrasonography showed large multilocular echogenic mass involving left adnexa. Uterus was of size 5.2x4 cm², with attached b/l adnexa. Left ovary consists of one large thin walled cyst containing hair & pultaceous material. (Fig 7) Her CA-125 was 28 U/mL (within normal limit). Considering the age the patient underwent hysterectomy with B/L salpingo-oophorectomy. Sections from endomyo, cervix, B/L tubes and right ovary showed no abnormality except for atrophic endometrium consistent with her age. Sections from left ovary showed histopathological features of mature cystic teratoma. (Fig 2&3)

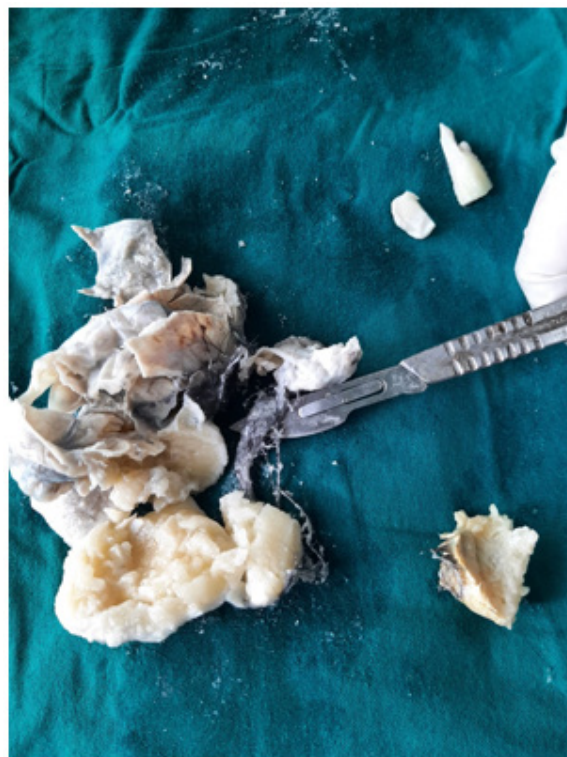

Fig 1- Showing gross pathology of mature cystic teratoma of ovary

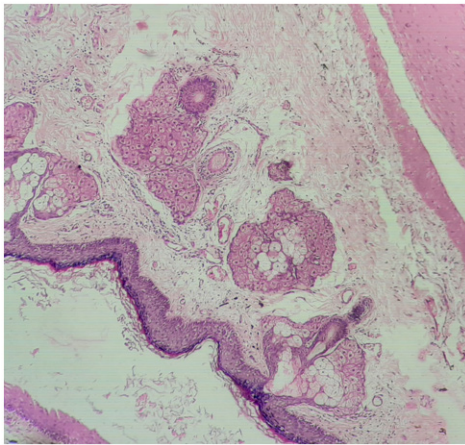


Fig 2 - showing ectodermal derivatives (skin epidermis & appendages) in teratoma(H&E,100X)

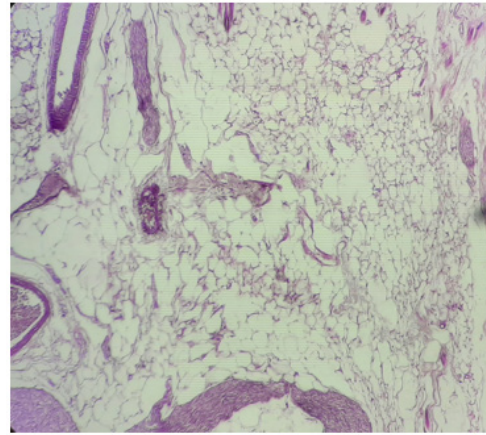


Fig 5- showing features of adipocyte rich teratoma (H&E,100X)

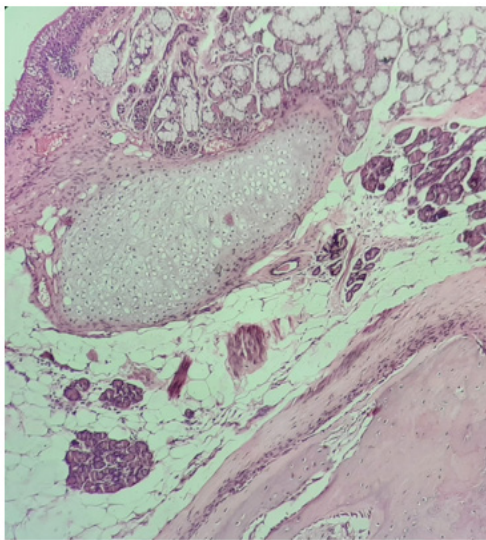


Fig 3- Showing mesodermal (bone, cartilage) & endodermal derivatives (glands) in teratoma (H&E,100X)

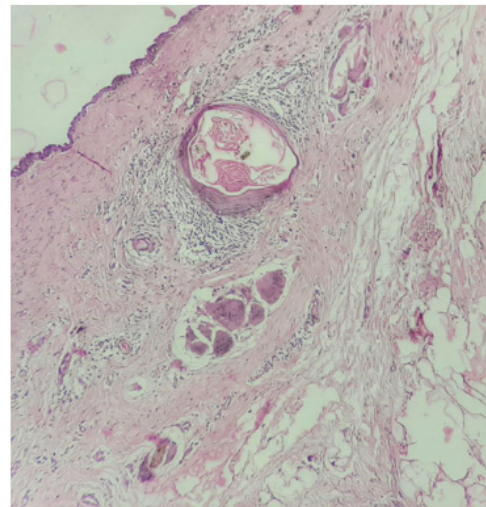


Fig 6- Showing presence of foreign body granulomatous reaction against keratin & hair shaft in case of rupture ovarian teratoma(H&E,100X)

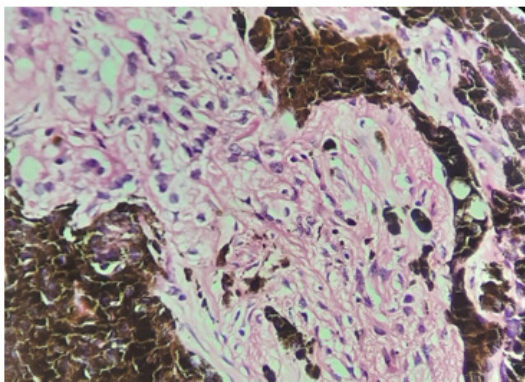


Fig 4- showing features of melanocytic nevus in teratoma(H&E,400X)

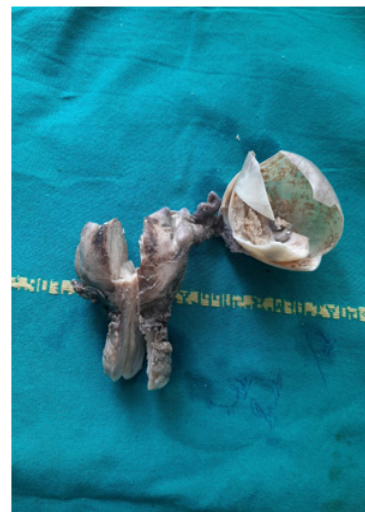

Fig 7- Showing gross features of presence of a large cyst of left ovary containing pultaceous material & hair attached to atrophic uterus

Discussion

Mature cystic teratomas (dermoid cyst) are the most common benign ovarian neoplasm constituting upto 10-25%.^{6,5} Histopathologically, they contain mature elements derived from all the three germ layers i.e. ectoderm, mesoderm and endoderm.¹¹

Our first case was melanocytic nevus arising from a dermoid cyst. Nevus arising in a dermoid cyst is a rare event. Very few cases had been reported in the literature. Chukwujama AE et al.¹ reported a case compound melanocytic nevus in dermoid cyst in a 36-year-old female. Kuroda et al⁹ postulated that melanocytes differentiate from the neural crest tissue originating in the teratoma and then migrate to the epidermis to form the nevus. Though the clinical outcome of these patients is uneventful after removal of the cyst, it is important to differentiate atypical melanocytic lesions such as dysplastic nevi and blue nevi from that of melanoma arising within teratoma for better management of the patients. In our case, there was uneventful clinical course.

Our second case was adipocyte rich dermoid cyst. One case adipocyte rich teratoma was reported by Suchita Pant et al¹³ in a 41-year-old female with B/L teratoma. The clinical course of the patient in our case was uneventful with no recurrence. Adipose tissue is not native to ovary and lipomatous ovarian lesions are rare. Lipomatous lesions originating from fat cells of teratoma contributes to one of the mechanisms for histogenesis of lipomatous lesion in ovary.²

Our third case was spontaneous rupture of teratoma with clinical presentation of acute abdomen. Spontaneous rupture of teratoma is rare.¹⁵ Ines Mazhoud et al.¹⁰ reported a case of ruptured mature cystic ovarian teratoma in a 21-year-old female.

Our fourth case was mature cystic teratoma in a post-menopausal woman. Dermoid cysts are more common in younger age groups and rarely seen in post-menopausal woman.¹⁴ Though the rate of malignant transformation in mature teratomas is low (1-2%)⁷ this rate increase in post-menopausal woman (15%).¹⁶ Though rare mature cystic teratomas can be seen in post-menopausal woman.

Conclusion

In this case series, we reported a series of cases of mature cystic teratomas with uncommon clinicopathological features. All these findings were diagnosed incidentally in histopathological evaluation. Therefore, extensive sampling in mature cystic teratomas is advised to diagnose the uncommon pathological entities and to avoid misdiagnosis.

Conflict of Interest- Nil

Source of Funding: No financial support received

Ethical Clearance: Our study was approved by institutional ethics committee

Patient Consent: Written informed consent was taken from all the patients participating in this study.

Author Contribution: All are having equal contribution

Acknowledgement: We like to acknowledge the Department of Gynecology for contribution of the specimens of this study.

References

1. A. E. Chukwujama, G. W. Bryson & J. C. R. Hardwick. Compound melanocytic naevus arising within the skin in benign mature cystic teratoma, *Journal of Obstetrics and Gynaecology*, 2006; 26(1): 82-83, DOI: 10.1080/01443610500419642
2. Akbulut M, Zekioglu O, Terek M, Ozdemir N. Lipoma of the ovary: A case report and review of the literature. *Ege Journal of Medicine*. 2007;46(2):105-06.
3. Ayhan A, Bukulmez O, Genc C, Karamursel BS, Ayhan A. Mature cystic teratomas of the ovary: case series from one institution over 34 years. *Eur J Obstet Gynecol Reprod Biol*. 2000 Feb;88(2):153-7. doi: 10.1016/s0301-2115(99)00141-4. PMID: 10690674.
4. Beker JS, Hacker NF, Hengst TC. *Practical gynecologic oncology*. Fourth ed. Philadelphia: Lippincott Williams and Wilkins; 2005. pp.443.
5. Chauhan R. S, Verma A. Kumar I, CT depiction of ovarian dermoid showing spontaneous fistulous communication with small bowel, *Egypt. J. Radiol. Nucl. Med*. 2018 Mar;49(1):292-294.
6. Fibus TF. Intraperitoneal rupture of a benign cystic ovarian teratoma: findings at CT and MR imaging. *AJR Am J Roentgenol*. 2000 Jan;174(1):261-2. doi: 10.2214/ajr.174.1.1740261. PMID: 10628494.

7. Inkollu S, Nelavelli A, Merugu SM. An unusual age presentation of mature cystic teratoma: a case report. *Int J Reprod Contracept Obstet Gynecol*. 2015 Aug;4(4):1234-1236.
8. Issack FH, Hassen SM, Mummmed FO, Gebreselassie KH, Hassen SK, Hassen IK. Pilimiction, a Rare Presentation of Ovarian Teratoma: A Case Report. *Res Rep Urol*. 2022 Mar 1; 14:57-61. doi: 10.2147/RRU.S356738. PMID: 35257005; PMCID: PMC8898156.
9. Kuroda N, Hirano K, Inui Y, Yamasaki Y, Toi M, Nakayama H, Hiroi M, Enzan H. Compound melanocytic nevus arising in a mature cystic teratoma of the ovary. *Pathol Int*. 2001 Nov;51(11):902-4. doi: 10.1046/j.1440-1827.2001.01288.x. PMID: 11844060.
10. Mazhoud I, Skhiri W, Hafsa C, Toumi D, Maatouk M, Ben Salem A. Ruptured mature ovarian teratoma: A case report. *Int J Surg Case Rep*. 2023 Jan; 102:107788. doi: 10.1016/j.ijscr.2022.107788. Epub 2022 Nov 24. PMID: 36516595; PMCID: PMC9768295.
11. Outwater EK, Siegelman ES, Hunt JL. Ovarian teratomas: tumor types and imaging characteristics. *Radiographics*. 2001 Mar-Apr;21(2):475-90. doi: 10.1148/radiographics.21.2.g01mr09475. PMID: 11259710.
12. Ozgur T, Atik E, Silfeler DB, Toprak S. Mature cystic teratomas in our series with review of the literature and retrospective analysis. *Arch Gynecol Obstet*. 2012 Apr;285(4):1099-101. doi: 10.1007/s00404-011-2171-8. Epub 2011 Dec 14. PMID: 22167448.
13. Pant S et al., Uncommon Pathological Presentations of Mature Cystic Teratoma. *Journal of Clinical and Diagnostic Research*. 2022 Jun;16(6): ER01-ER04.
14. Ulbright TM. Germ cell tumors of the gonads: a selective review emphasizing problems in differential diagnosis, newly appreciated, and controversial issues. *Mod Pathol*. 2005 Feb;18 Suppl 2: S61-79. doi: 10.1038/modpathol.3800310. PMID: 15761467.
15. Waxman M, Boyce JG. Intraperitoneal rupture of benign cystic ovarian teratoma. *Obstet Gynecol*. 1976 Jul;48(1 Suppl):9S-13S. PMID: 781571.
16. Wei F, Jiang Z, Yan C. Analysis of 20 mature ovarian cystic teratoma cases in postmenopausal women. *Chin Med J (Engl)*. 2001 Feb;114(2):137-8. PMID: 11780192.