

# Effectiveness of ligation of Inter Sphincteric Fistula Tract (LIFT) in the Management of Fistulas in ano in Maharashtra Population: Retrospective Study

Sampat Tukaram Waghmare

Assistant Professor, Department of General Surgery, School of Medical Sciences, S. S. U. T and M. C Sehere, Madhya Pradesh.

**How to cite this article:** Sampat Tukaram Waghmare. Effectiveness of ligation of Inter Sphincteric Fistula Tract (LIFT) in the Management of Fistulas in ano in Maharashtra Population: Retrospective Study. Indian Journal of Public Health Research and Development/Volume 15 No. 1, January-March 2024.

## Abstract

**Background:** Anal fistula is one of the most common ano- rectal problems, resulting in very negative patient experiences. The objectives of anal fistula treatments are to achieve healing with a low recurrence rate and preserve anal function.

**Method:** 55 adult patients were confirmed to be competent for surgery. USG examination with 7 to 10 MHZ transducer passed into the anal canal, which is carried out with the patient in the left lateral position. Serial radial images were taken to study the location and position of the fistula. The LIFT procedure was similar to Rojanaskul proposed method. The duration of surgery and healing time were also noted.

**Results:** 48 (87.2%) were as per Parks classification, 5 (9.09%) intersphincteric, 2 (3.63%) suprasphincteric, Classification based on course of fistula - 20 (36.3%) anterior straight, 28 (50.9%) posterior straight, 5 (9.09%) curved, and 2 (3.63%) semi-horse shoe. Classification based on the tract - 50 (90.9%) single tracts, 5 (9.09%) multiple tracts.

**Conclusion:** LIFT technique is simple and safe, with a high rate of healing and no risk of incontinence.

**Keywords:** MHz trasducer, Park's classification, Rojanaskal, Sitzbath Sitz bath, Vicry / suture

## Introduction

Peri-anal fistula is defined as abnormal communication between the anorectal mucosa and the perianal skin <sup>(1)</sup>. It usually results from an anorectal abscess that bursts spontaneously or after inadequate abscess drainage. It causes recurrent pain and purulent discharge, with or without abscess formation. Fistula in ano is a benign, treatable lesion of the rectum and anal canal. Cryptoglandular infection accounts for about

90% of the cases. The majority of the infections are acute, and a minority are chronic low grade infections, pointing to varying aetiogenesis. The pathogenesis has been attributed to the bursting open of an acute or inadequately treated anorectal fistula developed in an anal gland lying within the sub-mucosa of the anal canal, which is the direct cause of most of the fistula in ano<sup>(2)</sup>. It can be associated with a number of conditions, including tuberculosis, crohn's disease, and malignancies.

---

**Corresponding Author:** Sampat Tukaram Waghmare, Assistant Professor, Department of General Surgery, School of Medical Sciences, S. S. U. T and M. C Sehere, Madhya Pradesh.

**E-mail:** sampatwaghmare@yahoo.com

---

Fistula in ano is characterised on the basis of its location in relation to the anal sphincter muscles according to Park's classification; intersphincteric, transsphincteric, suprasphincteric, or extrasphincteric. A fistula can be simple or complex. Sub-mucosal, low inter-sphincteric, and low trans-sphincteric fistulas are considered as simple. Fistula in ano is considered complex if found to have any of the following characteristics:<sup>(3)</sup> tract crosses more than 30-50% external sphincter, anterior fistula in ano in a female, presence of multiple tracts; recurrent fistula; pre-existing incontinence, local irradiation; and Crohn's disease.

There are number sphincter sparing methods such as Fibrin or cyanoacrylate, glue injection anal fistula plug, endorectal muscular or mucosal advancement flap, care-out fistulectomy, ligation of inter-sphincteric Fistula tract (LIFT). As LIFT procedure is simple, safe, minimally invasive technique<sup>(4)</sup>. It was also effective with high and rapid healing rate without any resultant incontinence. Hence attempt was made to evaluate the LIFT in different age group patients.

### Material and Method

55 adult patients regular visiting to surgery department Prakash Institute of Medical Sciences and research Islampur (dist) Sangli, Maharashtra-415409 were studied.

**Inclusive criteria:** Patients above the age of 20 with recently diagnosed complex perianal fistulas of infectious aetiology who gave written consent were selected for study.

**Exclusion criteria:** Patients with superficial fistula, recurrent fistula, recurrent fistula secondary to tumour in inflammatory bowel disease, TB or trauma, pre-existing incontinence, or extra-sphincteric fistula immune compromised patients were excluded from the study.

**Method:** A detailed history was collected from every patient's demographics, type of fistula, extent of sphincter involvement, location of external and internal openings, presence of multiple tracts, and tract collection (perianal or submucosal collection). Every patient had an anal ultrasound examination. It involves the passage of 7 to 10 MHz transducer into the anal canal, which is carried out with the patient in the left lateral position.

**Operative techniques:** patients were prepared with an evacuation enema 6-8 hours before the time of the operation. All operations were performed under regional anaesthesia. Broad spectrum antibiotics and metronidazole were given before the operation. The positions of the patient were lithotomy, where the external opening of the fistula lies anteriorly, and prone Jack-knife with the buttocks strapped apart, where the external opening of the fistula lies posteriorly. A detail of the LIFT procedure is similar to that proposed by Rojanasakul et al. (2007). The first internal opening was identified by palpation or by injection of saline through the external opening. A curvilinear incision was made in the intersphincteric groove over the site of the internal opening. The intersphincteric plane was dissected by scissor and diathermy meticulously until the fibrous fistulous tract was identified. Once the tract was identified, the tract was then transfixed with 2/0 Vicryl close to the internal sphincter. Saline was injected through the external opening to confirm that the tract was no longer patent, and it was then divided distally to the point of ligation. After traction, a segment of the distal tract was excised. From the external opening, the tract was opened, curetted and washed with a 10% povidone iodine solution. Finally, the intersphincteric incision wound was repaired with interrupted 2/0 vicryl sutures.

**Post-operative Management and follow up -** post-operatively antibiotics were given for gram negative organism and anaerobes for 5 to 7 days. Analgesics were given according to patients need. Patients were discharged with antibiotics, analgesics, stool softener and advice to take sitz bath. Patients were asked to come after 1 week of operation for stitch removal of intersphincteric wound. The subsequent follow up consultation was weekly after the first visit till complete wound healing. At each visit patients were interviewed for pain, discharge, and wound healing and clinical continence status. On examination intersphincteric incision wound, site of previous external and internal opening of fistula and sphincter tone were assessed. After healing, the patients were asked to visit if any recurrent pain, swelling or discharge occurs.

Clinical healing was defined as healing of intersphincteric and external opening wound, absence of fistula drainage and no evidence of abscess formation at any time during follow up. Recurrence was defined as non-healing wound 6 weeks after

surgery or reappearance of an external opening, persistent discharge or reappearance of fistula after the initial wound had healed.

The duration of study was December-2015 to November-2019.

**Statistical analysis:** Fistulae of different types were classified with percentage. The duration of surgery and healing was compared with z test. The statistical analysis was carried out in SPSS software. The ratio of male and female was 3:1.

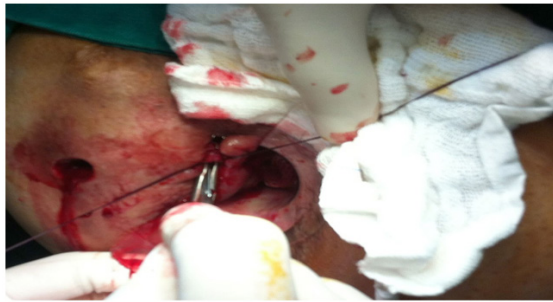

Figure 1: Repairing the fistula tract: the right one next to the edge of the internal sphincter and the left is by the external sphincter

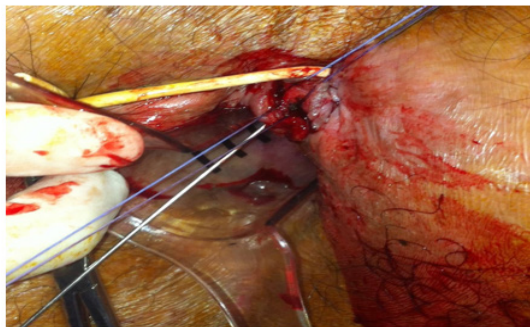


Figure 2: The second step of the technique, with correct identification of the fistula tract

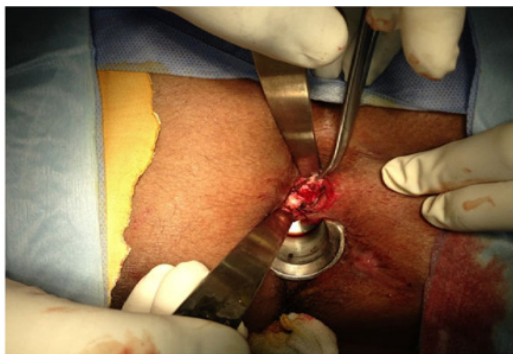

Figure 3 (a): The tract was transfixed close to the internal sphincter with 2/0 Vicryl and divided distal to the point of ligation

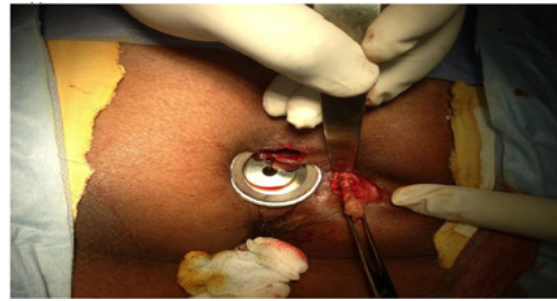

Figure 3 (b): Partial core-out fistulectomy performed from the external opening to the outer border of the external sphincter

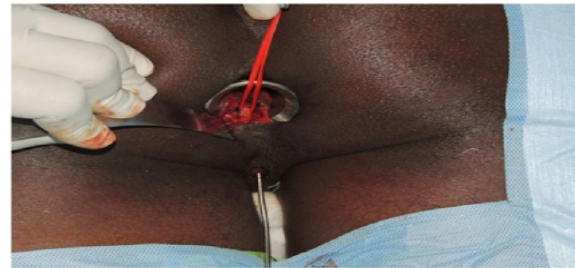


Figure 3 (c): The intersphincteric tract, identified by meticulous dissection and hooked using a vascular loop, was confirmed by passing a probe

**Observation and Results**

Table-1: Study of the classification and characteristics of fistulas

Classifications of Fistulae	Number	Percentage %
(a) Park’s classification		
Trans-sphincteric	48	87.2
Intersphincteric	5	9.09
Supra sphincteric	2	3.13
(b) Classification based on the course of fistulae		
Anterior Straight	20	36.3
Posterior Straight	28	50.9
Curved	5	9.99
Semi horse-shoe	2	3.63
(c) Classification based on the tract		
single tract	50	9.09
Multiple tract	5	9.09

48 (87.2%) park S classification, trans-spineter, 5 (9.99%) intersphincteric, and 2 (3.63%) intra-sphincteric

Classification based on the course of the fistula 20 (36.3%) anterior straight, 28 (50.9%) posterior straight, 5 (9.09%) curved, and 2 (3.63%) semi-horseshoe.

Classification based on the tract: single tract 50 (90.9%), 5 (9.09%) multiple tracts.

**Table-2:** Duration of surgery and wound healing - 35.4 ( $\pm 4.36$ ) operating time; 23.22 ( $\pm 5.13$ ) intersphincteric wound healing, 25.86 ( $\pm 7.82$ ) external opening wound healing.

**Table 2: Duration of surgery and wound healing**

Various	Mean value (SD $\pm$ )
(a) Operating time	35.4 ( $\pm 4.36$ )
(b) Intersphincteric wound healing	23.22 ( $\pm 5.13$ )
(c) External opening wound healing	25.86 ( $\pm 7.82$ )

### Discussion

The current study looks at the effectiveness of ligation of the inter-sphincteric fistula tract (LIFT) in the treatment of ano fistula in the Maharashtra population. 48 (87.2%) were as per Parks classification: 5 (9.09%) inter-sphincteric, 2 (3.63%), supra-sphincteric classification based on the course of fistulae: 20 (36.3%) anterior straight, 28 (50.9%), 5 (9.09%) curved, 2 (3.63%) semi-horseshoe, classification based on tract - 50 (90.9%) single tract, 5 (9.09%) multiple tract (Table-1). The operating time mean value was 35.4 ( $\pm 4.36$ ), 23.22 ( $\pm 5.13$ ) was intersphincteric wound healing time, and 25.86 ( $\pm 7.82$ ) was external wound healing time (Table-2), (Figure-1, 2 and 3) These findings are more or less in agreement with previous studies <sup>(6)(7)(8)</sup>.

There is a growing interest in the ligation of LIFT because the procedure is minimally invasive, easy to learn and perform, and can be used on recurrent cases. The early results of the LIFT procedure were quite impressive, with success rates ranging from 57% to 97% with minimal morbidity and little or no impact on continence status. Some surgeons have used modifications of LIFT by combining it with additional procedures

such as the trans-anal advancement flap or bioprosthesis prosthetic plug<sup>(9)</sup>. The healing rate improved to 95% in the LIFT with the anal fistula plug procedure but did not improve with the combination of the advancement flap.

Another advantage of the LIFT procedure is that it can be performed in cases of recurrence even when failure occurred with previous use of LIFT technique<sup>(10)</sup>. Recurrence of an anal fistula is mainly due to infection and technical errors. Infection was one of the reasons for the non-healing of internal opening wounds because it is caused by the breakdown of the closure wound on the internal sphincter. So in cases with persistent anal abscesses or infected incisional wounds, infection could be a factor for treatment failure.

### Summary and Conclusion

Ligation of the intersphincteric fistula tract (LIFT) has a high success rate in primary or recurrent complex fistulae-in-ano. Recurrence is related to diabetes mellitus, perianal collections, abscesses along the tract, and multiple tracts. It can be successfully managed by repeated LIFT.

**Limitation of study** - Due to the tertiary location of the research centre, the small number of patients, and the lack of the latest techniques, we have limited findings and results.

This research work is approved by the Ethical Committee of the Department of Prakash Institute of Medical Sciences and researches Islampur (dist.) Sangli, Maharashtra 415409.

**Conflict of Interest:** No

**Funding:** Self

### References

1. Matos D, Lunniss PJ - Total sphincter conservation in high fistula in ano; results of a new approach. Br. J. Surg. 1993, 80; 802-804.
2. Stripping Sirlkurnpiboon -ligation of the intersphincteric fistula tract and its modification: Results from the treatment of complex fistulas in world gastroenterology in test surgery 2013, 5 (4); 123-128.
3. Bluemeti J, Abcarian A - Evaluation of treatment of fistula in ano, World J. Surg. 2012, 35(3); 177-80.

4. Ramanujam PS, Prasad ML - Perianal abscess and fistulas. A study of 1023 patients Dis. colon rectum 1984, 27; 593-7.
5. Rojanasakul A, Pattanaarum J - Total anal sphincter saving technique for fistula in ano: the ligation of the intersphincteric fistula tract J. Med. Assoc. Thai. 2007; 90(30); 581-86.
6. Parks AG, Stitz RW - The treatment of high fistula in ano. Dis. Colon Rectum. 1976, 19; 487-99.
7. Bleier JL, Moloo H Ligation of the intersphincteric fistula tract; an effective new technique for complex fistulas Dis. Colon. Rectum. 2010, 53; 43-46.
8. Parks AG - Pathogenesis and treatment of fistula in ano Med. J. 1961, 1; 463-9.
9. Rojanasakul A - LIFT Procedure: A Simplified Technique for Fistula in Ano, Tech Col Proctol 2009, 13 (3); 237-40.
10. Han JG, Y; BQ - ligation of the intersphincteric fistula tract plus a bioprosthesis anal fistula plug. Colorectal Dis. 2012, 12; 32-38.
11. Tan KK, Tan IJ - The anatomy of failures following the ligation of the intersphincteric tract technique for anal fistula Dis. Colon. Rectum (2011), 54; 1368-1372.